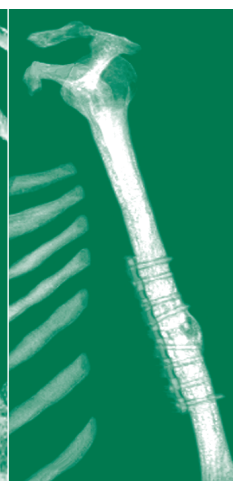
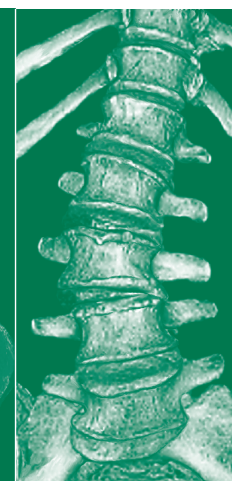


CRC Course  
13 June 2025  
Lyon, France

<https://congress.efort.org/crc>



# EFORT SYLLABUS

## The Comprehensive Orthopaedic Review Course


One full-day course during the 26<sup>th</sup> EFORT Congress: Friday 13 June 2025

### Course highlights

- Eye Opener
- Basic Science
- Paediatrics
- Reconstruction
- Sport Injuries
- Musculoskeletal Infections & Tumors
- Spine (incl. Trauma)
- Trauma Lower Limb
- Trauma Upper Limb



# Welcome



Dear CRC participants!

Welcome to the 17th edition of the EFORT Comprehensive Review Course (CRC) presented on Friday, 13th June 2025 all day.

This course, running during the 26th EFORT Congress Lyon 2025, is a review of the essentials of our specialty with emphasis on fundamental knowledge of basic sciences, orthopaedic surgery and traumatology. Indeed, the content is presented in a concise and brief way, gathering knowledge of the orthopaedics and traumatology based on best evidence.

The CRC presentations summarize the elements which are presented within the syllabus in a brief and easy way to understand.

The educational programme starts with the "Eye Opener", with a focus on Orthopaedics & Traumatology Research. Discussion around "Modern Technologies in Orthopaedics. Challenging Ethics and Outcomes" will be led by Professor Theofilos Karachalios from the University of Thessaly, in Larissa, Greece.

An extensive chapter on the fundamental knowledge within basic sciences will follow the CRC programme format. The rest of orthopaedics reviewed by each subspecialty with the most important information from the fields of paediatrics and reconstructive surgery of bones and joints will wrap up the module after a short focus on sports medicine. Basic knowledge on musculoskeletal tumours and infections will follow and a deep summary of spine conditions – both in orthopaedics and traumatology – will bridge the content towards the key aspects of trauma in lower and upper limb to close the programme. General conditions, treatments and possible complications are presented and explained in the syllabus 2025; a reference publication where each chapter includes three to five questions under the MCQ exam format. These questions, directly linked to the main highlights of the corresponding topic and clearly addressing established core knowledge, aim to actively involve the audience and to give specific examples of a standard interim assessment.

We hope this material will be useful to those willing to review the fundamentals of current orthopaedic surgery and traumatology, particularly to prepare to certification exams.

We would like acknowledge the collaboration of all the experts conducting the course whose participation and efforts in the preparation of this syllabus make the final result worth it.

We also wish to thank all the oral presenters of the CRC, as well as the chairs moderating the different topic sections of the course and the EFORT Head Office staff.


We are sure that this particular EFORT Comprehensive Review Course (CRC) during the 26th EFORT Congress Lyon 2025 will be a successful programme enhancing your experience.

A handwritten signature in blue ink, likely belonging to Prof. Stefan Nehrer.

Prof. Stefan Nehrer  
Chairman of the EFORT  
Education Committee

A handwritten signature in blue ink, likely belonging to Prof. Dr. Luigi Zagra.

Prof. Dr. Luigi Zagra  
Chairman of the EFORT  
Science Committee



## Eye Opener

Modern Technologies in Orthopaedics. Challenging Ethics and Outcomes .....	05
--	----

## Musculoskeletal Infections & Tumours

Infection After Total Joint Arthroplasty .....	06
Diagnostic & Recognition Of Primary Bone Tumours.....	11
Diagnostic Algorithm & Treatment Options In Bone Metastasis .....	17

## Spine (Including Trauma)

Paediatric Idiopathic Deformities.....	21
Degenerative Spine Diseases .....	27
Spine Fractures .....	27

## Trauma Lower Limb

Fractures: Pelvic Ring & Acetabular Fractures.....	37
Fractures: Femur, Tibia & Open Fractures.....	44
Fractures: Pilon, Ankle, Talus & Calcaneus.....	50

## Trauma Upper Limb

Fractures: Shoulder, Arm, Elbow & Forearm.....	59
Fractures: Hand & Wrist .....	74

## Basic Science

Biomechanics And Biomaterials For Musculoskeletal Application.....	78
Study Design And Statistics.....	85

## Paediatrics

Classification & Principles Of Childhood Fracture Treatment.....	91
Foot Disorders Of Newborns.....	96
Hip Diseases In The Childhood .....	102

## Reconstruction

Knee: Surgical Treatment For Degenerative Changes.....	108
Ankle Osteoarthritis, Adult Acquired Flatfoot Deformity and Hallux Valgus.....	116
Hip Reconstruction.....	128
Degenerative Disorders Of The Cuff, Shoulder And Elbow .....	134

## Sport Injuries

Knee Ligament And Menisci .....	142
---------------------------------	-----





Th. Karachalios, MD, DSc, PhD EFORT President 2024-2025

Professor and Chairman in Orthopaedics, Faculty of Medicine, University of Thessaly, Greece

### **The eye opener: Modern Technologies in Orthopaedics. Challenging Ethics and Outcomes**

We live in a rapidly evolving orthopaedic world, where technological advancements are significantly transforming both education and clinical practice. The pace of technological improvement is accelerating, presenting the challenge of ensuring that we have the means to keep pace with this evolution.

Despite improvements in orthopaedic surgery, it seems that we are still liable to create new patterns of failure and disaster. Clear examples of this lie in the recent overuse of minimally invasive surgical techniques, the problems which occur with metal on metal bearings of all types, and, more alarmingly, with the modular interfaces of the big femoral heads and modular necks. It has also become apparent that theoretical and laboratory studies do not always hold up in the cold morning light of long term clinical studies and that there are few quality Levels I and II clinical outcome studies. Added to these problems, there is the matter of finance. Health providers question the cost-effectiveness of fracture and arthroplasty procedures and especially the need for the introduction of the newer, more expensive, techniques and implants.

One corresponding notable trend is the shift in patient behaviour and expectations. Modern patients are increasingly well-informed, often turning to online resources and simply googling information about their conditions and potential treatments. This can lead to fast-tracked decisions that are not necessarily tailored to the individual patient's needs. This raises the question: how do we define the role of the orthopaedic specialist in this context?

Investments made by the implant and pharmaceutical industry are also increasingly geared towards the individual user experience, and educational dissemination is being explored through new methods. How do we interpret the truthfulness, reliability, and impartiality of such a flow of information?

In order to investigate arguments and controversies we will examine the example of total knee arthroplasty (TKA) performed with the use of modern robotic technologies.

Total knee arthroplasty (TKA) is a well established reconstructive procedure for end-stage knee joint disorders for which satisfactory survival rates have been reported at 15 years follow up. However, it has recently been reported that functional outcomes are inferior when compared to total hip arthroplasty and a high incidence (up to 20%) of patients with objectively sound joints report dissatisfaction with the procedure. Clinical databases and worldwide national registries suggest that modern TKAs often fail and must be subsequently revised due to aseptic loosening, infection, instability and/or stiffness.

Conventional surgical techniques have recently been challenged due to patient dissatisfaction rates, and specialist surgeons have attempted modifications and improvements of techniques,

often using experimental and/or expensive modern technology. Surprisingly, improvements are often introduced separately (alignment, laxities and contemporary implant designs) and there is a lack of a unified system for improved TKA technique in every day practice, which would take into consideration individual knee and patient characteristics.

Different types of robotic systems have been used in an attempt to improve outcomes and patient satisfaction.<sup>1,2</sup> Prospective randomized studies have already confirmed improvements in accuracy (at the level of one mm/one degree) of both femoral and tibial osteotomies resulting in more precise implant positioning. Improved early (3 months) functional recovery has been shown in a small number of RCT's.<sup>3-8</sup> In contrast, most RCT's found no significant differences in functional outcomes, opioid use, or complication rates. Longer operative times were recorded with robotic TKA.<sup>3-8</sup> However, this type of accuracy in implant positioning has not yet translated into improved long-term clinical survival rates.<sup>3-8</sup> When robotic assisted outcomes were compared to navigation assisted TKA outcomes they were also comparable.<sup>9</sup>

The issue of cost of modern robotic technology has not been adequately addressed in either media publications or RCTs. Although it is recognised that there are methodological problems in the model based economic evaluation of robotic TKA, some studies have found that it is cost effective in high volume hospitals while others show only marginal gains in quality adjusted life years.<sup>10,11</sup>

The media is for many people their most important source of health information, and a possible majority take specific actions following exposure to such information. It is important that media coverage and public messaging about robotic TKA reflect the best available clinical evidence.<sup>8,12</sup> Media portrayals of robotic TKA were often overly optimistic and in some cases inaccurate compared to the available Level I evidence on this topic. The volume of news articles about robotic TKA far outpaced the availability of high quality evidence and were usually overly optimistic.<sup>8,10</sup> A large number of media publications and scientific studies refer to a robot by brand name and/or manufacturer, which is often combined with an overwhelmingly positive tone, which thus raises concerns related to potential biases.<sup>13</sup> Medico-legal issues and complications related to robotic TKA have mainly not been addressed.<sup>14</sup>

Patient satisfaction remains one of the most challenging problems in TKA and patient expectations play a critical role in post-operative satisfaction. It is thus important that media depictions do not paint an unrealistic picture of robotic TKA.<sup>15</sup>

In order to improve patient satisfaction, a more personalised approach to TKA has been introduced<sup>16,17</sup>, especially for those patients who are younger and more active.<sup>16,17</sup> Various patients' osteoarthritic knee phenotypes have been described, possibly

requiring the introduction of kinematic, personalised or functional alignment techniques.<sup>18,19</sup> It is possible that personalised alignment techniques in TKA could be more accurately executed by a robotic unit. While it has been shown that outcomes of mechanically aligned robotic TKA are no better than those of conventional methods,<sup>20</sup> the exact effect on TKA outcomes of different alignment techniques has not yet been clearly shown.<sup>21</sup>

We have suggested in the past that all known parameters influencing the long term outcome of TKA should be incorporated into a model platform of a robotic unit (Fig. 1).<sup>16</sup> It is possible that other factors than osteotomies and alignment (such as individual laxities and implants which incorporate advanced contemporary surface kinematics) may play an important role in improving artificial joint kinematics and functional outcomes and thus improve satisfaction in selected young and functionally demanding patients.<sup>16,22</sup>

In our opinion, technology will continue to progress, but its introduction into clinical practice should be done with care, based on sound research and clinical evidence.<sup>23</sup> Given the rise of misinformation about health and treatments on the internet in general and in the media in particular, it is the ethical duty of researchers and clinicians to contribute meaningful and accurate information to the online conversation.

The long term outcome of TKA depends on several factors (Fig. 1).

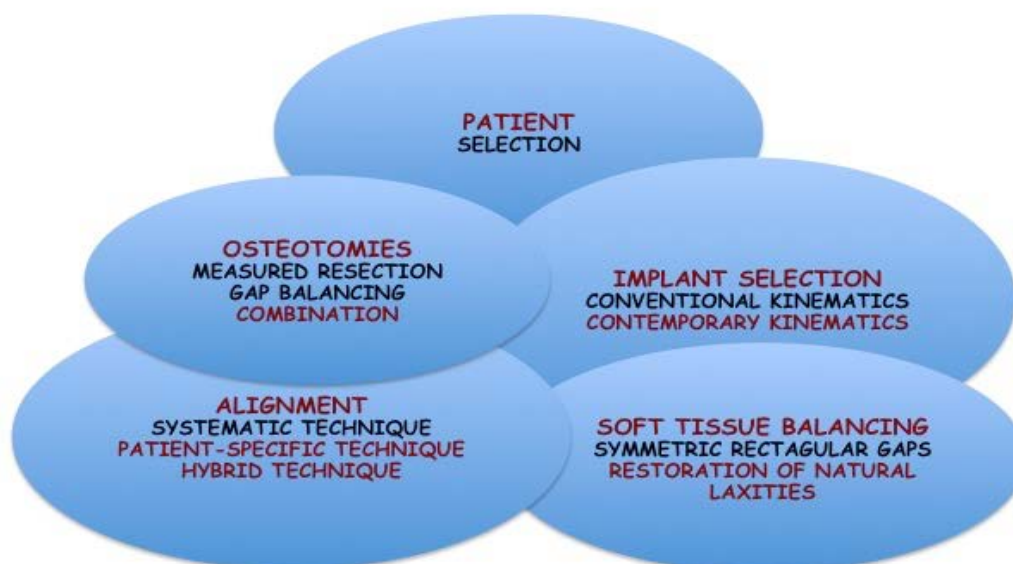


Fig. 1

## References

- Fan X, Wang Y, Zhang S, Xing Y, Li J, Ma X, Ma J. Orthopedic surgical robotic systems in knee arthroplasty: a comprehensive review. *Front Bioeng Biotechnol.* 2025; 20:13:1523631.
- Zhang H, Jiang XA, Jin BC, Zhang HH, Liang JB. Current developments in robotic assistance technology for total knee arthroplasty: a comprehensive overview. *J Orthop Surg Res.* 2025; 20(1):80.
- Yue HY, Ding GQ, Li HX, Zeng J, Jiang XD, Zhu ZD, Jiang H. Does Robotic-Assisted Total Knee Arthroplasty Improve Outcomes

of Adult Osteoarthritis Patients-A Systematic Review and Trial Sequential Meta-Analysis. *Orthop Surg.* 2025; doi: 10.1111/os.70007.

- Fu X, She Y, Jin G, Liu C, Liu Z, Li W, Jin R. Comparison of robotic-assisted total knee arthroplasty: an updated systematic review and meta-analysis. *J Robot Surg.* 2024; 25;18(1):292.
- Daoub A, Qayum K, Patel R, Selim A, Banerjee R. Robotic assisted versus conventional total knee arthroplasty: a systematic review and meta-analysis of randomised controlled trials. *J Robot Surg.* 2024; 18(1):364.
- Alrajeb R, Zarti M, Shuia Z, Alzobi O, Ahmed G, Elmhiregh A. Robotic-assisted versus conventional total knee arthroplasty: a systematic review and meta-analysis of randomized controlled trials. *Eur J Orthop Surg Traumatol.* 2024; 34(3):1333-1343.
- Zabat MA, Giakas AM, Hohmann AL, Lonner JH. Interpreting the Current Literature on Outcomes of Robotic-Assisted Versus Conventional Total Knee Arthroplasty Using Fragility Analysis: A Systematic Review and Cross-Sectional Study of Randomized Controlled Trials. *J Arthroplasty.* 2024; 39(7):1882-188.
- Ekhtiari S, Sun B, Sidhu R, Ade-Conde AM, Chaudhry H, Tomescu S, Ravi B, Mundi R. Evidence Versus Frenzy in Robotic Total Knee Arthroplasty: A Systematic Review Comparing News Media Claims to Randomized Controlled Trial Evidence. *J Bone Joint Surg Am.* 2024; 106(24):2384-2392.

- Melinte MA, Simionescu L, T b car M, Bl naru V, Melinte RM. Comparison between robotic-assisted and navigation-assisted total knee arthroplasty shows comparable outcomes: A systematic review and meta-analysis. *J Orthop.* 2025; 68:96-104.
- Sarrel K, Hameed D, Dubin J, Mont MA, Jacofsky DJ, Coppolecchia AB. Understanding economic analysis and cost-effectiveness of CT scan-guided, 3-dimensional, robotic-arm assisted lower extremity arthroplasty: a systematic review. *J Comp Eff Res.* 2024; 13(4):e230040.
- Hoeffel D, Goldstein L, Intwala D, Kaindle L, Dineen A, Patel L, Mayle R. Systematic review and meta-analysis of economic and healthcare resource utilization outcomes for robotic versus manual

total knee arthroplasty. *J Robot Surg.* 2023 Dec;17(6):2899–2910.

- Batailler C, Parratte S. Assistive technologies in knee arthroplasty: fashion or evolution? Rate of publications and national registries prove the Scott Parabola wrong. *Arch Orthop Trauma Surg.* 2021; 141(12):2027–2034.

- Barakat N, Ramamurti P, Duensing IM, Browne JA. Financial Conflicts of Interest and Industry Funding are Associated With Conclusions Favorable to New Technologies: A Review of Published Economic Analyses in Hip and Knee Arthroplasty. *J Arthroplasty.* 2024; 39(9S1):S299–S305.

- De Paola L, Treglia M, Napoletano G, Treves B, Ghamlouch A, Rinaldi R. Legal and Forensic Implications in Robotic Surgery. *Clin Ter.* 2025 Mar-Apr;176(2):233–240.

- Hoveidaei AH, Esmaili S, Ghaseminejad-Raeini A, Pirahesh K, Fallahi MS, Sandiford NA, Citak M. Robotic assisted Total Knee Arthroplasty (TKA) is not associated with increased patient satisfaction: a systematic review and meta-analysis. *Int Orthop.* 2024; 48(7):1771–1784.

- Karachalios T, Komnos GA. Individualized surgery in primary total knee arthroplasty. *EFORT Open Rev.* 2020; 5(10):663–671.

- Vendittoli PA, Riviere C, Hirschmann MT, Bini S. Why personalized surgery is the future of hip and knee arthroplasty: a statement from the Personalized Arthroplasty Society. *EFORT Open Rev.* 2023; 8(12):874–882.

- Aflatooni JO, Wininger AE, Park KJ, Incavo SJ. Alignment options and robotics in total knee arthroplasty. *Front Surg.* 2023; 10:1106608.

- Migliorini F, Pilone M, Schäfer L, Simeone F, Bell A, Maffulli N. Functional alignment in robotic-assisted total knee arthroplasty: a systematic review. *Arch Orthop Trauma Surg.* 2024; 144(4):1741–1749.

- Bensa A, Sangiorgio A, Deabate L, Illuminati A, Pompa B, Filardo G. Robotic-assisted mechanically aligned total knee arthroplasty does not lead to better clinical and radiological outcomes when compared to conventional TKA: a systematic review and meta-analysis of randomized controlled trials. *Knee Surg Sports Traumatol Arthrosc.* 2023; 31(11):4680–4691.

- Morcos MW, Uhuebor D, Vendittoli PA. Overview of the different personalized total knee arthroplasty with robotic assistance, how choosing? *Front Surg.* 2023; 10:1120908.

- García-Sanz F, Sosa-Reina MD, Jaén-Crespo G, González-de-la-Flor Á, Villafañe JH, Romero-Morales C. Redefining Knee Arthroplasty: Does Robotic Assistance Improve Outcomes Beyond Alignment? An Evidence-Based Umbrella. *J Clin Med.* 2025; 9:14(8):2588.

- Inabathula A, Semerdzhiev DI, Srinivasan A, Amirouche F, Puri L, Paponov H. Robots on the Stage: A Snapshot of the American Robotic Total Knee Arthroplasty Market. *JB JS Open Access.* 2024; 9(3):e24.00063.



Dr. Domizio Suva

Bone Infection Unit, Geneva University Hospitals  
Geneva, Switzerland

Domizio.Suva@hcuge.ch

## Infection After Total Joint Arthroplasty

### 1. Abstract

Total hip and knee arthroplasties are associated with a risk of infection ranging between 0.5 and 2%. Despite a low risk, periprosthetic joint infection (PJI) is a dramatic complication, often requiring multiple surgeries and a prolonged antibiotic treatment. In addition, PJI is associated with an increased morbidity and mortality for the patients. The treatment must be multidisciplinary and adapted to the clinical situation of the patients. The objective of this manuscript is to review the consensus on the diagnosis and treatment of PJI.

### 2. Introduction

Periprosthetic joint infection occurs in about 0.5 to 2 % of primary and 10% of revision arthroplasties<sup>1</sup>. PJI is the second cause of revision after primary joint replacement, and the primary cause of re-revision after revision arthroplasty. The most common bacteria are staphylococcus aureus, coag-neg staphylococci, and cutibacterium acnes (in periprosthetic shoulder infections and in chronic infections)<sup>2</sup> (table 1).

### 3. Definition

The definition of PJI is based on several criteria: according to the MSIS guidelines<sup>3</sup>, the diagnosis is based on the presence of at least one of the following points: (1) pus around the prosthesis, (2) a fistula between the prosthesis and the skin, (3) a joint aspiration showing and elevated leucocyte count and/or a high percentage of neutrophils, (4) positive cultures, and (5) histopathologic criteria of inflammation around the prosthesis.

After the MSIS guidelines, various definition criteria have been described, between 2013 and 2020<sup>4-9</sup>, but no single definition has gained acceptance as a reference. The major concerns are the sensitivity of the diagnosis and the diagnosis of low grade infections. In 2021, the EBJIS published a new definition of PJI with a major innovation consisting of a concept of a three-level definition<sup>10</sup> (Figure 1).

According to the EBJIS criteria, the infection can be unlikely, likely or confirmed (see Figure 1). The middle section is of great clinical significance because it can direct medico-surgical teams to treat patients not as having an aseptic loosening of their arthroplasty but as having a prosthetic joint infection.

### 4. Classification

The Coventry classification makes the difference between early, delayed and late infections. However, the trend now is to classify PJI based on the time since primary onset of symptoms<sup>11</sup>, which is correlated to the maturation stage of the biofilm. If the symptoms last less than 3 to 4 weeks the infection is acute, and the implant can be preserved, if the symptoms last more than 3 to 4 weeks, the PJI is chronic and the prosthesis needs to be changed.

Table 1 : Germs distribution in prosthetic joint infection

<i>S. aureus</i>	28.1%
Coag-neg staph	39.6%
G- bacilli	27.6%
<i>C. acnes</i>	4.9%
<i>Streptococcus spp</i>	9%
<i>Enterococcus spp</i>	8%
Anaerobic bacteria	6.8%
No germ found	4-12%

### 5. Diagnosis

Clinically, the patient can present an acute infection, with pain, redness and fever, or a chronic oligosymptomatic infection, more difficult to differentiate from an aseptic loosening. Standard X-rays can give useful information and are usually done first, despite poor sensitivity and specificity. The CT-scan can show collections in the soft tissues and can also be combined with nuclear imaging to better analyse bone inflammation or infection.

Figure 1: EBJIS criteria for suspected periprosthetic joint infection (McNally et al10)

	Infection Unlikely (all findings negative)	Infection Likely (two positive findings) <sup>a</sup>	Infection Confirmed (any positive finding)
<b>Clinical and blood workup</b>			
Clinical features	Clear alternative reason for implant dysfunction (e.g. fracture, implant breakage, malposition, tumour)	1) Radiological signs of loosening within the first five years after implantation 2) Previous wound healing problems 3) History of recent fever or bacteraemia 4) Purulence around the prosthesis <sup>b</sup>	Sinus tract with evidence of communication to the joint or visualization of the prosthesis
C-reactive protein		> 10 mg/l (1 mg/dl) <sup>c</sup>	
<b>Synovial fluid cytological analysis<sup>d</sup></b>			
Leukocyte count <sup>e</sup> (cells/μl)	≤ 1,500	> 1,500	>3,000
PMN (%) <sup>c</sup>	≤ 65%	> 65%	> 80%
<b>Synovial fluid biomarkers</b>			
Alpha-defensin <sup>g</sup>			Positive immunoassay or lateral-flow assay <sup>g</sup>
<b>Microbiology<sup>f</sup></b>			
Aspiration fluid		Positive culture	
Intraoperative (fluid and tissue)	All cultures negative	Single positive culture <sup>g</sup>	≥ two positive samples with the same microorganism
Sonication <sup>h</sup> (CFU/ml)	No growth	> 1 CFU/ml of any organism <sup>g</sup>	> 50 CFU/ml of any organism
<b>Histology<sup>e,i</sup></b>			
High-power field (400x magnification)	Negative	Presence of ≥ five neutrophils in a single HPF	Presence of ≥ five neutrophils in ≥ five HPF
			Presence of visible microorganisms
<b>Others</b>			
Nuclear imaging	Negative three-phase isotope bone scan <sup>c</sup>	Positive WBC scintigraphy <sup>i</sup>	

Figure 1: according to the EBJIS criteria, the infection is unlikely (left yellow column), if there is another reason for implant dysfunction, no CRP, synovial fluid analysis with less than 1500 cells/ul, and if the biomarkers, microbiology and histology are negative.

The infection is likely (middle orange column) in case of two positives findings, for example if there is a positive clinical element or a raised of CRP level, together with another positive test, like >1500 cells/ul in the synovial fluid or a positive culture. This middle section is very important because it can direct clinicians to treat patients not as an aseptic loosening but as an infected patient.

Finally, the infection is confirmed (right red column) if any of the following findings are present: a sinus tract, >3000 leucocytes/ul, >80% PMN, or positive cultures.

## 6. Laboratory Analyses

C-reactive protein (CRP) has a low specificity, a high sensitivity, is easy to perform and is usually done first. Synovial fluid analysis should be performed for every painful arthroplasty before revision. The sensitivity of synovial fluid culture is between 50% and 75% with a good specificity, and the sensitivity can be improved with blood cultures bottles. The intraoperative biopsies should include 3 to 5 samples, and the sensitivity can also be improved with blood cultures bottles. Intra-operative biopsies are currently considered to be the gold standard<sup>12</sup>. The sonication remains under debate<sup>13-15</sup>. The superiority of sonication cultures versus tissue cultures is controversial. The main concerns are false positive cases and the need for a specific infrastructure. In the end, the sonication is not done as a routine, but can be helpful for the diagnosis of PJI when patients are under antibiotic treatment and the cultures of tissue samples are negative.

## 7. Treatment

The principles are surgery, together with empirical and targeted antibiotic therapy. Among surgical options, the debridement, antibiotics, and implant retention (DAIR) is indicated in case of an acute infection, with a stable implant and a non difficult-to-treat (DTT) germ. The principles are a radical excision of necrotic tissues, synovectomy, high volume irrigation and replacement of the mobile parts. The limitations are the inability to perform an adequate debridement and sometimes the impossibility to remove the mobile parts. One stage exchange consists of the removal of the old implant and the re-implantation of a new prosthesis in the same surgery. One stage exchange is indicated in cases with longer duration of symptoms, where biofilm is present. The pathogen must be known, non difficult-to-treat, and the soft tissues need to be intact or only slightly damaged. The outcomes are similar between 1 and 2 stages procedures, with the advantage of doing only one



surgery. The two stage exchange is the removal of the prosthesis with a delayed implantation of a second implant, after a short or a long interval. The indications include unknown or difficult-to-treat microorganisms, several previous revisions and severe soft tissue damage. The drawbacks are a longer hospital stay, a poor functional outcome, and complications related to the spacer (figure 2). Finally, 10 to 20% of patients will have a treatment failure. In these cases, the options are (1) an arthrodesis (usually around the knee, figure 3), (2) a resection arthroplasty (usually in hip infections), (3) an iatrogenic sinus tract, (4) suppressive AB therapy, (5) an amputation, and (6) phage therapy.

## 8. Phage Therapy

Phages are viruses that target bacteria, they are specific to the species of the bacteria they infect, and they replicate inside the bacteria to produce bacterial lysis. Phage therapy<sup>16-17</sup> was first used in humans in the beginning of the last century, and was then abandoned after the rise of the antibiotic era. To date, there are no randomized trials about phage therapy, only case reports or case series. In Geneva, we performed a systematic review of the literature published in the last 20 years<sup>18</sup>. 52 treatment episodes were included, and about half of patients had a prosthetic joint infection. The success rate was 70%. However in the majority of cases phages were given together with surgery and AB, it is therefore difficult to determine the contribution of the phages to the success of the treatment. In conclusion, phages are promising in patients with therapeutic failure, but it is an experimental treatment since there is no legal authorization.

Figure 2: Complications related to a knee spacer

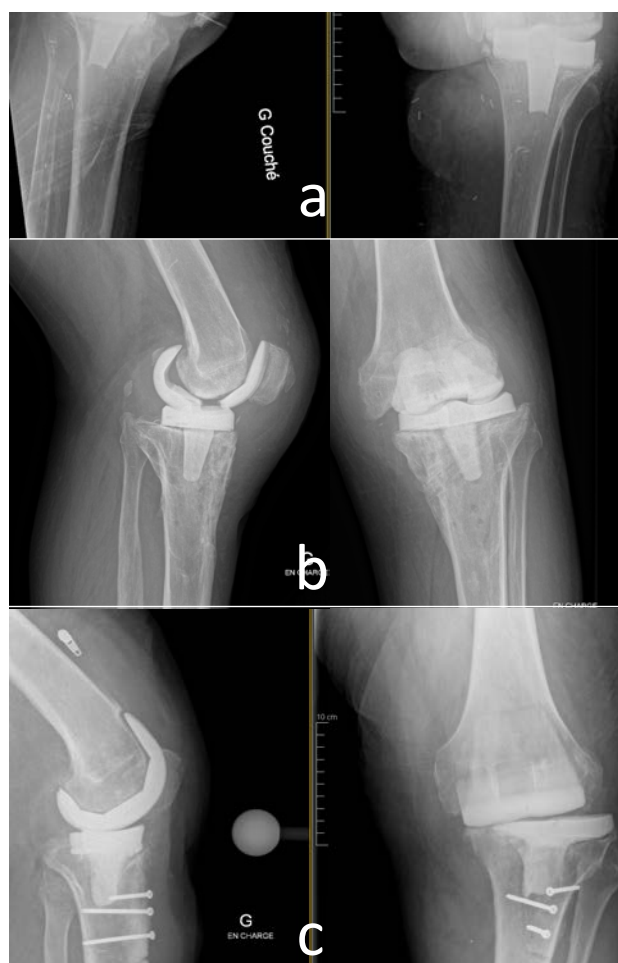


Figure 2: (a) spacer dislocation, (b) spacer breakage (femoral component), (c) spacer subsidence (tibial component).

Figure 3: Illustration of a knee arthrodesis after failed PJI treatment around the knee

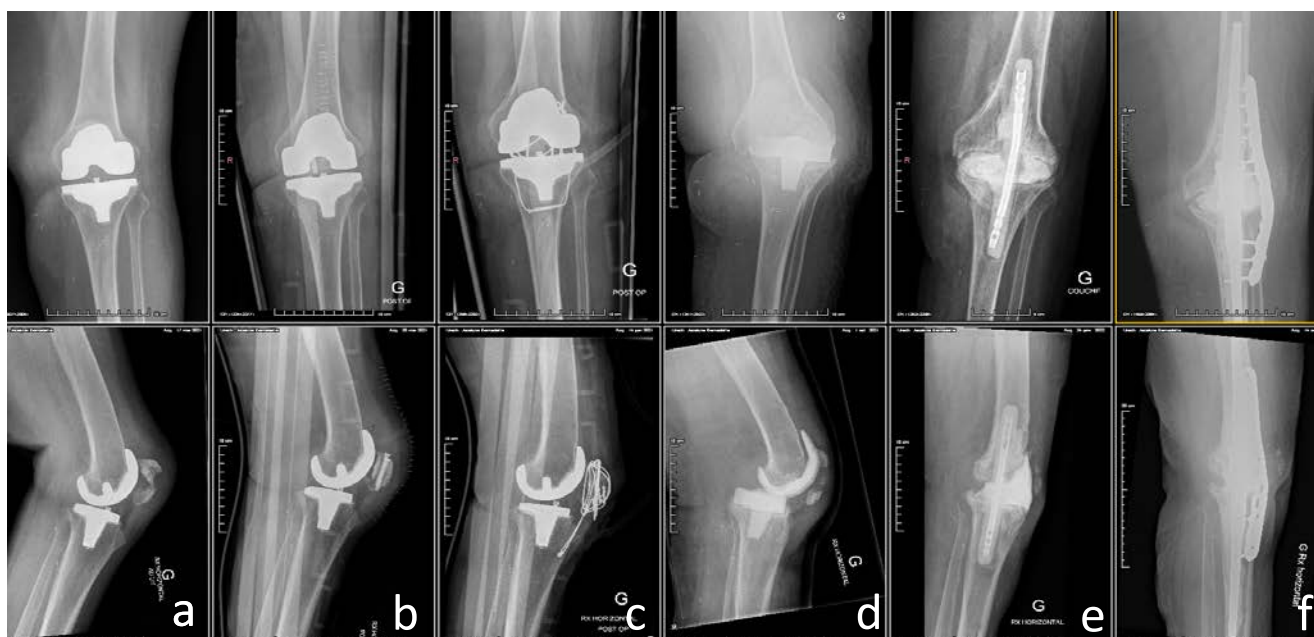

Figure 3: (a-b) 66 year old female underwent ORIF for patellar fracture after TKR. (c) ORIF revision was performed for fixation failure. (d) the patient presented with chronic Methicillin-resistant *Staphylococcus epidermidis* (MRSE) infection and was treated with material and TKR removal and articulated spacer implantation in order to perform a 2-time exchange. (e-f) due to treatment failure, severe soft tissue damage and extensor mechanism deficiency, an arthrodesis was finally performed.

## 9. Conclusion

- PJI requires a multidisciplinary ortho-infectio-plastic approach to ensure a successful treatment.
- The recent and new definition of a middle "infection-likely" group can help in the management of patients which would traditionally not be classified as infected.
- Phage therapy, associated with antibiotics and surgery, is a promising treatment for patients with prosthetic joint infection.

## References:

1. Lubbeke A, Barea C, Miozzari H, et al (2021) Annual report of the Geneva Arthroplasty Registry.
2. Benito N, Franco M, Ribera A, et al (2016) Time trends in the aetiology of prosthetic joint infections : a multicentre cohort study. *Clin Microbiol Infect* 22(8):732.
3. Parvizi et al (2011). New definition for PJI: from the Workgroup of the musculoskeletal infection Society (MSIS). *J Arthroplasty* 26(8):1136-8.
4. Parvizi J, Jacovides C, Zmistowski B, et al (2011) Definition of periprosthetic joint infection: is there a consensus? *Clin Orthop Relat Res* 469(11):3022-30.
5. Parvizi J, Gehrke T, Chen AF et al (2013) Proceedings of the International Consensus on Periprosthetic Joint Infection. *Bone Joint J.* 95-B(11):1450-2.
6. Osmon DR, Berbari EF, Berendt AR et al (2013) Diagnosis and management of prosthetic joint infection: clinical practice guidelines by the Infectious Diseases Society of America. *Clin Infect Dis.* Jan;56(1).
7. Parvizi J, Tan TL, Goswami K et al (2018) The 2018 Definition of Periprosthetic Hip and Knee Infection: An Evidence-Based and Validated Criteria. *J Arthroplasty.* 33(5):1309-1314.
8. Shohat N, Bauer T, Buttar M et al (2019) Hip and Knee Section, What is the Definition of a Periprosthetic Joint Infection (PJI) of the Knee and the Hip? Can the Same Criteria be Used for Both Joints?: Proceedings of International Consensus on Orthopedic Infections. *J Arthroplasty.* 34(2S):S325-S327.
9. Villa JM, Pannu TS, Piuze N et al (2020) Evolution of Diagnostic Definitions for Periprosthetic Joint Infection in Total Hip and Knee Arthroplasty. *J Arthroplasty* 35(3S):S9-S13.
10. McNally M, Sousa R, Wouthuyzen-Bakker M, et al (2021) The EBJIS definition of periprosthetic joint infection. *Bone Joint J* ;10- B(1) :18-25.
11. Li C, Renz N, Trampuz A (2018) Management of Periprosthetic joint infection. *Hip Pelvis* 30(3) : 138-146.
12. Izakovicova P, Borens O, Trampuz A (2019) Periprosthetic joint infection: current concepts and outlook. *EFORT Open Rev* 29;4(7):482-494.
13. Trampuz A, Piper KE, Jacobson MJ (2007) Sonication of removed hip and knee prostheses for diagnosis of infection. *N Engl J Med.*16;357(7):654-63.
14. Cunha Ribeiro T, Kiyoshi Honda E, Daniachi D et al (2021) The impact of sonication cultures when the diagnosis of prosthetic joint infection is inconclusive. *PLoS One* 13;16(7).
15. Dudareva M, Barrett L, Figtree M et al (2018) Sonication versus Tissue Sampling for Diagnosis of Prosthetic Joint and Other Orthopedic Device-Related Infections. *J Clin Microbiol* 27;56(12).
16. Pirnay JP, Ferry T, Resch G (2022) Recent progress toward the implementation of phage therapy in Western medicine. *FEMS Microbiol Rev* 18;46(1).
17. Barrocco C, Meyssonier V, Suva D, et al (2023) Actualités thérapeutiques en orthopédie septique. *Rev Med Suisse* (19) :714-8.
18. Genevière G, McCallin S, Huttner A, et al (2021) A systematic review of phage therapy applied to bone and joint infections : an analysis of success rates, treatment modalities and safety. *EFORT Open Rev* 10;6(12):1148-1156.







*Prof. Pietro Ruggieri*  
*pietro.ruggieri@unipd.it*

*Prof. Andrea Angelini*  
*andrea.angelini@unipd.it*

University of Padova, Department of Orthopedics and Orthopedic Oncology Padova, Italy

## **Diagnostic & Recognition Of Primary Bone Tumours**

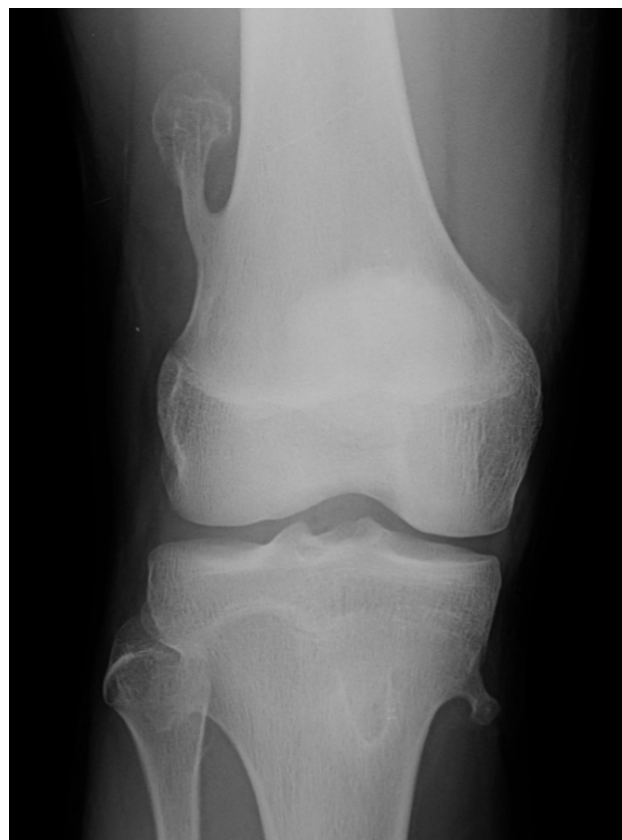The skeleton is affected by many processes that may be interpreted clinically and radiographically as either benign or malignant primary bone tumours. Bone tumours are rare and the correct diagnosis is crucial to guide the treatments. Their diagnosis requires a staged multidisciplinary approach, using clinical, imaging and histological analyses. Imaging evaluation starts with conventional radiography that provides information about the type, site and host bone reaction. Computed tomography (CT) and magnetic resonance imaging, always performed with contrast medium, allow to evaluate intra-medullary extension, soft-tissue involvement and relationship with neuro-vascular structures. Chest CT, bone scan and positron emission tomography are useful to complete staging in malignant tumours. Patient's history and age, anatomical site of the lesion and radiological pattern allow categorization of most of the lesions. However, biopsy is mandatory in most of the cases and represent the final step of the staging. Imaging evaluation is periodically repeated to assess the efficacy of adjuvant treatments and for detection of recurrence and distant metastases. A multidisciplinary approach is needed to treat these tumours, and a collaboration between orthopaedic surgeons, radiologists, pathologists, oncologists and radiotherapists is required.

## **I. Introduction**

Conventional bone lesion classification usually subdivides bone tumours in primary (pseudotumoural, benign or malignant) non-epithelial neoplasms originating from bone cells or their precursors, and, secondary lesions. The last group includes metastatic tumours (i.e. carcinoma metastasis, lymphoma, myeloma), tumours resulting from contiguous spread of adjacent soft-tissue neoplasms and malignant transformation of the pre-existing benign lesions. From the epidemiological point of view, bone tumours are relatively rare and include a wide spectrum of histological types ranging from benign lesions (some of them are not true neoplasms, but rather represent hamartomas) to malignant tumours that invade and destroy bone tissue. Metastatic cancers are the most frequent malignant tumours found in bone. In case of suspected bone tumour, the patient should be early referred to a specialist center to avoid a delay in diagnosis or inadequate treatments, possibly affecting prognosis. The differential diagnosis must be precise and it is achieved by a staged multi-disciplinary approach. The combination of medical history, clinical data, imaging and histology examination are crucial for final diagnosis (and therefore for correct management), and all of these parameters should be consistent.

## **Approach to a patient with a bone lesion**

There is an illustrative saying by an anonymous individual: "A doctor who cannot take a good history and a patient who cannot give one are in danger of giving and receiving bad treatment". As well as in other oncologic specialties, a complete and accurate history, and clinical examination are the cornerstones to build a correct diagnosis algorithm in patients with musculoskeletal tumours. In some cases, diagnosis is easily made by a careful evaluation of history and symptoms, such as in polyostotic fibrous dysplasia, Ollier's disease or Maffucci's syndrome or hereditary multiple exostoses (Figure 1).



*Figure 1: Plain radiograph of the knee in a 17 years-old male affected by hereditary multiple exostoses shows multiples pedunculated osteochondromas in distal femur and proximal tibia*

Table 1. The More Likely Differential Diagnoses By Age		
Age Group	Most Common Benign Lesions	Most Common Malignant Tumours
0 – 10 yrs	Simple Bone Cyst Eosinophilic Granuloma Osteomyelitis Osteofibrous Dysplasia	Ewing's Sarcoma Leukemia Metastatic Neuroblastoma Metastatic Rhabdomyosarcoma
10 – 20 yrs	Non-Ossifying Fibroma Fibrous Dysplasia Simple Bone Cyst Aneurysmal Bone Cyst Osteochondroma (Exostosis) Osteoid Osteoma Osteoblastoma Chondroblastoma Chondromyxoid Fibroma Osteomyelitis	Osteosarcoma Ewing's Sarcoma Adamantinoma
20 – 40 yrs	Enchondroma Giant Cell Tumour	Chondrosarcoma
> 40 yrs	Osteoma Bone Infarct	Metastatic Tumours Myeloma Lymphoma Chondrosarcoma Secondary Osteosarcoma (On Paget's Disease) Chordoma

Other metabolic (i.e. gout) or infective diseases should also be considered and included in clinical history because they may mimic bone tumours or be the substrate for sarcomatous degeneration (i.e. neurofibromatosis, Paget's disease) [8]. With few exceptions (osteosarcoma and Ewing's sarcoma), serum values are usually normal in patients who have a bone tumour. Despite this fact, as a rule, the physician needs to obtain at least a serum calcium, erythrocyte sedimentation rate, alkaline phosphatase, lactic dehydrogenase, immunoelectrophoresis, and complete blood count (CBC). In older patients, tumour markers (i.e. prostate-specific antigen) should be quantified if metastatic disease is suspected; both immunoelectrophoresis and urinary analysis for Bence-Jones protein (if a myeloproliferative disorder is suspected) and uric acid levels can help to exclude gout [12–13].

Age is probably the most important clinical clue (Table 1). In children in the first decade of life, a destructive bone lesion is most commonly metastatic neuroblastoma or rhabdomyosarcoma, or benign lesions such as eosinophilic granuloma; above 5 years it is often a primary bone tumour, while after 40 years, it tends to be metastasis or myeloma [2–3,6,9,12]. Latent benign lesions that remain static or heal spontaneously can be detected as incidental findings on an imaging study done for other purposes at any age [3,16–17].

The most common symptoms that should ring an alarm for bone tumours are pain, malaise, fevers and an enlarging mass. The presence of non-mechanical pain in bone without a history of trauma, lasting more than fifteen days should cause concern

and lead to investigation. We usually underline this concept as the “two weeks rule”. In fact, cancer pain mistakenly attributed to innocuous trauma usually progress to become constant without relief using simple analgesia. Pain may be a symptom of growing aggressive lesions, but also pathologic fracture complicating either benign or malignant tumours (Fig. 2) or a significant local tissue reaction. A palpable mass, depending on the location, depth and size of the lesion, will only be present if the tumour has progressed through the cortex and distended the periosteum [6,13]. A useful rule related to tumour volume is that masses greater than a golf ball (about 5 cm in maximum diameter) and depth to fascia should be considered malignant until proven otherwise [9].

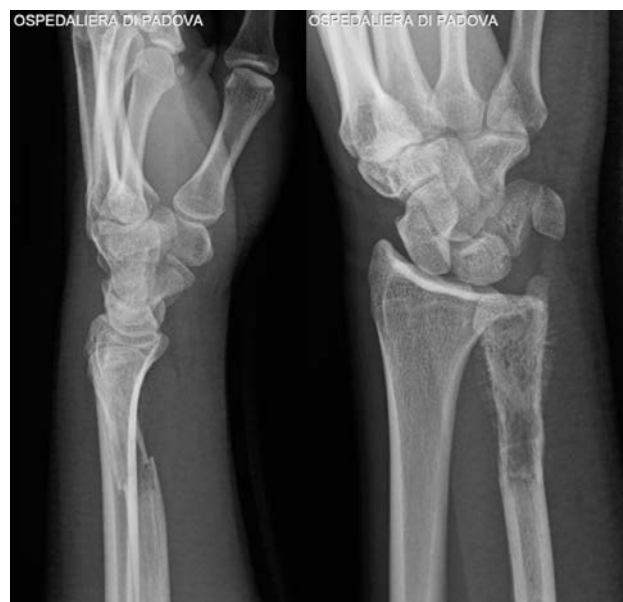

Figure 2: Anteroposterior and lateral views of the wrist in a 18 years-old male performed 7 days after trauma during sport activity show a malignant bone tumour with sunray periosteal reaction and a pathologic fracture. Biopsy confirmed the diagnosis of high grade conventional osteoblastic osteosarcoma.

## 2. Staging: imaging evaluation

Staging is of critical importance, in order to classify different tumours based on relevant prognostic factors and suggest the adequate treatment options for each individual patient (Table 2). Staging must be performed very carefully in any case of bone tumours, specially in sarcomas, because the treatment itself and the outcome as a consequence depend on it [6,9–10,12–15].

Imaging studies play a major role also for staging the disease (local and general), to evaluate response to adjuvant treatments and monitoring relapse during follow-up. Despite the evolution in musculoskeletal imaging, conventional radiographs are important and remain the first step in any patient with persistent bone pain [6,13,17].

Table 2. Objectives Of Staging In Bone Tumours
1. To Aid In Planning The Course Of Treatment
2. To Provide Insight Into The Prognosis
3. To Assist In Evaluating The Results Of Treatment
4. To Facilitate Multidisciplinary Communication
5. To Contribute To Continuing Investigation Of Human Cancer

There are some questions that must be answered when looking at a plane radiograph of a suspected bone tumour:

1. Which bone is affected?
2. Where in that bone is the lesion located?
3. What is the tumour doing to the bone?
4. What is the bone doing to the tumour?
5. What is in the lesion? Are there any types of specific features that may suggest diagnosis (such as periosteal reaction or matrix mineralization etc)?

Answering these fundamental questions is critical to the orthopaedic surgeon in terms of making the correct diagnosis, understanding the different appearances of the lesion and guiding the therapeutic algorithm. Radiographs in two planes provide information about site of the lesion, margins, matrix, mineralization, host periosteal reaction and allowed to identify pathologic fractures [13,16-17]. Most primary bone tumours have a favored location within long bones (Fig. 3); this may provide a clue to diagnosis considering that the site of the lesion is sometimes pathognomonic [13] (Fig. 4), even if exceptions have been reported in literature [7].

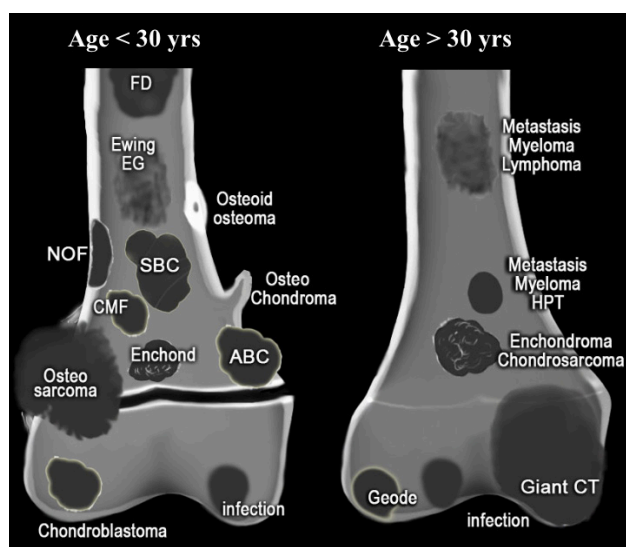


Figure 3: Artistic drawings show the common anatomical location of the most frequent bone lesions within the host bone. FD: fibrous dysplasia; EG: eosinophilic granuloma; NOF: Non-ossifying fibroma; SBC: simple bone cyst; CMF: Chondromyxoid fibroma; ABC: aneurysmal bone cyst; GCT: giant cell tumour; HPT: hyperparathyroidism

Bone tumours and metastases can appear osteolytic, osteoblastic or mixed lytic and sclerotic lesions. Osteolysis is usually caused by the up-regulation of the osteoclasts through the RANK ligand pathway and may be present in three different patterns: geographic bone destruction, moth-eaten appearance or a permeative appearance [13,16]. On the other hand, the reaction of host bone depends on tumour histology, grade and rapidity of growth. The periosteum responds to traumatic stimuli or pressure from an underlying growing tumour by depositing new bone. The radiographic appearances of this response reflect the degree of aggressiveness of the tumour. When the tumour grows too fast, layers of partially formed and partly calcified bone are laid down and the tumour continues to expand through them, resembling in a radiological appearance as "onion-skin". Benign lesions, growing slow, normally do not cause a response from the host bone or periosteum.

Some tumours produce calcifications or ossifications. Tumours

of osseous origin (for example osteoid osteoma, osteoblastoma or osteosarcoma) produce matrix that on radiograph appear as "cloud-like"; cartilage tumours (enchondroma or chondrosarcoma) have mineralization patterns with stippled calcifications (Fig. 5); fibrous tumours have an immature or woven bone matrix described on x-rays as "ground glass". Tumours can cause cortical resorption

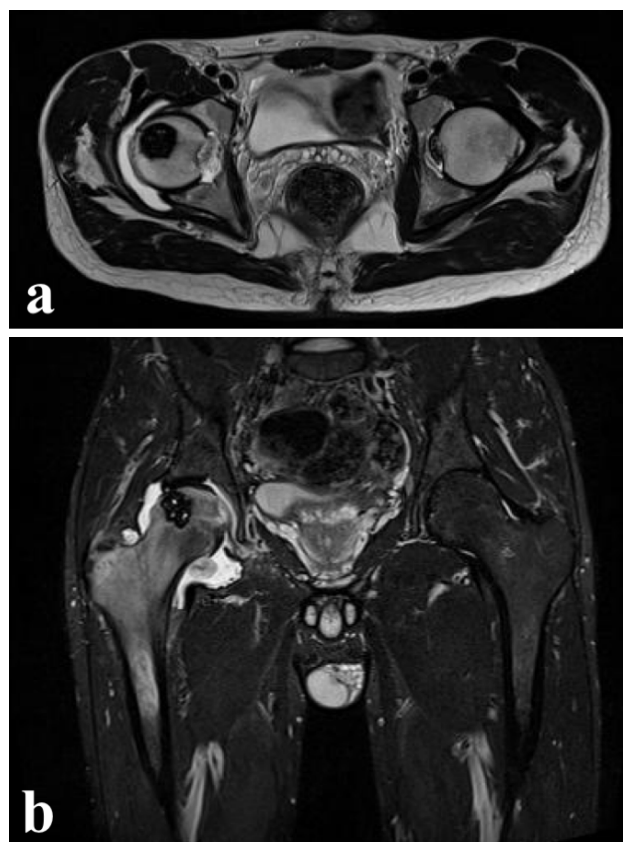

Figure 4: Axial T1-weighted MRI (a) and Coronal STIR (b) showing an epiphyseal osteoblastoma of the proximal femur without soft tissue extension

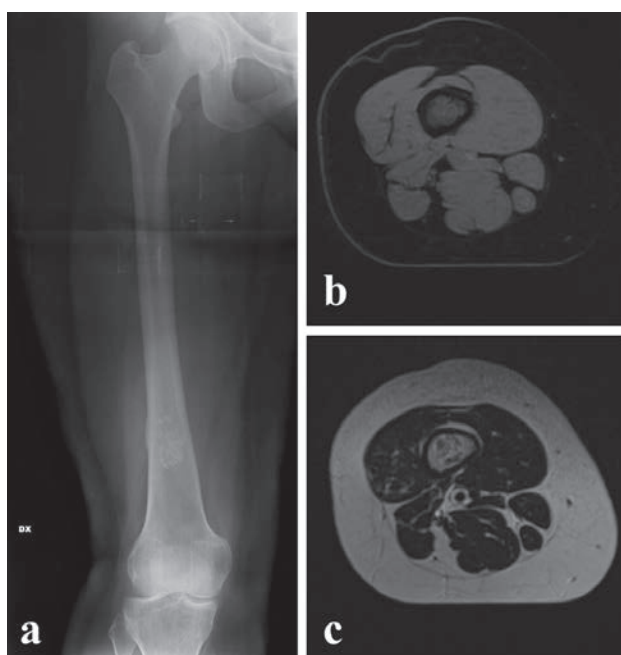


Figure 5: (a) Plain radiograph of the femur reveals an enchondroma with typical appearance of "stippled" calcification in center of bone; (b) Axial T1-weighted MRI demonstrates irregular low signal intensities within the lesion (c) axial T2-weighted MRI shows the sharply defined lobulated margins and characteristic "rings" of chondroid matrix



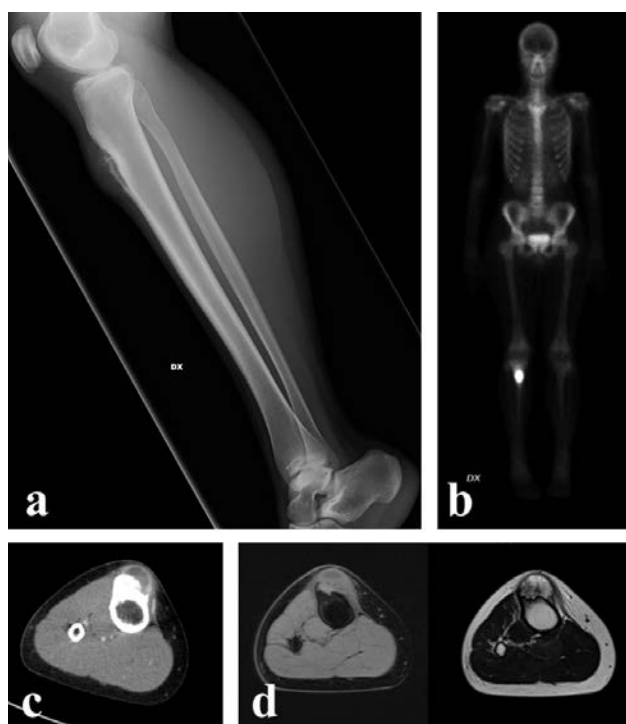


Figure 6: Osteosarcoma of the proximal tibia in a 20-years-old female. a) plain radiograph in lateral view shows destruction of the cortex with soft-tissue extension; b) bone scan demonstrates intense uptake in the proximal tibia without other suspicious lesions; c) Axial CT scan and d) axial MRI show a mass extended into the adjacent soft-tissue

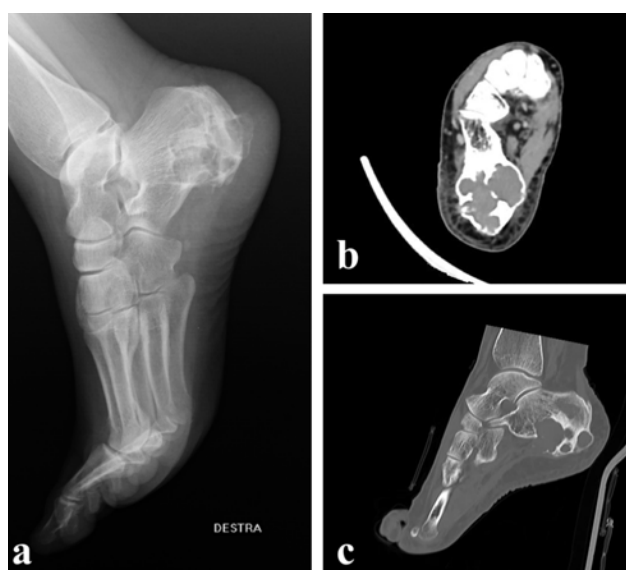

Figure 7: Grade 2 central chondrosarcoma of the calcaneus in a 51-years-old female. (a) lateral radiograph of the ankle and foot shows ill-defined heterogeneous lytic and destructive lesion with soft-tissue extension of the tumour; (b-c) Axial and sagittal CT scan indicating extensive cortical erosion

of bone from within, seen as endosteal scalloping.

Computed tomography (CT) and MRI should be used in case of diagnosis problems or doubt, to visualize more clearly the whole compartment with the adjacent joint and soft-tissue (Fig. 6). CT scan is superior to MRI imaging in the definition of matrix mineralization, calcifications, periosteal bone formation, and it allows an accurate study of the cortical involvement [Fig. 7]. Moreover, CT scan should be performed with contrast medium to detect vascularization of the lesion and correlation with neuro-vascular bundle [16-17]. MRI is the most precise exam to assess the

intramedullary extension of the tumour, to detect skip metastases, soft-tissue involvements and extension to nerves and vessels [4]. The MRI is also useful to identify tumour infiltration of joints. The STIR imaging MRI suppresses fat signal, enhancing the identification of abnormal tissue with increased water content. In aneurysmal bone cyst, fluid levels are better depicted on MRI (that represent the gold standard imaging for diagnosis) than on CT scan [Fig. 8] [4]. With MRI we can evaluate the efficacy of preoperative chemotherapy and radiotherapy treatment through the variation of lesions size, ossification or decrease contrast medium uptake [4].

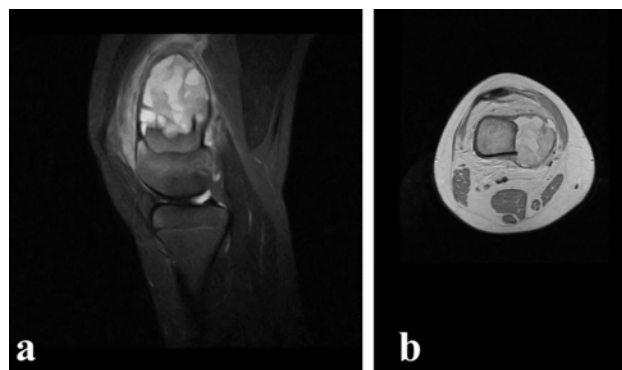


Figure 8: Aneurysmal bone cyst of the distal femur. (a) sagittal T2-weighted MRI and (b) axial T1-weighted MRI showing characteristic multiple fluid levels.

General staging, including total bone scintigraphy, chest radiographs, and CT, should be carried out to assess the extent of distant disease. Bone sarcomas most commonly metastasize to the lungs, therefore, radiography, or CT of the chest is required to accurately assess the lungs for metastasis. A technetium bone scan is useful to identify unsuspected areas of skeletal involvement for similar bone lesions or metastatic bone disease. It was widely used in the past, but it has been largely replaced by positron emission tomography (PET)/CT, that is more sensitive and specific to evaluate the diffusion and metabolic activity of the tumour. Osteoid osteoma and Paget's disease represent the most important bone lesions where pathognomonic features can be observed at bone scan (Fig. 9).

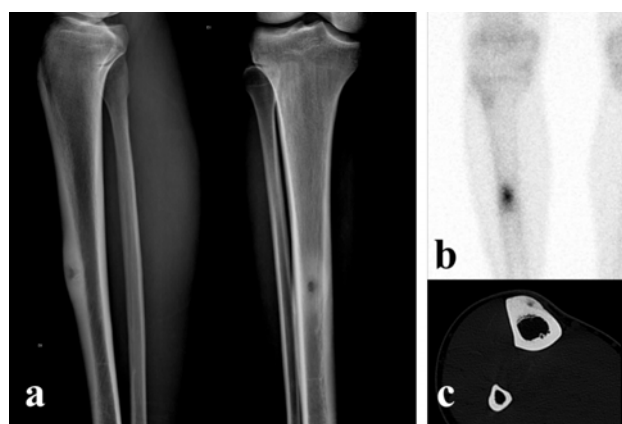
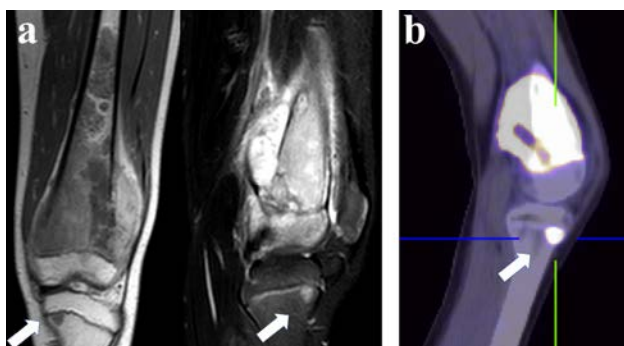


Figure 9: (a) Plain radiographs show intracortical osteoid osteoma of the tibia with reactive cortical sclerosis; (b) bone scan shows a classic "double density" sign; (c) Axial CT scan reveals a typical finding of small "nidus" surrounded by reactive bone.

Total-body MR imaging, PET/CT or PET/MRI are used increasingly to provide complementary information for a variety of indications, especially in sarcomas (Fig. 10). These combined systems enable fast and accurate full-body evaluation, increasing diagnostic and



**Figure 10:** Osteosarcoma of the distal femur. (a) coronal and sagittal MRI show the extensive involvement of the soft-tissue and the intramedullary extension. Moreover, a skip metastasis is identifiable in the tibial growth plate (with arrow); b) PET/CT confirm the increased metabolic activity of both sites.

clinical relevant data from the imaging studies. 18F-FDG-PET/CT has been shown to be very useful in sarcoma detection and grading, staging, biopsy guidance, monitoring response to therapy, restaging for recurrence, and determining prognosis [1,5]. PET/MRI is a hybrid imaging modality which combines the high resolution of MRI in the study of soft-tissue and the peculiarities of PET. More recent studies showed promising results with PET/MRI in sarcomas compared to the currently imaging methods [14].

### 3. Staging: biopsy

Biopsy is the final step of staging and gold standard for the diagnosis. It should be carried out at a reference center and should be performed or supervised by an experienced surgeon in limb salvage for bone sarcomas that has an overview of future definitive surgical plans, or a radiologist member of the team [10-11,15]. There are few exceptions where biopsy may be omitted, because of the lesions present pathognomonic clinically and radiologically features: osteoid osteoma, histiocytic fibroma, osteochondroma, simple bone cyst and fibrous dysplasia [11-12]. However, biopsy is mandatory in doubtful cases. The goal of biopsy is to obtain a diagnostic tissue sample with minimal contamination of normal tissues. Obviously, it should be carried out without complications, tumour spread or compromise of future surgery. Biopsy can be performed with open (incisional or excisional) or percutaneous (core needle) approach. Excisional biopsy has very circumscribed indications: when the lesion is clearly benign or when the malignancy is small and can be removed with wide margins. Core needle biopsy is preferable to open biopsy and should be performed imaging-guided to improve the accuracy. Operatively, needle biopsy should be performed through only one compartment, on the supposed access of the definitive surgery, away from neurovascular bundles, with adequate sampling of representative areas for histology. Tissue samples should be taken from the periphery of the tumour, including health tissue, reactive tissue, capsule/pseudocapsule, and should avoid necrotic tissue. Samples should always be sent for microbiological culture for a potential differential diagnosis when osteomyelitis could be suspected [6,12]. In aggressive benign and malignant bone tumours, the biopsy tract should be considered to be contaminated with tumour and must be removed en-bloc with the resection specimen to reduce risk of local recurrence. If percutaneous biopsy does not allow diagnostic, or the histologic diagnosis is inconsistent with the suspected clinical/imaging pattern, biopsy should be repeated [15].

Repeated imaging-guided biopsy may yield to diagnosis in up to 94% of cases [15].

Although biopsy is an essential operative procedure in the staging, surgeons should know the hazards and the possible complications that may result from a biopsy. An inattentive procedure can lead to non-representative specimens, diagnostic errors, unwanted changes in surgical plan, higher local recurrence and unnecessary limb amputations [10,13,15].

Recently, there has been significant progress in the development of liquid-based biopsy techniques. In principle, liquid biopsy consists in the evaluation of genetic materials or metabolites from a tumour in body fluids. Peripheral blood samples could be analysed measuring circulating tumour cells (CTCs), circulating cell-free nucleic acids, tumour extracellular exosomes and metabolites in the circulation [18]. In the next future, molecular assessment of these circulating materials may complement or even replace the role of tissue biopsies.

### 4. Conclusions

A consensus approach towards diagnostic principles of primary bone tumours has been described. Despite the extreme variety of bone lesions, a clear step-based approach during the diagnostic process is imperative to obtain an adequate staging. All physicians should be able to recognise a suspicious lesion and refer the patient to a reference centre. A multidisciplinary approach including orthopaedic surgeons, radiologists, pathologists, oncologists and radiotherapists with high expertise in musculoskeletal oncology is needed to evaluate and correctly treat bone tumours.

### References:

1. Angelini A, Ceci F, Castellucci P, Graziani T, Polverari G, Trovarelli G, Palmerini E, Ferrari S, Fanti S, Ruggieri P. (2017) The role of 18F-FDG PET/CT in the detection of osteosarcoma recurrence. *Eur J Nucl Med Mol Imaging*. Sep;44(10):1712-1720. This paper reports a large experience on the use of FDG-PET in the detection and restaging of patients with bone sarcomas
2. Angelini A, Hassani M, Mavrogenis AF, Trovarelli G, Romagnoli C, Berizzi A, Ruggieri P. (2017) Chondroblastoma in adult age. *Eur J Orthop Surg Traumatol*. Aug;27(6):843-849. This paper contains substantial clinical information concerning differences in diagnosis and treatment, when a specific bone entity is diagnosed in unusual decade of life
3. Angelini A, Mavrogenis AF, Rimondi E, Rossi G, Ruggieri P. (2017) Current concepts for the diagnosis and management of eosinophilic granuloma of bone. *J Orthop Traumatol*. Jun;18(2):83-90. This review summarizes current concepts in the management of patients with a specific bone tumour in order to underline the importance of age and site in the correct diagnostic algorithm
4. Azouz EM. (2002) Magnetic resonance imaging of benign bone lesions: cysts and tumours. *Top Magn Reson Imaging*. Aug;13(4):219-29. Review. This article reviews the role of MRI in the diagnosis of benign bone tumours

5. Bastiaannet E, Groen H, Jager PL, Cobben DC, van der Graaf WT, Vaalburg W, Hoekstra HJ. (2004) The value of FDG-PET in the detection, grading and response to therapy of soft tissue and bone sarcomas; a systematic review and meta-analysis. *Cancer Treat Rev.* 30:83–101. This review reports the diagnostic value of FDG-PET in the detection, grading and therapy response of soft-tissue and bone sarcomas
6. Bielack SS, Carrle D (2008) State-of-the-art approach in selective curable tumours: bone sarcoma. *Ann Oncol* 19 (Suppl 7):vii155–vii160. This paper contains substantial clinical information concerning diagnosis and treatment of malignant bone entities
7. Capanna R, Van Horn J, Ruggieri P, Biagini R. (1986) Epiphyseal involvement in unicameral bone cysts. *Skeletal Radiol.* 15(6):428–32. A representative paper on exceptions about the favored location of bone tumours within long bones.
8. Carter JM, Howe BM, Inwards CY. (2017) Conditions Simulating Primary Bone Neoplasms. *Surg Pathol Clin. Sep*;10(3):731–748. This article considers a spectrum of reactive and nonreactive processes that can present in such a way that they are mistaken for a tumour arising primary in bone.
9. Grimer RJ, Briggs TWR (2010) Earlier diagnosis of bone and soft-tissue tumours. *J Bone Joint Surg Br* 92-B:1489–1492. This paper highlights the clinical and radiological features that might suggest the possibility of a bone or soft-tissue sarcoma and suggests a succinct management pathway for establishing whether a suspicious bone or soft-tissue lesion could be malignant.
10. Mankin HJ, Mankin CJ, Simon MA, Members of the Musculoskeletal Tumour Society (1996) The hazards of the biopsy, revisited. *J Bone Joint Surg [Am]* 78:656–63. Historic milestone paper regarding the hazards associated with biopsies of primary malignant musculoskeletal sarcomas.
11. Mavrogenis AF, Angelini A, Errani C, Rimondi E. (2014) How should musculoskeletal biopsies be performed? *Orthopedics.* 2014 Sep;37(9):585–8. This editorial discusses the techniques, principles, and errors of biopsies for musculoskeletal tumours from radiologists' and orthopedic surgeons' perspectives.
12. Mavrogenis AF, Angelini A, Vottis C, Palmerini E, Rimondi E, Rossi G, Papagelopoulos PJ, Ruggieri P. (2015) State-of-the-art approach for bone sarcomas. *Eur J Orthop Surg Traumatol.* Jan;25(1):5–15. This article presents the current approach for staging, principles of biopsy, tumour classification, treatment, and follow-up of patients with bone sarcomas
13. Plant J, Cannon S. (2016) Diagnostic work up and recognition of primary bone tumours: a review. *EFORT Open Rev.* Jun; 1(6): 247–253. This review gives information to the process of investigation and differential diagnosis in benign and malignant bone lesions.
14. Platzek I, Beuthien-Baumann B, Schramm G, Maus J, Laniado M, Kotzerke J, van den Hoff J, Schuler M. (2017) FDG PET/MR in initial staging of sarcoma: Initial experience and comparison with conventional imaging. *Clin Imaging.* Mar-Apr;42:126–132. A large on the feasibility of PET/MR with FDG for initial staging of sarcoma.
15. Rimondi E, Rossi G, Bartalena T, Ciminari R, Alberghini M, Ruggieri P, Errani C, Angelini A, Calabrò T, Abati CN, Balladelli A, Tranfaglia C, Mavrogenis AF, Vanel D, Mercuri M. (2011) Percutaneous CT-guided biopsy of the musculoskeletal system: results of 2027 cases. *Eur J Radiol.* Jan;77(1):34–42. One of the greatest series on percutaneous CT-guided biopsy of musculoskeletal lesions
16. Vanel D, Ruggieri P, Ferrari S, Picci P, Gambarotti M, Staals E, Alberghini M. (2009) The incidental skeletal lesion: ignore or explore? *Cancer Imaging.* Oct 2;9 Spec No A:S38–43. Review. Accurate review on the "leave me alone" bone lesions
17. Woertler K. (2003) Benign bone tumours and tumour-like lesions: value of cross-sectional imaging. *Eur Radiol.* Aug;13(8):1820–35. Review. This article reviews the role of CT and MR imaging in the diagnosis of benign bone tumours and tumour-like lesions of bone, especially with regard to differential diagnosis
18. Li X, Seebacher NA, Hornicek FJ, Xiao T, Duan Z. (2018) Application of liquid biopsy in bone and soft-tissue sarcomas: Present and future. *Cancer Lett.* 2018 Dec 28;439:66–77. Accurate review on the new concept of liquid biopsy

## Questions

1. In which of the following findings, magnetic resonance images are superior to CT scan in terms of accuracy?
  - a. Matrix mineralization
  - b. Calcifications
  - c. Periosteal bone formation
  - d. Intramedullary extension of the tumour
  - e. Evaluation Of Cortical Involvement
2. Which of the following malignant bone tumours is more frequent in the first/second decade of life?
  - a. Ewing's sarcoma
  - b. Multiple Myeloma
  - c. Chondrosarcoma
  - d. Secondary osteosarcoma
  - e. Chordoma
3. Which of the following sentences related to biopsy is wrong?
  - a. Fine needle biopsy is adequate for both bone and soft-tissue tumours
  - b. Biopsy is part of the staging
  - c. Biopsy tract should be removed en-bloc with resection
  - d. Excisional biopsy has very circumscribed indications
  - e. Needle biopsy should be performed through only one compartment

## Answers

1d, 2a, 3a.



*Prof. Miklós Szendrői*

Semmelweis University Budapest  
Budapest, Hungary  
szendroi.miklos@med.semmelweis-univ.hu

## Diagnostic Algorithm & Treatment Options In Bone Metastasis

### Introduction

Oncology management is becoming an increasingly serious task in orthopaedic and trauma surgery.

In the past, without well established follow-up protocols, metastases were recognized late and mostly palliative treatments, radiotherapy and pain killing were favoured. Nowadays, modern diagnostic tools (PET-CT, whole body MRI, etc.) included into the follow-up protocols allow an early detection of the metastases. Beside improved chemo-, and radiotherapy, new targeted therapy as bisphosphonates and denosumab (antigen against RANKL) reduce skeletal related events. In the surgery, a broad spectrum of tools for reconstruction of defects and osteosynthesis can be used, many of them by minimal invasive techniques. All these advances result in a significant longer survival for metastatic patients even with multiple metastases. Data from the Scandinavian Skeletal Metastasis Registry about the last decade underline this:

- incidence of cancer has increased by 18%
- mortality of cancer has increased by 2%

Epidemiology And Characteristics Of Skeletal Metastases
- Cancer - 2nd most frequent causative factor for death
- Every fourth person dies of cancer
- USA: 1,2 million new tumour cases annually
- 300.000 metastases in the skeletal system
- 20 % will develop a pathological fracture (Capanna and Campanacci 2001)
- In 65-75 % of bone metastases the primary site is: lung, breast, kidney and prostate
- Imaging: lytic, mixed or sclerotic lesions
- Periosteal reaction is usually absent
- 10-20% are solitary at recognition but multiplication occurs in 1-3 yrs
- Pathological fracture in 20% of the cases Risk factors (Mirel, 1989):
- Size (more than 2 cm)
- Location (lower limb, proximal femur)
- Blastic/lytic
- Pain

Metastases are 80-100 times more common in the skeletal system than primary malignant bone tumours. The bones most frequently involved in decreasing sequence are: lumbar, dorsal, cervical spine, ribs, pelvis, proximal femur and tibia, skull, sternum and humerus. Only 1-2% of these secondary tumours affect the short tubular bones of the hand and foot.

Clinical Signs, Symptoms:
- deep intermittant pain, independent of movement
- often presents weeks or months before x-ray changes are detected but: there are many reports on painless skeletal metastases in the early stages
- pathologic fracture as first episode in 10-30% of cases
- primary cancer in the case history in cc. 60-70% of cases
- laboratory tests can be useful for recognising the primary site, especially in case of prostate, thyroid cancer or myeloma.
- lytic metastases of kidney or lung cancer fracture frequently, while osteoplastic metastases of prostate cancer rarely break and have a good propensity to heal
- SRE (skeletal related events like fracture, cord compression, radiotherapy for bone metastases) is present in 10 to 20% at diagnosis of lung, breast and prostate cancer (increase up to 50% during the follow-up)

### 1. Imaging

In suspected cases, e.g. when there is local bone pain after history of tumour, an X-ray is taken of the area in question and CT, MRI (occasionally PET-CT) scans are added if necessary. In spine, in the opposite of spondylitis the tumour involves single vertebral bodies, invading the intervertebral space only in a later stage. In the lung tubular bones, the lesion may be central, though it is more often eccentric, involving the cortex. Periosteal reaction is in most cases absent. Bone scan is also extremely important to decide if the process is single or multiple (Fig. 1).

Kidney and lung cancer usually produce lytic metastases in the bones, prostate cancer usually sclerotic ones, breast, thyroid and gastrointestinal cancers have most often mixed sclerotic-lytic metastases.



## Diagnostic algorithm for skeletal metastases

(Flow chart for reaching the diagnosis and treatment of skeletal metastases)

When the patient is admitted with a lytic lesion or impending fracture suspicious for a skeletal metastasis, a systematically evaluation is necessary (Fig.1).

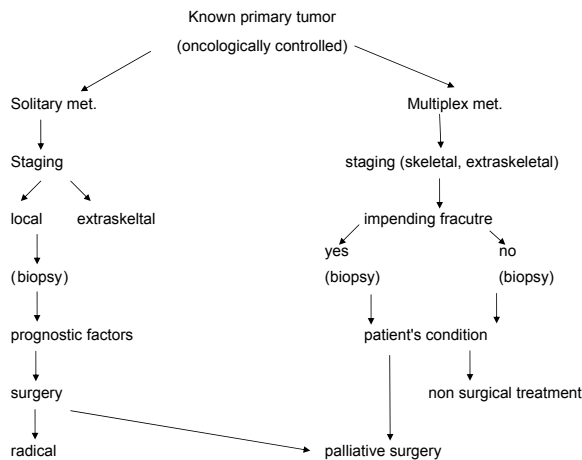


Fig. 1.: Diagnostic algorithym at impending fracture (Known primary tumor)

Figure 1: Diagnostic algorithm for impending fracture

If the primary tumour is unknown, finding the primary site and staging of the primary tumour is of major importance. It determines the treatment of the metastasis whether the primary tumour can be oncologically controlled, excised, irradiated etc. or not. Clinical history, laboratory tests, MRI, bone scan, CT for chest, abdomen and pelvis, and x-ray are helpful to screen the four-five most frequent primary tumours.

The treatment policy differs in pathologic fracture and in traumatic fracture of the extremities.

If x-ray/MRI/CT raise the diagnosis of pathologic fracture:

- Surgery is semi-urgent
- Set up the right diagnosis (primary or secondary bone tumour, tumour-like lesion)
- Look for the primary site
- Evaluate the prognostic factors then decide upon the right surgical intervention

Trauma: osteosynthesis, healing of the fracture

Metastasis: stabilization, weight bearing, mobility

## 2. Prognostic factors

Prognostic factors are related to primary tumour, metastasis and the patient's condition.

- Type of primary tumour is still the most sensitive prognostic factor (Table 1)
- Is the primary tumour oncologically controlled or not (inoperable, etc.)?
- Is the primary site known or does it remain unknown despite careful examination?
- Number of skeletal metastases (soliter versus multiplex)
- Presence of visceral metastases
- General condition of the patient (Karnofsky's index)

Table 1. Average survival of metastatic patients with different type of tumour

Type of primary tumour	Average survival (in months)
Breast cancer	34 months
Prostate cancer	24 months
Cervical cancer	18 months
Kidney cancer	12 months
Melanoma	3,5 months
Lung cancer	3-6 months

- Pathological fracture and age have controversial roles as prognostic factors.

Significant differences can certainly occur within these concerning the oncological stage, histological type, grade, radio- and chemotherapy-sensitivity, presence of hormone-receptors, etc. In some studies patients e.g. with solitary kidney metastases (interval between primary tumour and appearance of the skeletal metastases more than 4 years) had an average survival more than 30 months. It is also known, that the histological grade, hormone receptor status etc. can also change in the metastasis concerning the primary tumour.

The unfavorable prognostic factors are summarized in Table 2.

Table 2. Unfavourable prognostic factors

- Primary tumour: unknown, or oncologically uncontrolled
- Primary site: lung, liver, pancreas or melanoma
- Axial location
- Multiple/multiorganic metastases
- Short doubling time of metastases
- Radio-, chemotherapy resistency
- Synchron or metachron appearance of metastases
- Poor general condition of patient, hemoglobin less than 7 mmol/l

## 3. Surgical treatment

Surgery is rarely the first option in the treatment of skeletal metastases. It is the decision of the oncoteam to recommend radiotherapy, chemotherapy, isotope- or hormon treatment, or targeted therapy (bisphosphonates, denosumab, etc.) in the first line. Surgery is mostly necessary if there is an impending or pathologic fracture, or if indications for curative or ablative surgery are present.

## 4. Aim of surgical treatment:

- To alleviate the pain
- To prevent the imminent fracture
- To osteosynthesize and strenghten the bone in case of pathologic fracture
- Decompress and stabilize the vertebral column in case of neurological complications and instability of vertebra due to pathologic fracture
- Allow the patient to regain his mobility
- Radical excision of solitary metastases
- Improve the quality of life

There is a broad range of the possible surgical procedures for



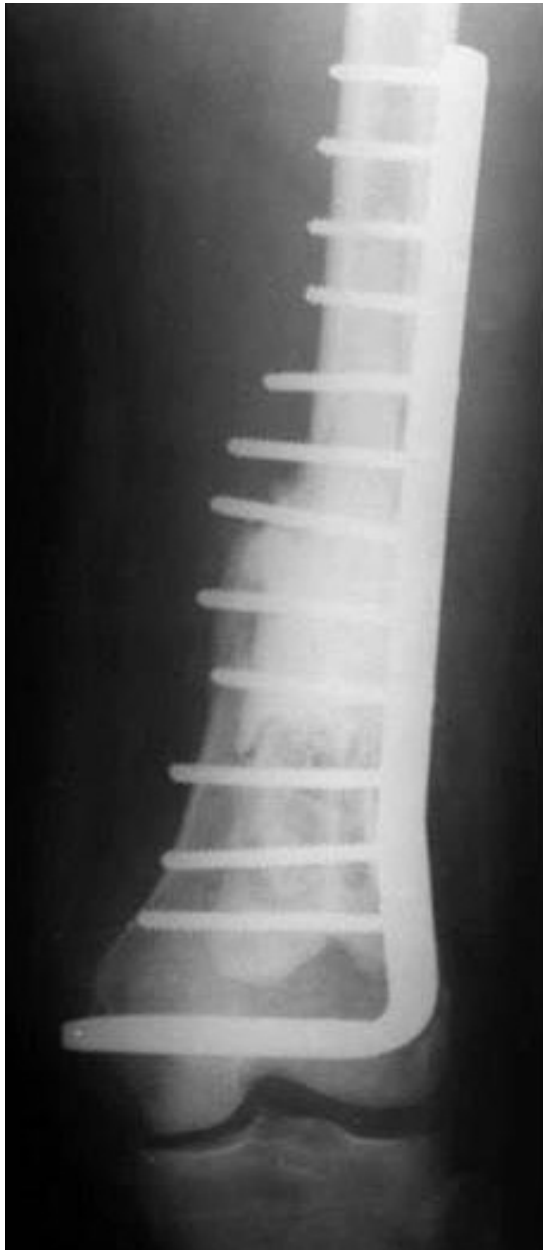
reconstruction of the defect, e.g. plating (Fig. 2), intramedullary nailing (Fig. 3), curetting the defect and filling up with bone cement or insertion of a normal or tumour endoprosthesis. Intramedullary nailing is advantageous for its stable weight-bearing and even if the tumour progresses, loosening of the implant is not likely. In 10-20% of the cases a curative-type radical tumour excision is warranted using limb-saving surgery and reconstruction of the defect by modular tumour endoprosthesis or allograft.

Most common area for the metastatic lesion is the spine. Main indications for surgery are:

- Pain
- Instability
- Pathological fracture
- Cord compression, neurological deficit

Cord compression with neurological deficit can occur unexpectedly and rapidly. Urgent surgery (Fig. 4.) is mandatory, a couple hours of delay can result in a definitive neurologic complication as plegia.

Figure 2: Lymphoma of the femur with pathological fracture .



Plating and augmentation by bone cement was performed.

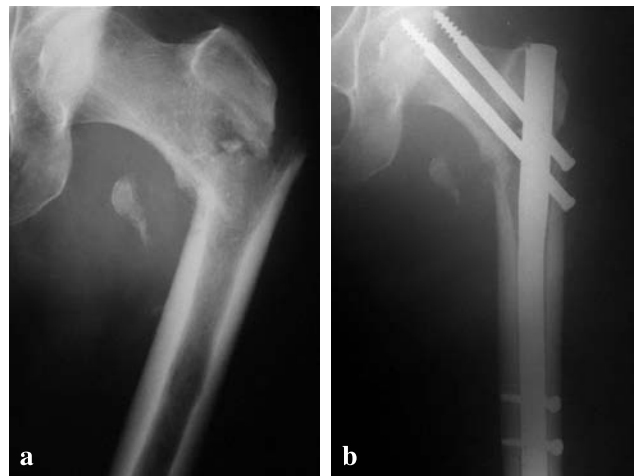


Figure 3: Breast cancer metastasis in the femur with pathologic fracture (a). Intramedullary nail inserted by minimal invasive technique was used for the osteosynthesis (b).

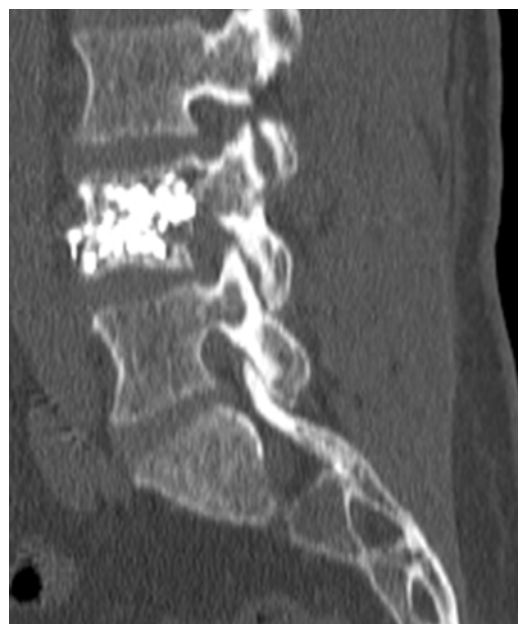
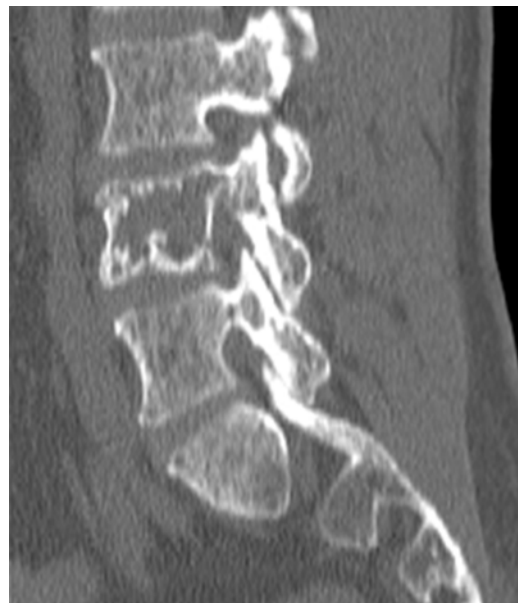
Figure 4: Percutaneous vertebroplasty in a metastatic vertebra with impending fracture

## Summary

- Change in surgical activity for metastatic patient
- Resection of the whole tumour if possible
- Life-long solution by minimal invasive palliative surgery
- Quality of life is an important factor

## References:

1. Breast Specialty Group of the British Association of Surg. Oncol.: The management of metastatic bone disease in the United Kingdom. *Eur J Surg Oncol.*, 25: 3-23, 1999.
2. Capanna R., Campanacci D.: The treatment in metastases in the appendicular skeleton. *J Bone Joint Surg.* 83-B: 471-481, 2001.
3. Fizazi K., Carducci M., Smith M. et al: Denosumab versus zoledronic acid for treatment of bone metastases in men with castration-resistant prostate cancer: a randomised, double-blind study. *Lancet* 377(9768): 813-822, 2011.
4. Ford J.A., Jones R., Elders A. et al: Denosumab for treatment of bone metastases secondary to solid tumours: Systematic review and network meta-analysis. *Eur. J. Cancer*, 49: 416-430, 2013.
5. Greco C, Forte L, Erba P, Mariani G. Bone metastases, general and clinical issues. *Q J Nucl Med Mol Imaging.* 55:337-52, 2011.
6. Katagiri H, Okada R, Takagi T et al. New prognostic factors and scoring system for patients with skeletal metastasis. *Can Med* 2014;3(5): 1359-1367.
7. Kirkinis MN, Lyne CJ, Wilson MD et al. Metastatic bone disease: A review of survival, prognostic factors and outcomes following surgical treatment of the appendicular skeleton. *EJSO* 2016;42:1787-1797.
8. Ratasvuori M., Wedin R., Keller J. et al: Insight opinion to surgically treated metastatic bone disease: Scandinavian Sarcoma Group Skeletal Metastasis Registry report of 1195 operated skeletal metastasis. *Surg. Oncol.* 22: 132-138, 2013.
9. Szendrői A., Dinya E., Kardos M. et al: Prognostic factors and survival of renal clear cell carcinoma patients with bone metastases. *Pahology Oncology Research*, 16: 29-38, 2010.
10. Willeumier JJ, van de Linden YM, van de Sande MA et al. Treatment of pathological fractures of the long bones. *EOR* 2016;1:S28-S37.
11. Hansen BH, Keller J, Laitinen M, et al. The Scandinavian Sarcoma Group skeletal metastasis register. Survival after surgery for bone metastases in the pelvis and extremities. *Acta Orthop Scand* 2004;311:75-79.
12. Randall R. Lor (editor): Metastatic bone disease. An integrated approach to patient care. Springer, 2016. ISBN: 978-1-4614-5661-2.

## Questions

1. Types of cancer which give more frequent metastases into the bone, with the exception of:
  - a. kidney
  - b. prostate
  - c. gastrointestinal
  - d. lung
  - e. breast
2. How frequent pathologic fractures occur in skeletal metastases?
  - a. 1%
  - b. 10%
  - c. 20%
  - d. 30%
  - e. 50%
3. Unfavorable prognostic factors, with exception of:
  - a. breast cancer
  - b. lung cancer
  - c. multiple metastases
  - d. unknown primary tumour
  - e. presence of visceral metastases
4. Frequently affected bones by metastases, with exception of:
  - a. vertebra
  - b. scapula
  - c. pelvic bones
  - d. short tubular bones of hand and feet
  - e. long tubular bones
5. Consequence of a delayed operation in case of pathologic fracture of the vertebra
  - a. permanent pain
  - b. instability
  - c. progression of the tumourous process
  - d. irreversible neurologic complicaiton, plegia
  - e. catastrophoal bleeding

## Answers

1c, 2c, 3a, 4d, 5d



*Prof. Haluk Berk*

Dokuz Eylul University, School of Medicine  
Izmir, Turkey

haluk.berk@deu.edu.tr

## Paediatric Spine Deformities

For normal physiologic functions, the human body requires a spinal column that is coronally and sagittally well aligned. Spine should be able to shift its shape during bodily functions and revert to its original shape after the cessation of the activity. The distortion of the shape of the spine not only creates a cosmetic problem but it also affects the development and the functions of other organs. Spinal deformities may change over time as growing spine almost always carry the risk and potential for progression.

The goal of this work is to provide an overview with up-to-date information on spinal deformities in childhood, including relevant aspects of its initial evaluation, diagnosis, classification, orthopaedic and surgical treatment.

### 1. Development of spine and thorax

Rapid growth of spine occurs during the first 5 years and prepubertal phases, the rate of growth of the spine decreases considerably in between ages 5 to 10 years. The spine acquires half of its adult size in the first 5 years of life and the rest in the period up until puberty. Thus, knowledge of development of the normal spine is very important in order to understand the nature of the deformity and method of treatment.

Thorax and pulmonary development is somehow different from spine development. Alveolar multiplication occurs until the age of 8, first 3 years being the fastest phase. Thoracic capacity is only at the 30% range of adult capacity by the age of 5 and 50% at age 10 and 100% at age 15. On the other hand, spine achieves its 78% of mature height by age 10. It should be kept in mind that deformities that occur before the age of 5 do not only affect spinal alignment but also disturb the development of the thoracic cage and lungs. It is unavoidable that any intervention that permanently alters spine, and thus thoracic growth, will cause pulmonary problems that have a negative effect on cardiac function as well. While planning to treat spinal deformity, prediction of the child's remaining growth has utmost importance on the outcome of the treatment. With the current state-of-art in the treatment of immature spine deformities, one has to judge the pros and cons of fusion, growth modulation and growth-friendly techniques. In small children delaying strategies to postpone surgery have become important. It is also very important to estimate the remaining growth of a child near puberty. Calendar age is not a reliable marker in the evaluation of skeletal maturity. Besides the clinical signs of maturation (menarche, Tanner stages) it is necessary to assess child's maturation by some radiological methods. Risser sign is the most commonly used one, yet it is unreliable if used alone. Risser 0 is a long period that covers Y cartilage closure, peak height velocity and initiation of menses. It

is therefore highly recommended to look for other sites such as hand (Tanner-Whitehouse as popularized by Sanders), olecranon (Sauvegrain method as popularized by Dimeglio). Clinically, peak height growth velocity is the most important indicator.

### 2. Evaluation of deformity

A crucial part of the evaluation of a patient with spinal deformity is to assure whether the diagnosis is idiopathic or has an underlying pathology. Detailed history taking and physical examination should focus on specific items.

The history should include:

- When the spinal deformity was noticed
- Rapidity of change, progression rate
- Associated pain or discomfort and its patterns
- Maturity including onset of menses in females, voice change in boys, and the onset of rapid growth
- Numbness, weakness, difficulty controlling the bowel or bladder, difficulties with vision, hearing, swallowing or severe headaches
- Other medical conditions
- Family history of scoliosis or neuromuscular disorder

A complete musculoskeletal (including neurologic) examination should be performed. Syringomyelia, neurofibromatosis, and Marfan's syndrome, may look like idiopathic but the evaluation must also search for evidence of CNS and spinal tumours or underlying neuropathies or myopathies.

Examination should include:

- Cutaneous lesions
  - Café au lait spots or axillary freckling (suggestive of neurofibromatosis),
  - Spinal hairy patches, haemangioma or sinuses (suggestive of dysraphism and congenital spine)
- Overall morphology
  - Elongated fingers with the "thumb sign" or "wrist sign" (suggestive of Marfan's syndrome)
  - Short trunk or limbs (suggestive of dwarfism)
  - Limb-size discrepancy – potentially associated with neurological causes.
  - Cavus foot, toe clawing, equinus contractures or discrepancy between feet

- Spinal Examination
  - Adam's forward bending test to assess trunk rotation using the scoliometer and a ruler.
  - Trunk shift
  - Waistline and shoulder asymmetry, pelvis level
  - Limb length discrepancy
  - Spinal motion
- Thorough neurological examination
  - The cranial nerves looking for evidence of brain or brainstem abnormalities
  - Muscle strength testing
  - Straight leg raise looking for hamstring tightness or radiculopathy
  - Deep tendon reflexes, clonus, Babinski, Hoffman and Wartenburg
  - Abdominal reflexes (asymmetry suggestive of neurologic pathology)
  - Gait, stance and balance (Romberg's test)

High quality radiographic images from the cervicothoracic junction to the pelvis should be obtained for all patients suspected of having spinal deformity. Low-dose X-ray diagnostic modalities or surface topography imaging techniques offer the ability to initially diagnose and follow at risk patients with a significantly reduced irradiation. Additional workup with MRI should be done in cases of skin abnormalities along the spine, IS in a male patient, a left main thoracic curve, a rapidly progressing curve, scoliosis in a child under 10 years, scoliosis associated to kyphosis, neurological abnormalities at physical examination, pes cavus and/or unilateral amyotrophic calf.

According to the Scoliosis Research Society (SRS) revised glossary of terms, the chronologic definition of IS presentations is:

- Infantile scoliosis - presenting from birth through age 2+11
- Juvenile scoliosis - presenting from age 3 through age 9+11
- Adolescent scoliosis - presenting from age 10 through age 17+11
- Adult scoliosis - presenting from age 18 and beyond

Early Onset Scoliosis (EOS) term refers to scoliosis deformity regardless of aetiology diagnosed before age 10. It represents a group of heterogeneous diagnoses only unified by age at presentation and including infantile and juvenile IS, congenital scoliosis, neuromuscular scoliosis and syndromic scoliosis. (Figure 1)

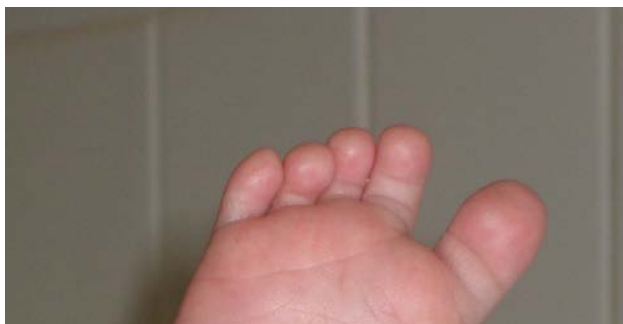

Figure 1: Both clinical and radiologic pictures depicting of a brother and sister having scoliosis. Both are affected with Horizontal Gaze Palsy progressive Scoliosis syndrome. Sister was later operated with dual subcutaneous rods

Location-related classification of a scoliotic curve is based on its apex location. The apex is the vertebra or the disc in a curve most deviated laterally from the vertical axis of the patient that passes through the sacrum (the central sacral line)

- Thoracic: apex at a point between the T2 vertebral body through the T11-T12 disc
- Thoracolumbar: apex at a point between T12 and L1

**Table 1. Classification of spinal deformities by aetiology Structural Scoliosis**

1. Idiopathic
2. Neuromuscular
3. Congenital <ul style="list-style-type: none"> <li>a. Failure of formation</li> <li>b. Failure of segmentation</li> <li>c. Mixed</li> </ul>
4. Neurofibromatosis
5. Mesenchymal <ul style="list-style-type: none"> <li>a. Marfan's syndrome</li> <li>b. Ehlers-Danlos syndrome</li> <li>c. Other</li> </ul>
6. Rheumatoid
7. Trauma <ul style="list-style-type: none"> <li>a. Fracture</li> <li>b. Surgical</li> </ul>
8. Extra spinal contractures <ul style="list-style-type: none"> <li>a. Post burns</li> <li>b. Post empyema</li> </ul>
9. Osteochondrodystrophies <ul style="list-style-type: none"> <li>a. Diastrophic dwarfism</li> <li>b. Mucopolysaccharidoses</li> <li>c. Spondyloepiphyseal dysplasia</li> <li>d. Multiple epiphyseal dysplasia</li> <li>e. Other</li> </ul>
10. Infection of bone
11. Metabolic disorders <ul style="list-style-type: none"> <li>a. Rickets</li> <li>b. Osteogenesis imperfecta</li> <li>c. Homocystinuria</li> <li>d. Others</li> </ul>
12. Related to lumbosacral joint <ul style="list-style-type: none"> <li>a. Spondylolysis and listhesis</li> <li>b. Congenital anomalies of lumbosacral region</li> </ul>
13. Tumours <ul style="list-style-type: none"> <li>a. Vertebral column               <ul style="list-style-type: none"> <li>i. Osteoid osteoma</li> <li>ii. Histiocytosis X</li> <li>iii. Other</li> </ul> </li> <li>b. Spinal cord</li> </ul>



- Lumbar: apex at a point between the L1-L2 disc space through the L4-L5 disc space

## 3. Idiopathic scoliosis

Any disease that is of uncertain or unknown origin may be termed "idiopathic", a word derived from new Latin "idiopathia", Greek "idiopatheia" that is idio- (one's own) + -patheia (feeling suffering). While many theories including biomechanical, hormonal, asymmetry, developmental approaches have been put forward in order to explain the reasons for these deformities, it is still impossible to find a reason in 80% of these curves. (Table 1) Recent studies claim that multifactorial affection on genetic basis might be the reason behind "idiopathic" curves. Therefore, as mentioned above, it is ultimately important to eliminate all other reasons that are known to cause scoliosis, before it is treated as "idiopathic".

Infantile curves (age<3 y.o.) are generally left thoracic, more common in boys and seem to spontaneously resolve without the need for treatment. However, infantile curves have to be closely observed and for those with the inclination to progress, a high level of scrutiny is needed. Mehta's RVAD will be helpful in observation and cast treatment of progressive curves.

Juvenile curves appear between the ages of 4 to 10 according to SRS age classification. Although curves at this age group are alike adolescent idiopathic scoliosis and more thoracic right-sided curves, there was controversy on the treatment modalities. British scoliosis society (BSS) did not take into account this age group as a separate age classification. It was rather called early onset (<5 yo) and late onset (>5 yo) scoliosis. Late onset covers most of the SRS juvenile scoliosis group. Later Growing spine study group proposed early onset scoliosis being a spine deformity less than 10 yo regardless of its aetiology. Yet, it is important to remember that intraspinal pathologies may be seen in juvenile curves in 20% of patients of more than 20 degrees and appropriate MRI evaluation deemed to be necessary.

Adolescent idiopathic scoliosis (AIS) is the most commonly encountered deformity of childhood. It is more common in girls with low BMI and who have an early sudden growth spurt. As the growth of the thorax and the spine are largely completed, neither the deformity, nor the treatment required, cause serious systemic side effects. AIS is predominantly a problem of cosmesis. It causes a loss of balance in the trunk and shoulders and results in a back hump. Pain is not expected until the patients reach their thirties. Painful spine curve unresponsive to conservative treatment deserves further investigation. Osteoid osteoma might be the underlying problem. (Figure 2)

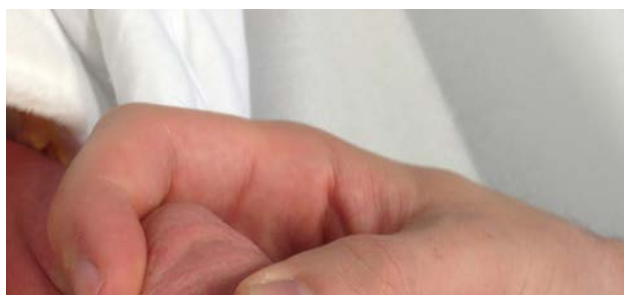


Figure 2: 17-years-old female complains back pain and scoliosis. Bone scintigraphy shows increased uptake in spine and CT images of the related area showed an osteoid osteoma.

Observation, brace treatment and surgery are established treatment modalities.

There is no single recipe for all in the treatment of scoliosis. Treatment plan has to be tailored depending on the gender, curve type, remaining growth and cosmetic problem.

Curves under 20 degrees do not require treatment at any age. There is growing evidence that shows exercise is better than observation. According to SRS-SOSORT criteria, scoliosis exercise may be indicated in adolescents with curves less than 25 degrees and Risser 0-3; adolescents with curves 20 to 29 degrees and a risk of progression 40-60% calculated based on Lonstein progression factor ((Cobb angle-3xRisser sign)/Chronological age).

On the other hand, surgical treatment is generally considered after 40-45 degrees especially in immature patients. Between 20 to 40 degrees, curves exceed the limits of observation and do not reach surgical limits and brace treatment is the only proven to be effective. Fusionless surgery is preferred in young immature patients with curves exceeding 45-50 degrees (see Figure 1). Whereas, patients with Cobb angles 45-50 degrees or more accompanied with trunk shift, shoulder imbalance and proven to be progressive warrants instrumented correction and fusion.

Current state-of-art treatment is the posterior approach using pedicle screws. (Figure 3, Figure 4)

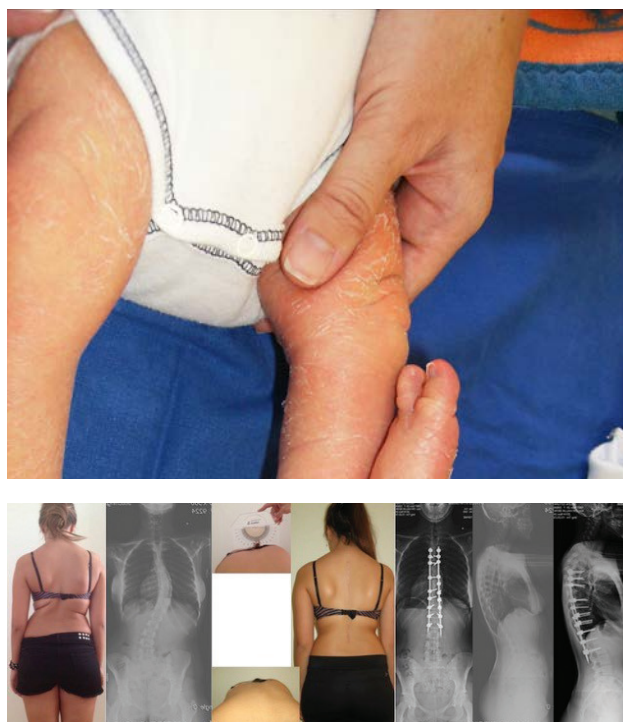

Figure 3: Similar thoracic scoliosis cases operated with different implant densities resulted in similar outcome

Figure 4: 15-years-old female having right thoracic scoliosis is shown. Preoperative Adams forward bending depicts a hump. Postoperative clinical photo shows corrected waistline and shoulder level.

There is however, emerging technology for immature kids (Sanders 2-5, Risser 0-3, Cobb angle between 35-60 degrees) that yields promising results. Dr. Alanay et al. has presented the 2 year follow-up results of 14 consecutive Lenke 1 curves underwent Vertebral Body Tethering (VBT) and showed that patients achieved

44% , 78% and 83% spontaneous correction for upper thoracic, main thoracic and lumbar curves respectively without fusion. (Figure 5)

## 4. Congenital deformities

The term "congenital scoliosis" refers to a spinal deformity caused by vertebrae that have not formed properly. The defect occurs early in life and no cause has been definitely associated with the condition. However, it has serious consequences on spinal growth. A process called somitogenesis, which produces transient segments of tissue known as somites, forms axial skeleton. Disruptions in somitogenesis that usually occurs during the first 4-6 weeks of intrauterine life have been shown to result in vertebral malformations such as hemivertebrae and wedge vertebrae, block vertebrae, and butterfly vertebrae. Notch, FGF and Wnt pathways have been associated with the process of somitogenesis. Associations with Carbon Monoxide exposure, maternal diabetes and anti-epileptic drugs have also been proposed. Familial incidence is about 1 - 5%.

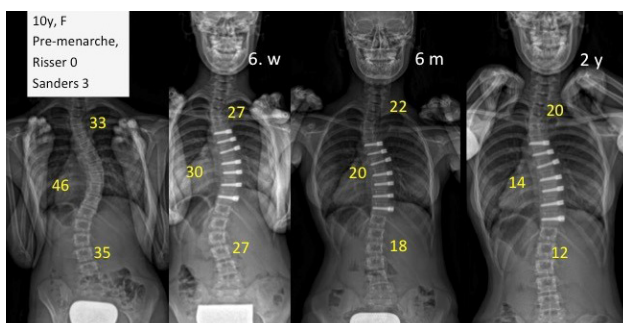


Figure 5: 10-years-old girl having 33° upper thoracic, 46° main thoracic and 35° lumbar curves. She is premenarcheal, R0 and Sanders 3. Preoperative SRS-22 score was 3.6 (Function 4.2, pain 3.6, Self-image 3, mental health 3.6, Satisfaction 4.5). She has undergone thoracoscopic VBT. At 2 years follow-up all measured curves regressed (20° upper thoracic, 14° main thoracic and 12° lumbar) and SRS-22 total score was 4.6 (Function 4.8, pain 4.8, Self-image 4.6, mental health 4.2, Satisfaction 5).

Formation defects cause hemivertebrae while segmentation defects cause bridges between vertebral segments (unsegmented bars). The natural progression of congenital scoliosis can show great variation from patient to patient.

Table 2. Figures show yearly change in the Cobb angles.						
	Block	Wedge	Hemi	Hemix2	USB	USB +Hemi
UpT	<1-1°	*-2°	1-2°	2-2.5°	2-4°	5-6°
T	<1-1°	1-2°	2-2.5°	2-3°	5-6.5°	6-7°
TL	<1-1°	1.5-2°	2-3.5°	5° -*	6-9°	>10° -*
L	<1-1°	<1° -*	<1-1°	*	>5°*	*
LS	*		<1-15°	*	*	*

\*Insufficient number; Green no fusion; Yellow/Grey fusion needed  
UpT: Upper thoracic, T: Thoracic, TL: Thoracolumbar, L: Lumbar, LS: Lumbosacral.  
Hemi: Hemivertebra, USB: unsegmented bar. McMaster MJ JBJS 64A-1128

Unsegmented bar on one side and a hemivertebra will be the worst prognosis. Hemivertebrae located in the cervicothoracic and lumbosacral areas of the spine show a rapid progression.

One should be aware of concurrent congenital pathologies as many develop in the same embryological period. The most commonly observed and most important accompanying anomalies are those related to the spinal cord such as diastematomyelia, diplomyelia, intraspinal lipomas, syringomyelia, Arnold-Chiari malformations and tethered cord syndrome. Twenty per cent of patients have renal anomalies and congenital heart anomalies are not rare.

The aim of treatment in congenital scoliosis is having a stable balanced spine and arrest the progression of deformity while allowing spinal growth. (Figure 6)

Non-surgical treatment is seldom effective but nevertheless has some role to play in selected cases.

Most studies focusing on congenital scoliosis have pointed out that due to the presence of severe deformity and the risk of high rate of progression without treatment, the outcome usually is unfavourable. Of the untreated cases, only 10% have a curve of 20 degrees or less, and 64% have curves that are greater than 40 degrees.

It should be kept in mind that spine with congenital anomalies already lack the normal growth potential of their healthy counterparts and that these children will have shorter stature than their peers in adulthood even if fusion is not performed. Before the age of 5, fusing convex side of the deformity and allowing the growth of only the concave side may result in some spontaneous correction over time (hemiepiphysiodesis). In cases where the deformity is severe, resection of the hemivertebra presents an effective method (Figure 7). When the deformity comprises more than one vertebral segment, acutely kyphotic, more than one segment - including adjacent disks - may have to be resected (vertebral column resection).

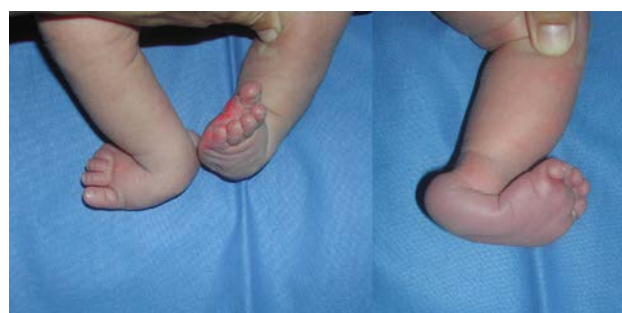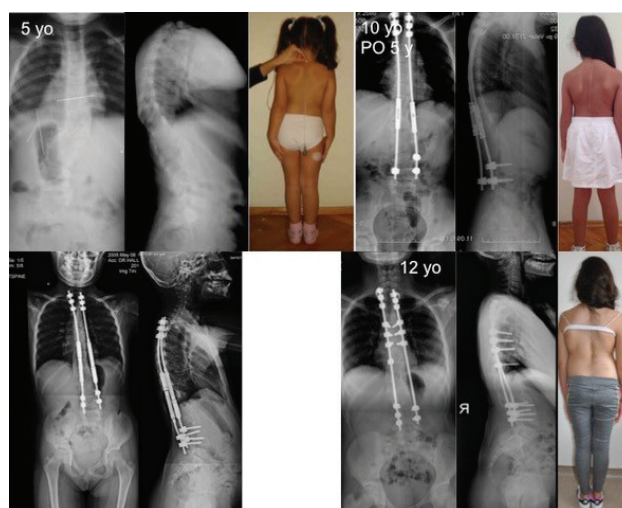


Figure 6: 5-years-old congenital scoliosis. She was operated due to documented increase in curve and trunk shift. Subcutaneous dual rod managed to balance her. Later in the course rods were replaced with magnetically controlled rods. At the age of 12 definitive fusion was carried out. Fusionless surgery allowed 11.6 cm lengthening of the spine.

Figure 7: 3-years-old girl. Single isolated hemivertebra was treated with hemivertebrectomy.

## 5. Neuromuscular spine deformities

Scoliosis is common in patients with neuromuscular diseases. Table 3 summarizes neuromuscular scoliosis types. Neuromuscular deformities generally are C type and involve a large number of vertebrae. They resemble a collapsing spine, which often includes pelvis as well. The larger the curves get, more sitting imbalance occurs and pulmonary problems arise. Window of opportunity is usually in between, where pulmonary functions are favourable and spine deformity has started to progress. Brace treatment generally does not affect the natural history of scoliosis in these patients.

Table 3. Neuromuscular scoliosis classification
1.0 Neuropathic
1.1 Upper motor neuron
1.1.1 Cerebral palsy
1.1.2 Spinocerebellar degeneration
1.1.2.1 Friedrich's ataxia
1.1.2.2 Charcot Marie-Tooth disease
1.1.2.3 Roussy Levy disease
1.1.3 Syringomyelia
1.1.4 Spinal cord tumour
1.1.5 Spinal cord trauma
1.2 Lower motor neuron
1.2.1 Poliomyelitis
1.2.2 Traumatic
1.2.3 Spinal muscular atrophy
1.2.3.1 Werdnig-Hoffmann
1.2.3.2 Kugelberg-Welander
1.2.3.3 Letterer Siwe
1.2.4 Myelomeningocele
1.3 Dysautonomia (Riley-Day syndrome)
2.0 Myopathic
2.1 Arthrogryposis
2.2 Muscular dystrophy
2.2.1 Duchenne's
2.2.2 Limb-girdle
2.2.3 Fascioscapulohumoral
2.3 Fiber type disproportion
2.4 Congenital hypotonia
2.5 Myotonia dystrophica

Considering altered life expectancy and quality of life both patient and caregiver's surgical treatment should not be postponed. Epilepsy - especially seen in Cerebral palsy patients - imposes difficulty in management. The goals and treatment methods are therefore different from idiopathic curves. Usually longer fusion (often to the pelvis) is needed. (Figure 8) Due to nature of underlying disease surgical treatment is prone to complications.



Figure 8: 14-years-old male. Lumbar curve due to neuromuscular scoliosis resulted in progressive sitting imbalance. Postop image depicts balanced sitting posture


## References:

1. Acaroglu E, Bobe R, Enouf J, Marcucio R, Moldovan F, Moreau A. The metabolic basis of adolescent idiopathic scoliosis: 2011 report of the "metabolic" workgroup of the Fondation Yves Cotrel Eur Spine J. 2012; 21: 1033-1042.
2. Akbarnia BA, Breakwell LM, Marks DS, McCarthy 1. RE, Thompson AG, Canale SK, Kostial PN, Tambe A, Asher MA; Growing Spine Study Group. Dual growing rod technique followed for three to eleven years until final fusion: the effect of frequency of lengthening. Spine 2008; (33): 984-90.
3. Bollini G, Bergoin M, Labriet C, Jouve JL, Cottalorda J. (1992) Hemivertebrae excision and fusion in children aged less than five years. J Pediatr Orthop B 1:95-101.
4. Campbell RM Jr, Smith MD, Mayes TC, Mangos JA, Willey-Courand DB, Kose N, Pinero RF, Alder ME, Duong HL, Surber JL. (2003) The characteristics of thoracic insufficiency syndrome associated with fused ribs and congenital scoliosis. J Bone Joint Surg Am. 85:399-408.
5. Deschines S, Charron G, Beaudoin G, Labelle H, Dubois J, Miron MC, Parent S. Diagnostic imaging of spinal deformities: reducing patients radiation dose with a new slot-scanning X-ray imager. Spine 2010 (20); (35):989-94.
6. Dimeglio A, Charles YP, Daures JP, de Rosa V, Kabore B. (2005) Accuracy of the Sauvegrain method in determining skeletal age during puberty. J Bone Joint Surg Am. 87:1689-96.
7. Duval-Beaupere G. Pathogenic relationship between scoliosis and growth. Orthop Clin North 1988; (19): 58-64.
8. Farley FA, Hall J, Goldstein SA. Characteristics of congenital scoliosis in a mouse model. J Pediatr Orthop 2006; 26(3): 341-6
9. Giampietro PF, Dunwoodie SL, Kusumi K, et al. Progress in the understanding of the genetic etiology of vertebral segmentation disorders in humans. Ann N Y Acad Sci 2009; 1151: 38-67
10. Lonstein JE. Scoliosis: Surgical versus nonsurgical treatment. (2006) Clin Orthop Relat Res. 443:248-592.
11. McMaster MJ, Ohtsuka K. (1982) The natural history of congenital scoliosis. J Bone Joint Surg Am 64:1128-1147.



12. Mehta MH. Growth as a corrective force in the early treatment of progressive infantile scoliosis. *J Bone Joint Surg* [2005;87-B:1237-47.
13. Mehta MH. The rib-vertebra angle in the early diagnosis between resolving and progressive infantile scoliosis. *J Bone Joint Surg* 1972;54-B:230-43
14. Nascia RJ, Stilling FH III, Stell HH. Progression of congenital scoliosis due to hemivertebrae and hemivertebrae with bars. *J Bone Joint Surg Am* 1975; 57(4): 456-66.]
15. Negrini S, Minozzi S, Bettany-Saltikov J, Zaina F, Chockalingam N, Grivas TB, Kotwicki T, Maruyama T, Romano M, Vasiliadis ES. Braces for idiopathic scoliosis in adolescents. *Spine* 2010; (35): 1285-93.
16. Negrini S, Minozzi S, Bettany-Saltikov J, Zaina F, Chockalingam N, Grivas TB, Kotwicki T, Maruyama T, Romano M, Vasiliadis ES. Braces for idiopathic scoliosis in adolescents. *Cochrane Database Syst Rev*. 2010 Janv 20; (1). CD006850.
17. Nelson S, Sanders J. Idiopathic scoliosis 2018 available at <http://etext.srs.org/book/> accessed 10.2.2018,
18. Pahys JM, Guille JT. What's New in Congenital Scoliosis? *J Pediatr Orthop*. 2018; 38: e173
19. Parent S, Newton PO, Wenger DR. (2005) Adolescent idiopathic scoliosis: Etiology, anatomy, natural history, and bracing. *Instr Course Lect* 54:529-36.
20. Sanders JO, Khoury JG, Kishan S, Browne RH, Mooney JF, Arnold KD, Sharon McConnell J, Bauma JA, Finegold DA. Predicting Scoliosis Progression from Skeletal Maturity: A Simplified Classification During Adolescence. *J Bone Joint Surg -A* 2008; 90:540-53.
21. Shahcheraghi GH, Hobbi MH. Patterns and progression in congenital scoliosis. *J Pediatr Orthop* 1999; 19(6): 766-75
22. Suk SI, Kim JH, Kim WJ, Lee SM, Chung ER, Nah KH. (2002) Posterior vertebral column resection for severe spinal deformities. *Spine* 27:2374-8.
23. Uzumcugil A, Cil A, Yazici M, Acaroglu E, Alanay A, Aksoy C, Surat A. (2004) Convex growth arrest in the treatment of congenital spinal deformities, revisited. *J Pediatr Orthop*. 24:658-66.
24. Wang WJ, Yeung HY, Chu WC, Tang NL, Lee KM, Qiu Y, Burwell RG, Cheng JC. Top theories for the etiopathogenesis of adolescent idiopathic scoliosis. *J Pediatr Orthop* 2011; (31): S14-27.
25. Winter RB, Moe JH, Lonstein JE. (1984) Posterior spinal arthrodesis for congenital scoliosis. *J Bone Joint Surg* 66A: 1188-1197.
26. Wybier M, Bossard P. Musculoskeletal imaging in progress: The EOS imaging system. *Joint Bone Spine*
27. Yazici M, Asher MA, Hardacker JW. (2000) Safety and efficacy of Isola-Galveston instrumentation and fusion in the treatment of neuromuscular spinal deformities. *J Bone Joint Surg Am* 82:524-43.
28. Yazici M, Yilmaz G. (2011) Congenital scoliosis. In: Akbarnia B, Yazici M, Thompson GH (eds) *The growing spine*. Springer Berlin Heidelberg, pp: 213-28.





Dr. Guillem Saló, MD, PhD  
Autonomous University of Barcelona, Barcelona, Spain  
gsalobru@gmail.com

Gemma Vilà Canet, MD, PhD  
Parc de Salut Mar, Barcelona, ICATME, Hospital, Quirón-Dexeus, Barcelona  
Gvila@psmar.cat

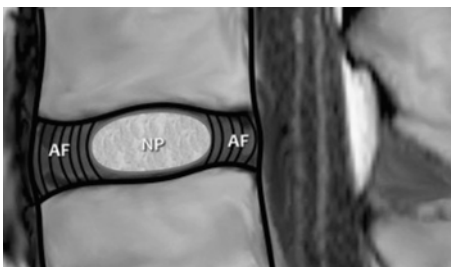
## Degenerative Spine Diseases

### I Prevalence of Lumbar Degenerative Disease

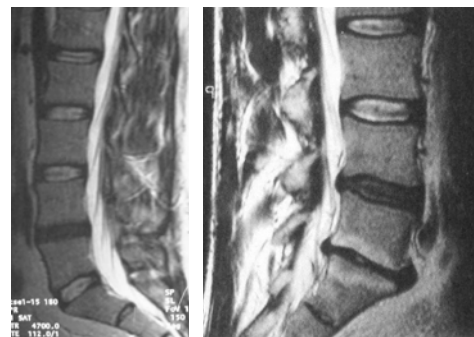
1. 70-80% of all individuals will experience low back pain at some time in their lives; usually it resolves in some weeks
2. Low pain is the leading cause of disability in people younger than 50 years of age
3. Many sources of pain are described
  - 3.1 facet joint arthropathy
  - 3.2 discogenic pain or annular tears
  - 3.3 spondylolisthesis
  - 3.4 spinal stenosis

### II Disc Components

The disc consists of a fibrous outer annulus fibrosus with obliquely oriented collagen I molecules, and softer inner core called nucleus pulposus, which cushions force predominantly type II collagen molecules. Reduced water and glycosaminoglycan content and increased non-collagen glycoprotein are considered characteristic features of degeneration of a disk.



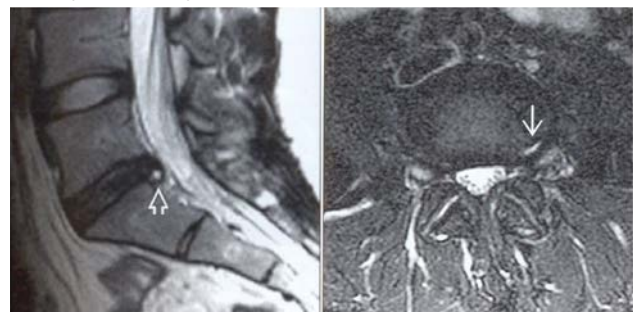
A. L4-L5 selective DDD B. Modic Changes in L5-S1



A. L4-L5 selective DDD B. Modic Changes in L5-S1

Modic type	T1 signal	T2 signal
Modic I	EDEMA decrease	Increase
ModicII	FAT DEGENERATION increase	Increase
ModicIII	ESCLEROSIS decrease	Decrease

6. HIZ changes: High Intensity Zone in T2 localized annulus posterior or posterolateral layer



Images of annular tears corresponding with HIZ in L5-S1

### III Dark Disc Disease DDD

1. MRI image with a degenerative disk disease degree IV
2. Participates in the degenerative and physiologic cascade starting from 30 years old
3. When appearing in a precocious time, in young people, could be symptomatic
4. Structural and biochemistry changes put up with alteration of biomechanics properties
5. Modic changes in MRI describes different situations around DDD

Disk tear lesion predictor, vascularized granulomatous tissue, highlighted with Gadolinium Strong relationship with positive discography but not always with clinical significance.

### IV Lumbar Disc Herniation

1. General overview
  - a. Incidence: 80% of people have some episode of low back pain in life, but only 2-3% have true sciatica
  - b. Age: Average starting age 35 years old. Unusual before 20 and after 60 years. Less frequent in old people, more common associated with stenosis.
  - c. Sex: Similar in both but delayed one decade in females

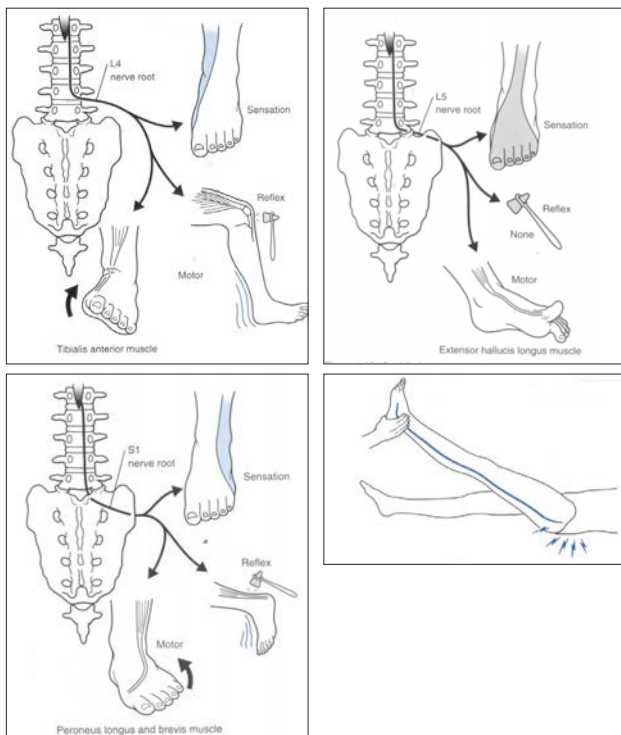
## 2. Anatomy

- Caudal segments are affected more commonly L5-S1 discretely more frequent than L4-L5 less frequent in thoracic and high lumbar level
- Frequently posterolateral
- Central location will cause lumbar pain without sciatica
- Foramina location more frequent in elderly people; high levels (L3-L4)
- Intradural location very unusual

## 3. Clinical features Radiculopathy

- Leg pain > lumbar pain
- Dermatome distribution
- Increase sitting positions and forward bending
- Improve with bed rest

## 4. Physical exam



## 5. Diagnostic imaging

### 5A. RNM

- modality of choice for LHD
- T2-weighted images most commonly used
- T1-weighted + Gadolinium can differentiate between scar tissue and herniated disc material

### 5B. Discography + TAC useful tool in recurrence

## 6. Treatment

### 6.1 Non-surgical treatment:

- LDH has a favourable prognosis  
90% report improvement of symptoms (natural history)
- Short rest (3-5 days)
  - NSAIDs (more effective than placebo)
  - Physical therapy (extremely beneficial)
  - Epidural steroid injections (50% avoided surgery)

### 6.2 Surgical treatment: Conventional discectomy

Patient who failed to improve with non-surgical treatment will probably need surgery.

Surgical treatment provided an increase in quality of life in comparison to continued non-surgical treatment.

The Paraspinal splitting approach (Wiltse approach) is recommendable for extraforaminal disc herniation. Recurrent lumbar disc herniation has been reported in widely varying incidences between 3% and 18% of the patients and depends on the duration of the follow-up.

## V Lumbar Spinal Stenosis

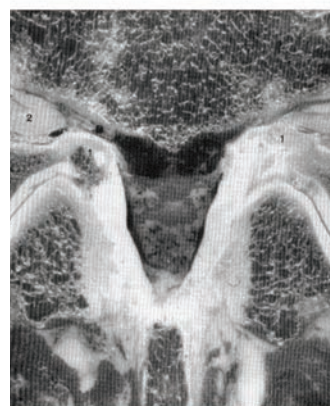
### A. Definition

Spinal stenosis simply means a decrease in the space available for the neural elements, and, in the lumbar spine, the cauda equina. It can occur at different levels: the central canal, the lateral recess or the intervertebral foramen causing neurological compression.

### B. Physiopathology

It is the final result of a cascade of events.

- The event that begins the process is thought to be the disc degeneration.
- As the disc height decreases, the loading characteristics of the facet joints are altered.
- Facet joints capsules become incompetent, leading to capsular, ligamentous flavum, and facet hypertrophy.
- The final result of this continuum of changes is a decrease in the diameter of the spinal canal.



### C. Diagnostic imaging

- Upright AP, lateral, and flexion-extension radiographs amount of lumbar degeneration, vertebral deformity and instability.
- EMG may be helpful to distinguish peripheral neuropathy from LSS.
- Myelography: useful when deformity exists.
- CT scan: facet joints hypertrophy, disc vacuum, size of disc height and foramen height.

- MRI is currently the recommended advanced imaging modality to evaluate LSS. Non invasive technique. If there is discordance between clinical and lumbar MRI, cervical spine should be reviewed. The association between cervical and lumbar stenosis is common.

## D. Treatment

### D1. Non-surgical

- 1) Narcotics, NAIDs, anticonvulsants
- 2) LS orthotics
- 3) Physical therapy: flexion-based lumbar stabilization program
- 4) Steroid injections

### D2. Surgical treatment

#### 1) Indications:

Caudal equine syndrome

Severe neurologic deficit or impairment

Failure to improve leg pain and neurogenic claudication after non-surgical treatment.

Persistent and severe worsening in patient quality of life.

#### 2) Natural history

Not well understood.

It is typically favourable with only 15% deteriorating clinically.

Improvement occurs in 30% to 50% of patients.

#### 3) Operative technique

Preoperative medical evaluation

Elderly patients

Coexisting comorbidities

Save blood preoperative techniques

Self-saver postoperative

Laminectomy

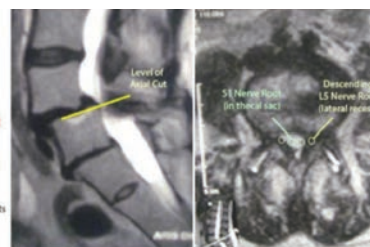
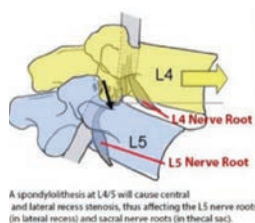
Lateral decompression into the lateral recess and into the foramen

Fusion if resection is > 50 % bilateral facets or complete unilateral facetectomy. Incidental dural tear primarily repaired not changing the clinical outcome.

- o this is different that isthmic spondylolisthesis which is most commonly seen at L5/S1

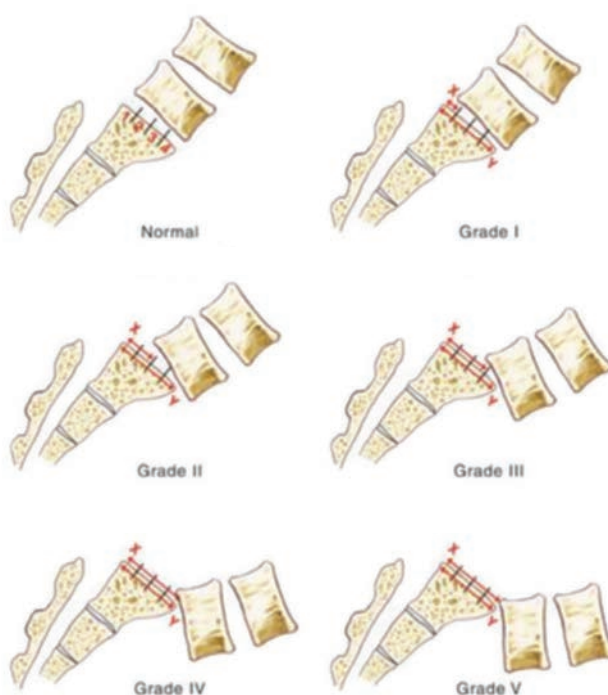
### - Pathoanatomy

- forward subluxation (intersegmental instability) of vertebral body is allowed by
  - o facet joint degeneration
  - o facet joint sagittal orientation
  - o intervertebral disc degeneration
  - o ligamentous laxity (possibly from hormonal changes)
- neurologic symptoms caused by central and lateral recess stenosis



## B. Classification

Myerding Classification	
Grade I	< 25%
Grade II	25 to 50%
Grade III	50 to 75% (Grade III and greater are rare in degenerative spondylolisthesis)
Grade IV	75 to 100%
Grade V	Spondyloptosis



## VI. Degenerative Spondylolisthesis

### A. Overview

A condition characterized by lumbar spondylolisthesis without a defect in the pars

absent of pars defect differentiates from adult isthmic spondylolisthesis

#### - Epidemiology

- prevalence
  - o 5% in men and 9% in woman
- demographics
  - o more common in African Americans, diabetic patients, and women over 40 years of age
  - o 8 times more common in women than men
  - o prevalence increased in women due to increased ligamentous laxity related to hormonal changes
- location
  - o degenerative spondylolisthesis is 5-fold more common at L4/5 than other levels

## C. Presentation

- Symptoms
  - mechanical/back pain
    - most common presenting symptom
    - usually relieved with rest and sitting
  - neurogenic claudication & leg pain
    - second most common symptom
    - defined as buttock and leg pain/discomfort caused by upright walking
    - relieved by sitting
    - not relieved by standing in one place (as is vascular claudication)
    - may be unilateral or bilateral
    - same symptoms found with spinal stenosis
  - cauda equina syndrome (very rare)
- Physical exam
  - L4 nerve root involvement (compressed in foramen with L4/5 DS)
    - weakness to quadriceps
    - best seen with sit to stand exam maneuver
    - weakness to ankle dorsiflexion (cross over with L5)
    - best seen with heel-walk exam maneuver
    - decreased patellar reflex
  - L5 nerve root involvement
    - weakness to ankle dorsiflexion (cross over with L4)
    - best seen with heel-walk exam maneuver
    - weakness to EHL (great toe extension)
    - weakness to gluteus medius (hip abduction)
  - provocative walking test
    - have patient walk prolonged distance until onset of buttock and leg pain
    - have patient stop but remain standing upright
    - if pain resolves this is consistent with vascular claudication
    - have patient sit
    - if pain resolves this is consistent with neurogenic claudication (DS)
  - hamstring tightness
    - commonly found in these patients, and must differentiate this from neurogenic leg pain

## D. Treatment

- Nonoperative
  - physical therapy and NSAIDS
    - indications
    - most patients can be treated nonoperatively
  - modalities include
    - activity restriction
    - NSAIDS
  - epidural steroid injections
    - indications
    - second line of treatment if non-invasive methods fail
- Operative
  - lumbar wide decompression with instrumented fusion
    - indications
      - persistent and incapacitating pain that has failed 6 mos. of non operative management and

- epidural steroid injections
  - progressive motor deficit
  - cauda equina syndrome
- outcomes
  - 79% have satisfactory outcomes
  - improved fusion rates shown with pedicle screws
  - improved outcomes with successful arthrodesis
  - worse outcomes found in smokers

## E. Complications

- Pseudoarthrosis (5-30%)
  - CT scan is more reliable than MRI for identifying failed arthrodesis
- Adjacent segment disease (2-3%)
  - incidence is approximately 2.5% a year
- Surgical site infection (0.1-2%)
  - treat with irrigation and debridement (usually hardware can be retained)
- Dural tear
- Positioning neuropathy
  - LFCN
    - seen with prone positioning due to iliac bolster
  - ulnar nerve or brachial plexopathy
    - from prone positioning with inappropriate position
- Complication rates increase with
  - older age
  - increased intraoperative blood loss
  - longer operative time
  - number of levels fusion

## References:

### Degenerative Disc Disease

1. Lindstrom I, Ohlund C, Eek C, Wallin L, Peterson LE, Fordyce WE (1992) The effect of graded activity on patients with subacute low back pain: a randomized prospective clinical study with an operant-conditioning behavioural approach. *Physical Therapy* 72: 279-293
2. Frost H, Klaber Moffett JA, Bergman JA, Spengler D (1995) Randomised controlled trial for evaluation of fitness programme for patients with chronic low back pain. *Br Med J* 310:152-154
3. Van Tulder M, Koes B, Malmivaara A (2006) Outcome of non-invasive treatment modalities on back pain: an evidence-based review. *Eur Spine J* 15:S64-S81
4. Abenhaim L, Rossignol M, Valat JP, Nordin M, Avouac B, Blotman F, Charlot J, Dreiser RL, Legrand E, Rozenberg S, Vautravers P (2000) The role of activity in the therapeutic management of back pain. Report of the International Paris Task Force on Back Pain. *Spine* 25:1S-33S

### Lumbar Disc Herniation

1. Williams RW (1978) Microlumbar discectomy: a conservative surgical approach to the virgin herniated lumbar disc. *Spine* 3:175-82



2. Atlas SJ, Keller RB, Wu YA, Deyo RA, Singer DE (2005) Long-term outcomes of surgical and non-surgical management of sciatica secondary to a lumbar disc herniation: 10 year results from the Maine Lumbar Spine Study. *Spine* 30:927–935
3. Balague F, Nordin M, Sheikhzadeh A, Echegoyen AC, Brisby H, Hooge- woud HM, Fred- man P (1999)
4. Weber H (1983) Lumbar disc herniation. A controlled, prospective study with ten years of observation. *Spine* 8:131–140
5. Weinstein JN, Lurie JD, Tosteson TD, et al. (2006) Surgical vs nonopera- tive treatment for lumbar disk herniation. The Spine Patient Outcomes Research Trial (SPORT), a randomized trial. *JAMA* 296:2441–2450
6. Weinstein JN, Lurie JD, Tosteson TD, et al. (2006) Surgical vs nonoperative treatment for lumbar disk herniation. The Spine Patient Outcomes Research Trial (SPORT) observational cohort. *JAMA* 296:2451–2459

## Spinal Stenosis

1. Amundsen T, Weber H, Nordal HJ, Magnaes B, Abdelnoor M, Lilleas F (2000) Lumbar spinal stenosis: conservative or surgical management? A prospective 10-year study. *Spine* 25(11):1424–35
2. Grob D, Humke T, Dvorak J (1995) Degenerative lumbar spinal stenosis. Decompression with and without arthrodesis. *J Bone Joint Surg Am* 77:1036–41
3. Herkowitz HN, Kurz LT (1991) Degenerative lumbar spondylolisthesis with spinal stenosis. A prospective study comparing decompression with decompression and inter-transverse process arthrodesis. *J Bone Joint Surg Am* 73:802–8

## Questions

1. What is the risk of recurrent herniation's at the same level in surgically treated patients at 5-year follow-up?
2. What is the most common location for lumbar disc herniation?
3. How are extraforaminal disc herniations ideally approached?
4. A 65-year-old man has low back pain and leg pain with standing. Walking endurance is limited to two blocks due to leg cramping. He has a wide-based, unsteady gait and hyperflexia. Lumbar radiographs reveal a degenerative spondylolisthesis at L4–L5, and an MRI scan shows moderate spinal stenosis at this level. The next step in his care should include:
  - a. lumbar epidural steroid injections.
  - b. lumbar decompression with fusion.
  - c. a lumbar epidurogram.
  - d. interspinous distraction.
  - e. cervical MRI.
5. An incidental dural tear was primarily repaired with a watertight closure during an otherwise uncomplicated laminectomy. After surgery, the patient should be informed that:
  - a. the chance of resolution of the preoperative symptoms will be decreased.
  - b. there is a greater risk of a wound infection.
  - c. the clinical outcome will be unaffected.
  - d. strict bed rest for 2 weeks is recommended.
  - e. a compression dressing must be maintained for 7 days.

## Answers

1. 3–18%
2. Caudal segments are affected more commonly, L5–S1 slightly more frequent than L4–L5. Less frequent in thoracic and high lumbar level
3. Wiltse approach
4. a
5. c

## VII. Spinal Cord Injury

### A. Background

1. The annual incidence of SCI is approximately 40 cases per 1 million people in the United States, or 11,000 new cases per year.
2. 55% of SCIs occur in the cervical spine. The remaining injuries are equally distributed through-out the thoracic, thoracolumbar, and lumbosacral spine.
3. Motor vehicle accidents account for half of reported SCIs. Fall and recreational sport injuries are responsible for most of the remaining SCIs.
4. Neurologically, most patients sustain incomplete tetraplegia (34%), followed by complete paraplegia (25,1%), complete tetraplegia (22,1%) and incomplete paraplegia (17,5%).

### B. Emergency department evaluation

1. Respiratory pattern: SCI above C5 is more likely to require intubation, because of fatigue of the accessory respiratory muscles. Complete tetraplegia is more likely to require intubation than incomplete tetraplegia.
2. Hemodynamic evaluation: neurogenic shock, defined as circulatory collapse resulting from neurologic injury, is caused by an interruption of the sympathetic output to the heart and peripheral vasculature. This collapse gives rise to the bradycardia and loss of vascular and muscle tone below the level of the SCI.

### C. Neurological Examination

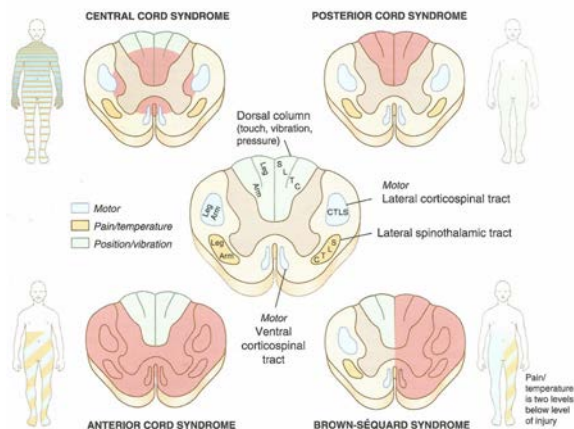
1. The American Spinal Injury Association (ASIA) standards of neurological testing provides a concise and detailed method for evaluating spinal cord and peripheral nerve root function. (Table 1)
2. In traumatic cord injury the main classification distinguishes between paraplegia (impairment or loss of motor and/ or sensory function in the thoracic, lumbar or sacral neural

**Table 1. ASIA Impairment Scale**

ASIA A: sensory and motor complete
ASIA B: sensory incomplete, motor complete
ASIA C: sensory and motor incomplete, motor function below the level of lesion in mean M3
ASIA D: sensory and motor incomplete, motor function below the level of lesion in mean >M3
ASIA E: no relevant sensor/motor deficit, minor functional impairments of reflex-muscle tone changes

segments T2-S5) and tetraplegia (impairment or loss of motor and / or sensory function in the cervical segments C0-T1).

3. A further differentiation is made in regards to the completeness of the lesion as: complete or incomplete. The distinction between complete and incomplete is based on the preservation of any sensory or motor function within the last sacral segments S4-S5.
4. Recognition of patterns of neurological deficits can help determine prognosis: Brown-Séquard carries the best prognosis, Central cord syndrome is the most common, Anterior cord syndrome carries the worst prognosis and Posterior cord syndrome.



## D. Imaging Evaluation

1. Computed tomography (CT) scanning with coronal and sagittal reformat images is useful to further define bony anatomy of the lesion.
2. Magnetic Resonance Imaging (MRI) is used in all cases of neurological compromise or to better visualize soft-tissue anatomy, that is, neural compressive lesions such as disc herniation, epidural hematomas or traumatic ligamentous injuries.
3. Radiological examination includes standard anteroposterior and lateral plain x-ray films of the cervical, thoracic and lumbosacral spine, if the patient conditions allow. Remember that 10%-15% of patients have non-contiguous spinal column fractures.

## E. Pharmacologic intervention

1. Respiratory, cardiac, and hemodynamic monitoring is necessary for SCVI patients. Hypotension (systolic blood pressure < 90mm Hg) should be avoided and a mean arterial blood pressure of 85 to 90 mm Hg should be maintained for the first 7 days.
2. To avoid deep venous thrombosis and pulmonary embolism, prophylactic use of low-molecular-weight heparin, a rotating bed, and pneumatic compression stockings or combination therapy are recommended.
3. Many clinicians believe there is insufficient evidence to support any pharmacologic therapies as a stand of care in the management of acute spinal cord injury. Criticism has recently been directed at the interpretation and conclusions of NASCIS II and III studies.

4. Methylprednisolone was indicated to improve the motor scores in post-traumatic SCI when patients were delivered within 8 hours of injury (NASCIS III).
5. Less than 3 hours after injury, a 30 mg/Kg bolus of methylprednisolone is administered, followed by 5,4 mg/Kg/h for 23 hours.
6. Between 3 to 8 hours after injury, the 30 mg/Kg bolus is followed by 5,4 mg/Kg/h for the next 47 hours.

## F. Timing of Surgery

1. Data for the timing of surgical treatment of spinal cord injury has not been shown conclusively to support either early or late intervention.
2. Proponents of early surgical decompression advocate timely normalization of the intracellular environment and recovery of capillar perfusion by removing external pressure from the spinal cord and establishing spinal stability.
3. There is substantial class 2 and 3 evidence (non prospective, nonrandomized and uncontrolled) that surgical decompression provides better outcomes than late or nonsurgical therapies.

## VIII. Cervical Fractures

### A. Epidemiology

1. Cervical spine injuries account for about one-third of all spine injuries. C2 was the most common level of injury, one – third of which were odontoid fractures. In the subaxial spine, C6 and C7 were the most frequent
2. A neurological injury occurs in about 15% of spine trauma patients.
3. Functionally, the cervical spine is divided into the upper cervical (occiput C0-C1-C2) and the lower (subaxial) cervical spine (C3-C7). The C0-C1-C2 complex is responsible for 50% of all cervical rotations while 80% of all flexion/extension occurs in the lower cervical spine. The C5-C6 level exhibits the largest ROM.

### B. Instability of the cervical spine

1. One of the problems has been the absence of a clear definition based on reliable radiological criteria. Therefore White and Panjabi (Table 2) defined clinical instability of the spine as: The loss of the ability of the spine under physiological loads to maintain its pattern of displacement so that there is no initial or additional neurological deficit, no major deformity and no incapacitating pain.

Table 2. Criteria for C0-C1-C2 instability (According to White and Panjabi)

>8° axial rotation C0-C1 to one side
>1mm translation of basis on to dens top (normal 4-5 mm) on flexion/extension
>7mm bilateral overhang C1-C2
>45° axial rotation (C1-C2) to one side
>4mm C1-C2 translation measurement
<13mm posterior body C2 – posterior ring C1 avulsion fracture of transverse ligament

## C. Initial Treatment

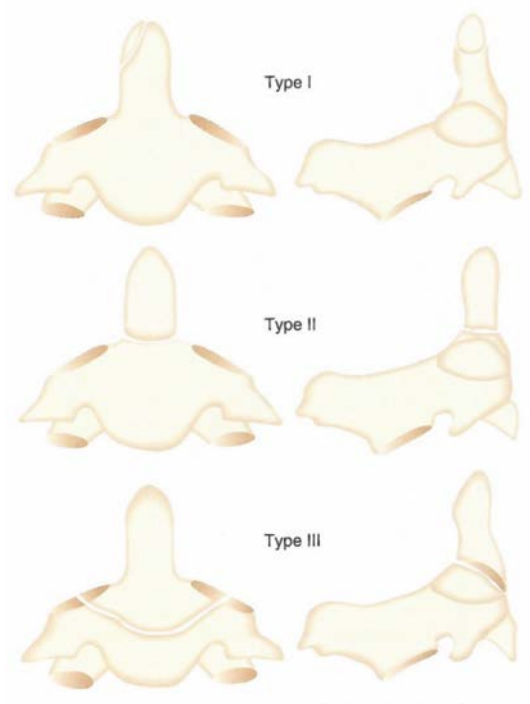
1. Early recognition of injury begins in the field. A collar is placed and a spine board is applied.
2. Neurological examination should include the assessment of cranial nerves, motor and sensory function, reflexes, and rectal tone.
3. The level of neurological function is graded according to the ASIA classification and reflected in clinical history.
4. Avoid the "chin lift" method of the securing airway, it may decrease space available for spinal cord.

## D. Imaging Studies

1. Symptomatic patients require radiographic studies to rule out the presence of a traumatic cervical spine injury before the cervical spine is cleared. A cervical spine injury is found in 2-6% of all symptomatic patients.
2. Radiography remains the imaging modality of first choice. The lateral view should extend from occiput to T1. Do not miss injuries at the cervicocranial and the cervicotorathic junctions.
3. CT is the first choice for unconscious patients. Most large trauma centers now perform multislice CT scans for the assessment of polytraumatized patients. The reason why CT has surpassed radiography include the ease of performance, speed of study, and most importantly, the greater ability of CT to detect fractures other than radiography.
4. MRI should be performed in addition to CT for specific diagnostic assessments.
5. Magnetic resonance is the imaging study of choice to exclude discoligamentous injuries. And it is the modality of choice for evaluation of patients with neurological signs or symptoms to assess soft-tissue injury of the cord, disc and ligaments.

## E. Upper Cervical Trauma

1. Atlas Fractures (C1):
  - 7% of cervical spine fractures
  - Neurological injury is rare because of the wide spinal canal at that level, but cranial nerve injuries are frequently observed.
  - Classic Jefferson (burst) fractures are bilateral fractures of the anterior and posterior arches of C1 resulting from axial load.
  - Long-term stability depends on the mechanism and healing of the transverse ligament.
  - Treatment: all stable fractures without transvers ligament injury can be treated non surgically, with 6 to 12 weeks of external immobilization
  - Jefferson fractures with an intact transverse ligament are considered stable fractures and can also be treated with external immobilization with halo.
  - On unstable Jefferson fractures surgical options may be considered.
2. Axis fractures (C2):
  - Odontoid fractures are the most common type of axis fractures
  - Type 1 fractures are avulsion fractures of the tip of the odontoid
  - Type 2 fractures occur through the waist of the odontoid process.
  - Type 3 fractures extend into the C2 vertebral body.
  - Treatment of Type 1 and Type 3, typically stable fracture, should be treated with a cervical orthotics for 6 to 12 weeks



- Treatment of type 2 fractures, correlates with increased risk of non-union if the initial translation is greater than 6 mm of failed reduction, age greater than 50 and angulation greater than 10°.
- These type 2 fractures should be considered for early C1-C2 fusion in elderly patients.
- In young people type 2 fractures not displaced could be treated with halo vest immobilization. For fractures in which reduction cannot be achieved or maintained, surgical treatment should be considered. Anterior odontoid screw placement is an option for minimally comminuted fractures or C1-C2 posterior stabilization and fusion.
- 3. Traumatic Spondylolisthesis of the Axis:
  - This injury is characterized by bilateral fractures of the pars interarticularis (Hangman's fracture)
  - Most patients can be treated successfully with external immobilization in a halo vest or cervical orthosis for a 6 to 12 weeks.
  - Surgical indications include fractures with severe angulation or with disruption C2-C3 disk and/or facet dislocation. Surgical options include C2-C3 interbody fusion, posterior C1-C3 fusion or bilateral C2 pars interarticularis screws.

## F. Subaxial Cervical Trauma

Apply the Allen and Ferguson classification of subaxial cervical trauma (Allen et al. 1982) for fractures and dislocations of cervical spine C3 through C7.

The classification system is based upon the mechanism of injury; there are six categories divided into stages. It provides probable deficiencies of bony and ligamentous elements.

The three most commonly observed categories are compressive flexion, distractive flexion and compression extension.

1. Compression-flexion:
  - failure of anterior column compression and posterior column distraction.
  - are caused by axial loading in flexion with failure of the

anterior half of the body without disruption of the posterior body cortex and minimal risk of neurologic injury.

- Treatment: stable undisplaced compression-flexion fractures can be treated conservatively with external immobilization for 6 to 12 weeks with a rigid collar. Kyphosis deformity > 15° should be considered for operative stabilization with anterior cervical fusion.
- 2. Vertical compression injuries:
  - are caused by severe compressive load. These fractures, "burst fractures", are commonly associated with complete or incomplete SCI from retropulsion of fracture fragments into the spinal canal.
  - Treatment: patients with neurological deficit are better treated by anterior decompression and reconstruction with strut grafts and plating it. If there is a significant compromise of the spinal canal, it can usually be reduced with traction.
- 3. Distraction flexion:
  - four stages (Allen et al 1982):
  - stage I- facet subluxation in flexion and widening of the interspinous distance. < 25% subluxation of facets
  - stage II- unilateral facet dislocations
  - stage III- bilateral facet dislocation with < 50% anterior vertebral body translation.
  - stage IV- bilateral facet dislocation with 100% anterior translation of the vertebral body.
  - Treatment: Rotational injuries are considered very unstable and are therefore usually treated operatively. Awake and alert patient can safely undergo closed reduction with progressive traction. Development of new or worsening neurologic deficits is an indication to cease closed reduction.
  - Patients who have undergone successful awake reduction should undergo an MRI to verify that no disc material or hematoma remains.
  - A combined antero/posterior technique provides the best outcome although in selected cases (e.g. unilateral dislocation) either a single anterior or posterior approach may be sufficient.

## G. Complications

- Overall, 5% of patients with compressive injuries of the subaxial cervical spine had persistent instability after non-operative treatment.
- Kyphosis or subluxation develops in about 10% of patients who are treated with posterior fusion.
- Operative complications are more common in patients treated with posterior fusion procedures (37%), compared with anterior fusion procedures (9%).
- Graft displacement is the most common complication found in patients treated with anterior cervical fusion without anterior fixation (9%).

## IX. Thoracolumbar Fractures

### A. Epidemiology

1. The thoracolumbar spine is the most common site of spinal injuries.
2. Usually they are the result of a significant force impact, such as a motor vehicle accident or fall.

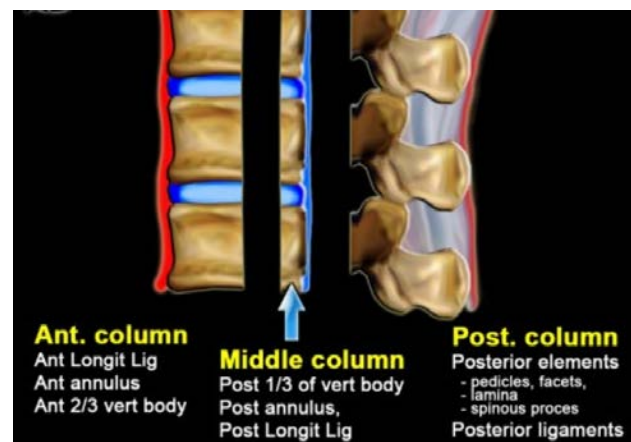
3. Most injuries (52%) occur between T11 and L1 followed by L1 through L5 (32%) and T1 through T10 (16%).
4. The increased incidence of fractures of the thoracolumbar junction is the result of its location at the biomechanical transition zone between the rigid thoracic rib cage and the more flexible lumbar spine. Contiguous and non-contiguous spine injuries are present in 6% to 15% of patients.
5. Associated injuries include intra-abdominal bleeding from liver and splenic injuries, vessel disruption, and pulmonary injuries (20% of patients).
6. In thoracolumbar fractures neurological deficiencies were reported between 22% and 35%. In the thoracolumbar transition (T10-L2) neurological deficiencies occur in 22-51% depending of the fracture type.

### B. Radiologic Evaluation

- Plain X-ray film is the initial screening modality with computed tomography (CT) scanning or magnetic resonance imaging (MRI) used as an adjunct, depending upon whether the surgeon needs to further evaluate bony or soft-tissue anatomy.

### C. Classification Methods

1. Denis (1983) chose to divide the anterior column into two, making three columns in total, the middle of which was felt to be the biomechanical key, which means, disruption here was thought to render the fracture unstable. Major injuries include compression fractures, burst fractures, flexion-distraction injuries and fracture dislocations.



2. Magerl et al (1993) introduced a complex hierarchical classification system based on pathomorphologic criteria, of increasing injury and instability. This system divides thoracolumbar spinal fractures into three general groups. Type A compression injuries, Type B distraction injuries and Type C torsional injuries. The complexity of the system certainly enables researchers to accurately compare fracture types in follow-up.
3. Vaccaro et al (2005) have proposed recently, a novel new Thoracolumbar Injury Classification and Severity Score (TLISS) based in three parameters: the morphology of the fractured vertebrae, the neurologic status and the integrity of the importance PLC, now visible on MRI.



Points	
Fracture Mechanism	
Compression fracture	1
Burst fracture	1
Rotational fracture	3
Splitting	4
Neurological Involvement	
None	0
Nerve root	2
Medulla spinalis, conus medullaris, incomplete	3
Medulla spinalis, conus medullaris, complete	2
Cauda equina	3
Posterior Ligamentous Complex	
Intact	0
Possibly injured	2
Injured	3

## D. Non-operative treatment

1. Most thoracolumbar spine fractures are stable and do not require surgery.
2. Non operative treatment with a well-molded brace or hyperextension cast has been shown in numerous studies to be very effective.
3. Simple compression or stable burst fracture without neurologic complications can typically be treated with off-the-shelf braces or well-molded orthoses that permit early ambulation.
4. Upright radiographs of the patient, in brace or in cast, should be obtained before discharge.
5. Significant increases in the fracture angle ( $>10^\circ$ ) or significant increases in pain have been suggested as an indication for operative treatment.

## E. Operative treatment

1. Operative treatment does offer a few advantages: immediate mobilization, earlier rehabilitation and may restore sagittal alignment more reliably in certain situations.
2. The benefits of surgical treatment must be carefully weighed against the potential morbidity associated with the operation.
3. Compression fractures: Coronal split type fractures frequently fail to unite and may be a source of painful non-union. Operative treatment is, more commonly considered, especially in the lower lumbar spine.
4. Burst fractures: instability should be considered whenever large degrees of axial compression ( $>50\%$ ) or more than  $25^\circ$  of angulation.
  - The decision of surgery depends on the location of the fracture, the degree of vertebral destruction, any neurologic involvement, the degree of kyphosis, and the stability of the posterior column structures.
  - It has been demonstrated in numerous reports that retropulsed bony fragments do resorb and the canal remodels up to 50% of the occlusion over time.
  - Posterior pedicle screw fixation has been shown to be efficient, reliable and safe for the reduction and stabilization of most traumatic fractures.
  - The proportion of vertebral body damage, spread of the fracture fragments, and degree of kyphosis are tabulated to predict failure, that is, suggesting the need for additional anterior column support/surgery. In this situation anterior

reconstruction with structural graft or plate instrumentation and short-segment posterior pedicle screw fixation has been shown to be effective.

5. Flexion-distraction injuries:
  - Because the injury in these fractures is mainly linked to the posterior osteoligamentous complex, it is best treated with a posterior compression type construct and fusion to restore the normal sagittal contour.
  - Most specialists advise postural reduction by positioning, gentle compression and lordosing rod.
6. Fractures-dislocation:
  - Fracture-dislocations are often the result of very high-energy trauma and are the fracture type most often associated with neurological damage and associated skeletal injuries.
  - Because of the severe nature of the bony disruption, realignment and fixation are best accomplished through posterior positioning, reduction, multilevel instrumentation, and fusion.

## F. Complications

The reported complications rate in the literature varies largely and ranges from 3,6% to 10%. Postoperative neurological complications range from 0,1% to 0,7%. Only honest and accurate assessment of complications will lead to scientific and clinical progress.

## References:

### Book chapters

1. Heinzelmann M, Wanner GA. Thoracolumbar Spinal Injuries. In: Boss N, Aebi M (2008) *Spinal Disorders*. Springer – Verlag. Berlin Heidelberg.
2. White AA, 3rd, Panjabi MM: *Practical biomechanics of spine trauma*. In: White AA, 3rd, Panjabi MM (eds) *Clinical Biomechanics of the spine*. JB Lippincot, Philadelphia 1990, pp169–275

### Journals

1. Allen BL, Ferguson RL, Lehmen TR, O'Brien RP: A mechanistic classification of closed, indirect fractures and dislocation of the lower cervical spine. *Spine* 1982; 7:1–27.
2. Anderson PA, D'Alonzo RT. Fractures of the odontoid process of the axis. *J Bone J Surg* 1974; 56A(8):1663–1674
3. Levine AM, Edwards CC. Fractures of the atlas. *J Bone J Surg* 1991; 73A:680–691.
4. Denis F. The three column spine and its significance in the classification of acute thoracolumbar spine injuries. *Spine* 1983; 8:817–31.
5. Effendi B, Roy D, Cornish B et al. Fractures of the ring of the axis – A classification based on the analysis of 131 cases. *J Bone J Surg* 1981; 63B:3
6. Harris MB, Kronlage SC, Carboni PA, et al.: Evaluation of the cervical spine in the polytrauma patient. *Spine* 2000; 25:2884–2891.
7. Magerl F, Aebi M, Gertzbein SD et al. A comprehensive classification of thoracic and lumbar injuries. *Eur Spine J* 1994; 3:184–201.
8. Vaccaro AR, Lehman RA, Hulbert RJ, et al. A new classification of thoracolumbar injuries: the importance of injury morphology, the integrity of the posterior ligamentous complex and neurologic status. *Spine* 2005; 18:209–15.

9. Wood K, Buttermann G, Mehbod A, Garvey T, Jhanjee R, Sechriest V: Operative compared with nonoperative treatment of a thoracolumbar burst fracture without neurological deficit. *J Bone Joint Surg Am* 2003;85-A:773-781.

---

### Questions

1. A 44-year-old farmer involved in a rollover accident on his tractor sustained a L1 burst fracture with 20% loss of vertebral body height, 30% canal compromise, and 15° of kyphosis. He remains neurologically intact. The preferred initial course of action should consist of
  - a. posterior spinal fusion with instrumentation
  - b. a thoracolumbarsacral orthosis (TLSO) extension brace and early mobilization.
  - c. Bed rest for 6 weeks followed by immobilization in a cast
  - d. Anterior L1 corpectomy and fusion with instrumentation
  - e. Anterior corpectomy followed by posterior fusion with instrumentation
2. What is the prognosis for ambulation, from best to worst, for patients with an incomplete spinal cord injury?  
CCS = Central Cord Syndrome  
ACS = Anterior Cord Syndrome  
BSS = Brown-Sequard Syndrome
  - a. CCS, ACS, BSS
  - b. CCS, BSS, ACS.
  - c. BSS, ACS, CCS
  - d. BSS, CCS, ACS
  - e. ACS, CCS, BSS
3. Which is the most common site of spinal fractures?
4. Which mark be fitting with a incomplete sensory deficit and complete motor deficit in ASIA Impairment Scale?
5. Which classification of thoracolumbar fractures MRI is used to identify PCL injury Posterior Ligament Complex?

---

### Answers

1. b
2. d
3. Thoracolumbar spine
4. ASIA B
5. TLICS Thoracolumbar injury classification and severity score



*Prof. Enrique Guerao, MD, PhD, FRCS*

Hospital Universitario Costa del Sol  
University of Malaga – Malaga, Spain

eguerado@hcs.es

## Fractures: Pelvic Ring & Acetabular Fractures

### 1. Pelvic Ring

#### 1.1. Introduction

Over the past decade, the literature on pelvic and acetabular fractures has grown to outnumber all that has been previously published. This result of the bibliographic searches is paradoxical given that conceptually no new paradigm has been published on the resuscitation of severe trauma patients, diagnosis or treatment of pelvic fractures or, since Letournel, in relation to acetabular fractures. The novelties focus on fractures occurring in the elderly or the form of administration of osteosynthesis thanks to the advances offered by imaging and computer technologies, such as intraoperative CT-scan, less invasive surgery, or navigation. The emergency of treating bleeding in pelvic fractures with secondary reconstructive surgery and anatomical reduction in acetabular fractures remain unchanged.

Nonetheless, new knowledge has provided great utility mainly in fractures after low-energy trauma. In its well-known that pelvic fractures are usually due to high energy trauma. But they also can occur in elderly patients as the result of a simple indoor fall. In both cases pelvic fracture can provoke major bleeding. In case of high energy trauma in adults because of concurrent injuries a life threatening bleeding can occur whereas in elderly patients bleeding can be associated to the own trauma but also to medication, mainly to anticoagulant treatments.

While high-energy trauma cases always receive critical consideration, fractures in the elderly after low-energy trauma do not receive the attention they require. The TARN report is eloquent in finding that head injuries in the elderly, as well as pelvis fractures, are not usually given the required prompt and accurate diagnosis and treatment, nor are more senior doctors who attend to them <sup>(1)</sup>.

The keystones of the anatomical stability of the pelvis are bone strength and ligaments fixating the pelvic ring. This ring is constituted by the two iliac bones articulated posteriorly by the sacrum, and anteriorly by the symphysis pubis. The fragility of the pelvic bones facilitates the fracture, even more so if the ligaments do not show this fragility. Conversely, when the bones are strong, the ligaments can tear, causing major instability in the pelvic ring. In these latter cases, the combination of bone fracture and ligament tears, are the most common pathological patterns in high-energy trauma. Strong iliolumbar, lumbosacral, and iliosacral ligaments mechanically stabilize the pelvic ring. The lumbosacral disc, although providing shock-absorbing effects, does not have lumbosacral tethering, whereas the facet joints of L5 and S1 also provide some stability, especially rotational. The iliosacral ligaments can be divided into two main groups: short ligaments (anterior and posterior sacroiliac) and

long ligaments (sacrospinous and sacrotuberous).

Vascular plexuses run posterior to the symphysis pubis and anterior to the sacrum. Whenever an anteroposterior or vertical traumatism tears these plexuses, major bleeding can occur, even more important if –very rarely– the iliac vessels are damaged <sup>(2)</sup>. Some others viscerae can be injured such as the bladder, the bowel, the vagina or the uterus, masking a real open fracture. Neurological damage of the lumbosacral or sacral plexuses can complete the possibilities of complementary injuries in pelvis traumatism.

#### 1.2. Diagnosis

As in any severe trauma, the Advance Trauma Life Support (ATLS) should be applied, which should be rehearsed frequently, especially when new members join the team <sup>(3)</sup>.

The essential acute problem of severe pelvis trauma is major bleeding. Whenever a patient sustains a high energy traumatism, a prompt diagnosis must be made to know hemorrhage severity, being the pelvis one of the most serious bleeding sites. For that purpose, provided the patient is haemodynamically stable and before becomes unstable, a rapid contrast CT-scan must be the choice before performing any therapeutic action, apart from colloid perfusion <sup>(2,4)</sup>; otherwise, should they be unstable, an EchoFast can be very helpful just before a potential surgical approach. Contrast CT-scan is also very useful for diagnosing some other source of bleeding cranial, thoracic or abdominal.

Throughout this process, it must be taken into account that the spine must be immobilized in order to avoid spinal cord injury that would cause bradycardia, hypotension and, of course, paralysis, adding severity to the hypovolemic clinical situation due to potential major bleeding of the pelvic bones (Fig. 1). Concurrent lower limb injuries, mainly femur fractures, are not uncommon and also aggravate bleeding and can cause fat embolism. For spinal fractures, the same CT scan helps avoid missing this important diagnosis, and fractures of the femur are also easily seen by simple clinical inspection. Clinical tests –blood pressure and heart rate– and laboratory tests –at least hemoglobin, hematocrit, cell blood count, lactate levels and, if possible, thromboelastography– should complete the diagnostic battery <sup>(2,4)</sup>.

During the diagnosis process an augmentation of the pelvis ring diameter must be recognized and, if present, should immediately be closed by a pelvis binder, before further diagnosis test are carried out. If hemodynamic stabilization is not achieved once the ring is closed, prompt extraperitoneal packing with subsequent embolization can be the choice. Therefore diagnosis of pelvis trauma is a combination of concurrent diagnosis and treatment decisions aimed to avoid general

bleeding and central nervous system injury. After control of bleeding, it is important to make a meticulous exploration to rule out an open pelvic fracture, either by skin lesion or a hollow viscera injury that comes in contact with the fracture. An open fracture that is missed can provoke a severe infection in an already immunocompromised patient.

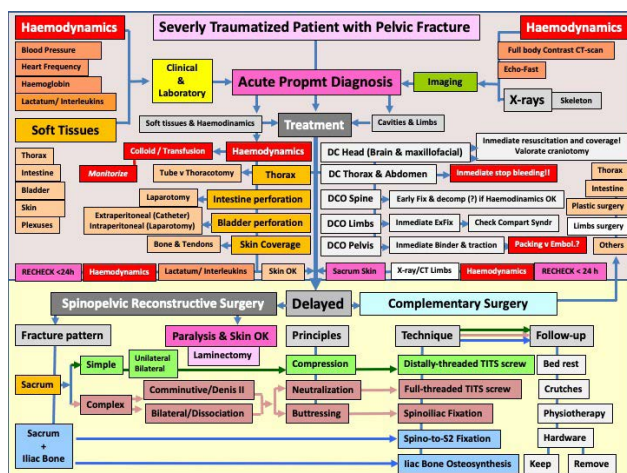


Figure 1: Acute diagnosis process for pelvic fractures. Based on: Guerado E, Cervan A, Cano JR, Giannoudis PV. Spinopelvic Injuries. Facts and Controversies. Injuries 2018;49:449-56.

In the elderly, "minor" fractures of the iliopectic or ischiopubic rami, diagnosed by simple pelvic radiographs, should also be completed with a pelvis CT-scan since, due to osteoporosis, a sacral fracture can be frequently missed. Treatments with anticoagulant drugs can cause apparently simple fractures to bleed significantly. Therefore, any elderly patient with a simple and non-displaced sacral fracture on anticoagulants should be admitted to the hospital for observation for 1-2 days. For that meticulous anamnesis is essential.

## 1.3. Classification

Classification of pelvis fractures are based on the prompt CT-scan images obtained through the diagnosis process. Delaying time on further x-ray studies may be fatal, and nowadays former outlet and inlet x-ray projections can be avoided once a proper CT-scan has been duly obtained during the emergency process. These images allow the mechanism of fracture production to be analyzed and, thanks to this analysis, to suspect the severity of the bleeding.

For this purpose, Young and Burgess classification<sup>(5,6)</sup> provides excellent information, according to three possible fracture mechanisms: 1. Anteroposterior compression (APC): causes opening of the pelvic ring due to injury to the anterior sacroiliac ligaments with preservation of the posterior ones and severe bleeding due to tearing of the arteriovenous plexuses. 2. Lateral compression (LC) with the opposite effect to the previous one: decrease in pelvic diameter and less bleeding. There is injury to the posterior sacroiliac ligaments with preservation of the anterior ones or iliac fracture with internal rotation of the anterior part of the fractured hemipelvis and even ipsilateral overhang of the sacrum. Yet, in cases where internal rotation of the hemipelvis is more severe, it can cause external rotation of the contralateral hemipelvis and then more severe bleeding. 3. Vertical shear mechanism that

causes injury to the anterior and posterior part of the pelvic ring, usually causing more bleeding than the other types. The basis of the bleeding, in any fracture type is in the magnitude of the displacement in external rotation and in the vertical direction.

Tile-AO/OTA classification (Fig. 2) is similar to that by Young and Burgess: (A) Full stable fractures, (B) rotationally unstable/vertically stable, or (C) rotationally and vertically unstable<sup>(7)</sup>. A-type, full stable fractures are characterized by no remarkable alterations of the pelvic brim with usually lesser bleeding, provided the patient is not on anticoagulant medicaments, as said above. B-type, rotationally unstable/vertically stable fractures may be due to an anterior traumatism, opening apart one of the iliac bones (the anterior sacroiliac ligaments tears whereas the posterior ones remain intact – "open book" –) together with significant bleeding (B1-type) or by a lateral compression (B2-type) (the posterior sacroiliac ligaments tears whereas the anterior ones remain intact) with usually lesser bleeding. These B-type patterns can be either unilateral as described above, or bilateral (B3-type), with even more bleeding in case of bilateral open book combination. C-type lesions combine a lesion of the anterior part of the ring together with either a transiliac fracture, a through the sacroiliac joint full ligaments disruption, or a trans-sacral fracture. Since iliac as well as sacrum bone are well vascularized, in case of fracture, bleeding

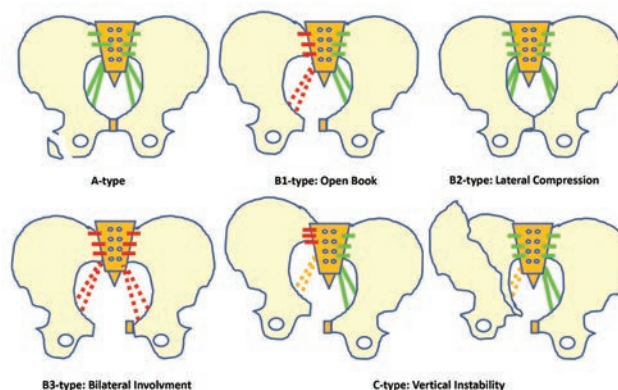


Figure 2: AO/OTA Classification Of Pelvic Fractures

can increase.

Also bilateral fractures through the sacrum will usually form part of a spinopelvic injury: a separation between the lumbar spine together with the proximal and central part of the sacrum from the rest of the pelvis bones.

## 1.4. Treatment

### 1.4.1. Acute treatment

Early treatment of pelvic fractures must be aimed to control bleeding, usually within a "damage control orthopaedic" (DCO)<sup>(2,4,8,9)</sup> rather than an "early appropriate care" (EAC)<sup>(10)</sup> concept. Whatever the fracture exists, closing the ring until reaching its normal diameter is commonly a very effective maneuver. If this cannot control hemorrhage, extraperitoneal packing should be performed with diligence. Angiography with embolization can complement these surgical treatments, but major vascular lesion needs open repair. Pelvic binders are very useful for ring closure, and time saving in



relation to external fixation. In case of anterior and posterior ring lesions (C-type fractures) binder or suprapubic external fixation may be combined with a posterior C-clamp –it can be used only in case of pure sacroiliac dislocation or sacral fracture out of the foramen–, or if at all possible, early transiliotranssacral screwing. In any case, for the application of packing or any other abdominal surgery the pelvic ring should be closed and mechanically stable. Nowadays, provided the patient is in good condition, percutaneous screws can be used for the treatment of sacral fractures, iliosacral dislocation or anterior column fractures, in the acute setting, and as definitive osteosynthesis.

Open fractures need special care. Sphincter lesion or bowel tear require colostomy, and either urine catheter in case of extraperitoneal bladder injury or open reparation if the lesion is intraperitoneal, must be performed as an emergency provided the haemodinamia is favorable. Bone should be covered as early as possible by plastic surgery methods.

## 1.4.2. Elective treatment

In order to allow normal posturing for standing, sitting and walking, reconstructive surgery must be undertaken with the objective of reaching a square pelvis without vertical or rotational displacement. Usually, elective treatment is accomplished once the patient is haemodynamically stable, the coagulation markers and blood lactatum levels show normal values, and the skin is in good condition. With the introduction of the early appropriate care (EAC) concept apart from the skin situation, only 3 parameters have to be taken into account: lactate level (up to 4 mmol / L is allowed), pH greater than 7.25 and base excess greater than 5.5 mmol / L. By complying with these requirements, the patient can be considered fit to be treated for all his/her fractures <sup>(10)</sup>. EAC is criticized because, in opposition to DCO <sup>(8,9)</sup>, it does not take into account the risks of the lethal triad (coagulopathy, hypothermia and acidosis), minimizes thoracic injuries or massive transfusion <sup>(9)</sup>.

The majority of A-type fractures can be conservatively treated, unless a bone fragment protrudes either under the skin or under a viscera.

B-type fractures are easily treated by either closing (B1) or opening (B2) the ring to its normal circumference. The indemnity of posterior (in case of B1-type instability) or anterior (in case of B2-type instability) sacroiliac ligaments makes the reduction very easy by a simple rotation maneuver, followed by stabilization by a plate. Pure B1-type fractures need only anterior osteosynthesis, whereas combinations with partial rupture of posterior ligaments also require posterior iliosacral screwing. B2-type fractures have usually more simple patterns, suitable for simple anterior symphysis pubis plating. B3-type fractures having an open book component are better managed by anterior symphysis pubis plating together with iliosacral screwing. Whether one or two plate should be inserted is not clear, although it appears advisable inserting two plates in more complex fracture patterns.

C-type fractures require more complex surgery. Although there is no rule for reduction and osteosynthesis, usually proximal correction facilitates reduction of the anterior column fracture or of a concomitant acetabular fracture. The combination of percutaneous screws with or without plates is nowadays very common and, in any case, anatomical reduction must be attempted. Fractures through the sacrum are different depending on whether they form part of a spinopelvic lesion or not. Although whenever the sacrum is fractured there is a dissociation of the extremity on the side of the fracture in relation to the axial skeleton, the complexity of the fracture pattern

determines the severity.

## 1.4.3. Spinopelvic Injuries

Spinopelvic injuries result from a severe traumatism onto the sacrum and are characterized by biomechanical instability between the spine and the pelvis <sup>(11)</sup>. Prompt diagnosis and treatment of the general trauma are of overwhelming importance (Fig. 1) followed by a mechanical stabilization once the patient is medically stable.

Along the years, classifications have progressed from pure morphological concepts to more functional stability conception by considering lumbo-sacrum-iliac bones alignment as a very important issue. Therefore consideration of anterior and sagittal alignment of the lumbar spine, of the sacrum and of both iliac bones is essential; otherwise secondary displacement, non-union, malunion and subsequent lifetime pain and disability may be the outcome. The x-ray based classification by Denis correlates the risk of neurological root damage and the site of the fracture tract, in relation to sacral foramen <sup>(12)</sup>, complemented by the use of letters which resemble the lines of transverse and sagittal fractures, such as "H", "U", "T" and "Y" <sup>(13)</sup>. However it does not take into account that fractures are multiplanar and also does not consider as a uniform biomechanical unit the spine, sacrum, and iliac bones segments. Roy-Camille classification, modified by Strange-Vognsen and Lebech which evaluates the relationship between the proximal and the distal sacral fragments but does not deal with the level at which this transverse fracture occurs, lacks in the consideration of the value of this on the lumbopelvic stability <sup>(14)</sup>. Isler's is the first classification highlighting biomechanical stability of the spinopelvic segment; according to it, fractures exiting medial to the L5-S1 facet (type III) are associated with significant instability, considering bilateral type III fracture as spinopelvic dissociation since spondylopelvic stability depends on the posterior lumbosacral ligamentous structures, as well as on the integrity L5-S1 facet joints, and on the level of transverse fracture <sup>(15)</sup>. The Lumbosacral Injury Classification System (LSICS) takes into account spinal canal compromise and neurological status <sup>(16)</sup>. But all these classifications lack in the correlation between diagnosis and treatment.

## 1.4.4 Principles of Osteosynthesis for Spinopelvic Injuries

Understanding the biomechanics of fracture patterns and osteosynthesis is essential for obtaining a good result <sup>(17,18)</sup>. Transilio-transsacral screws can be indicated in case of simple sacral fractures patterns with its tracts out of the foramen.

Nevertheless, in case of more complex fracture patterns <sup>(19,20)</sup> and since compression is absorbed by bone after a few weeks, more robust neutralization of shearing and rotating forces become necessary: triangular osteosynthesis (TO) is the choice. TO consists of transiliac-transsacral screwing combined with spinopelvic fixation; better purchasing pedicular screws in more than one lumbar level, as in case of unique proximal L5 fixation, shearing and rotating forces can loosen the screw <sup>(17,18)</sup>.

Connection between this bilateral construct would palliate this side-effect; nonetheless the convenience of adding connectors to the indispensable rods can leave dead spaces which can fill of blood and provoke a subsequent infection, as well as in case of bilateral connection with a crosslink which prevents the muscles from to applying itself onto the bone lamina, leaving also dead spaces <sup>(17,18)</sup>.

## 1.4.5 Controversies

Nowadays there is a consensus about the better results obtained by surgical treatment over the conservative one. However some controversies exist.

There are two possibilities for surgical access <sup>(19,20)</sup>: a less invasive approach or a full conventional spinal midline skin incision together with a bilateral incision onto, or just below, the posterosuperior iliac spine (PSIS). Surgeon's experience, fracture complexity, and skin situation are the three main variables for the choice. Also traction is controverted; we always use intraoperative traction applied by a spreader forceps as it can be more effectively applied, quantified and making possible multidirectional maneuvers; more than traction applied from the femoral condyles <sup>(17,18)</sup>.

Laminectomy appears to be advisable in case of cauda equinus compression symptoms and signs; otherwise although bone fragments occupy the sacral canal, a laminectomy is useless. Nonetheless even in case of cauda equinus injury, when a Morel Lavallée hematoma or a skin laceration is present, decision should be carefully taken as a skin uncovered laminectomy may result. Also in many instances just kyphosis correction may be the choice although its results might be sensibly inferior.

The base of a simple but robust construct is screw purchase into pedicles and the iliac screws can be positioned in a subcrestal area, minimizing that problem of skin sore. Nevertheless fifty to sixty millimeters long screws for the iliac pedicle can be enough in a strong healthy bone, and an experienced surgeon can introduce them without the need of radiation. Weight bearing release in walking patients might be more a doctor's sensation than a real therapeutic indication followed by patient compliance; trusting the operation outcome upon weight bearing release is not advisable as stability depends indeed on the robustness of the construct.

We do not fuse either the sacroiliac joint or the lumbosacral hinge and therefore it make sense the recommendation of removing the instrumentation several months post-implantation. Movement restriction is also an important issue as although it is more a sensation than a real biomechanical limitation, it may be felt by patients to be very incapacitating. The majority of flexion and extension movements of the trunk are made thanks to the hip joints, not to the lumbar spine, the lumbosacral hinge or the sacroiliac joint. Therefore although movement sensation is more located in the lumbar spine than more distally, gains in movement after instrumentation removal are minimal. Readmitting patients for implants removal means a new obstacle to their reincorporation into work and personal life, after a hard process of treatment and rehabilitation. Therefore the convenience of this new surgery should be discussed with the patient before making a decision. Only in case of hardware breakage or protrusion onto the skin, the patients should be recommended to undergo a new operation, otherwise rarely they desire it.

Spinopelvic fixation looks the gold standard for spondylopelvic instability, however the number of patients in the literature is still low, and studies based on large data are needed.

## 1.4.6 Treatment in elderly patients

Fractures in the elderly are not usually displaced, in this case, they should be treated conservatively. In case of displacement, the same principles should be applied as in younger patients, although the

general condition and the possibilities of robust osteosynthesis should be assessed. The application of cement to reinforce the iliosacral screws purchase does not guarantee the secondary displacement of the osteosynthesis.

## 2. Acetabular Fractures

### 2.1. Anatomy

With the aim of studying the fractures of the acetabulum, Letournel divided the acetabulum into two columns: the anterior column, including the anterior part of the iliac bone - anterior part of the iliac crest, the anterosuperior and anteroinferior iliac spine, and the anterior acetabular wall-; and the posterior column, having the greater sciatic notch as the ground of the fossa iliaca interna, the posterior wall, the spina sciatica, the lesser sciatic notch, and the ischium. Within the acetabular cavity is the acetabular roof (tectum), as the so-called transverse fracture can be divided into transtectal, yuxtatectal and infratectal, as we will see below.

### 2.2. Diagnosis

Acetabular fractures do not usually represent an emergency as pelvis fractures do. Therefore time is not an issue when studying the nature of fracture patterns. Three x-ray projections are standardized for an acetabular fracture (Figs. 3-5): 1. Anteroposterior: gives information about the pelvis shape, and asymmetries between both sides, being the iliopectineal lines the representation of the anterior columns and the ilioischial lines the representation of the posterior columns (Fig. 3). 2. Obturator projection (with the patient 45° tilted oblique onto the contralateral side): allows the view of the anterior column plus the posterior wall (Fig. 4). 3. Iliac or alar projection (with the patient 45° tilted oblique onto the ipsilateral side): allows the view of the posterior column plus the anterior wall (Fig. 5).

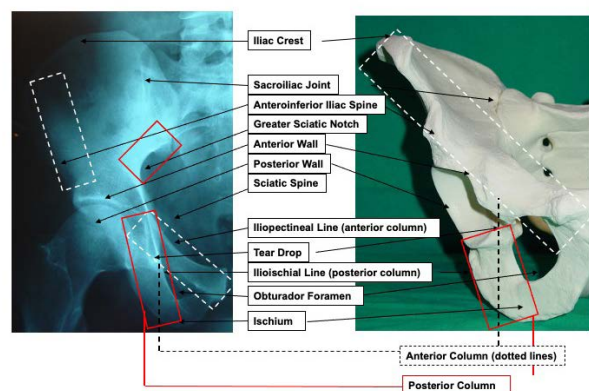


Figure 3: AP x-ray projection of pelvis

This study must be completed with a CT-scan with planar coronal, sagittal, and axial cuts, together with a 3D reconstruction. Small fragments can be better seen in planar cuts whereas 3D reconstruction is a good help for overall pelvis shape evaluation and approach decision.

### 2.3. Classification

The worldwide most used classification is that described by Judet

and Letournel<sup>(21)</sup> (Figure 6). Those fractures of the anterior wall, the anterior column, the posterior wall, the posterior column,

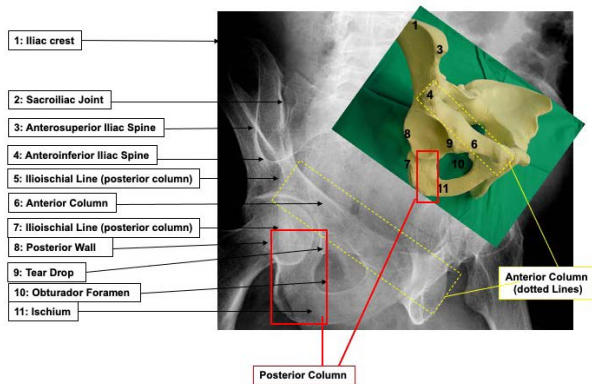


Figure 4: Obturator x-ray projection

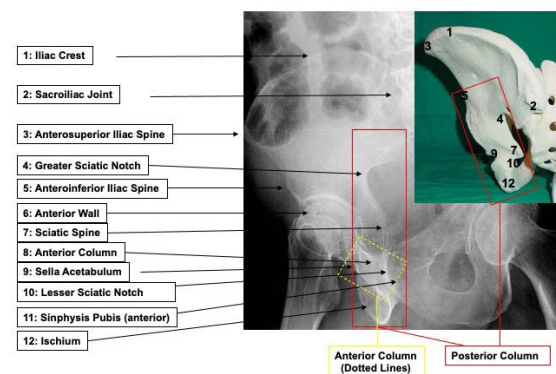


Figure 5: Iliac x-ray projection

and transverse constitute the so-called simple group. Combined fractures of the posterior wall plus posterior column, posterior wall plus transverse, anterior column plus posterior hemitransverse, T-type, and both-columns constitute the so-called complex group. The difference between transverse and both column fractures is that in the transverse pattern a part of the joint remains within the proximal fragment in continuity with the unscathed iliac bone whereas in "both columns" patterns no part of the acetabulum remains attached to the proximal intact iliac bone. Therefore the transverse patterns can be subdivided, according to its affection to the tectum into transtectal, yuxtatectal, or infratectal tracts. This distinction into subtypes is very important because more proximal tracts must be approach anteriorly whereas more distal one may be approach posteriorly.

## 2.4. Treatment

Fractures distally to the weight bearing zone without major displacement (< 2mm) can be conservatively treated. Also those affecting severely the weight bearing zone or in elderly patients, particularly those with a fracture with secondary congruence, can be treated non-surgically.

Surgical approach is essential for proper reduction and osteosynthesis (Figure 7). Anterior column structures are better treated by an anterior approach (ilioinguinal, iliofemoral, Stoppa, or pararectus) whereas posterior structures benefit from a posterior Kocher-Langenbeck approach (K-L). Because of its potential iatrogenic

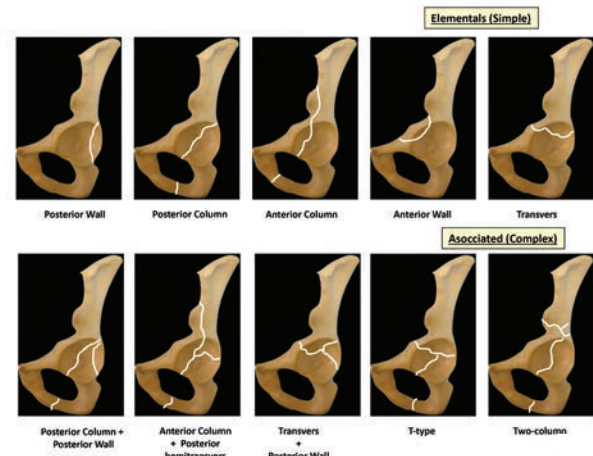


Figure 6: Letournel Classification Of Acetabular Fractures

complications, extended approaches are currently abandoned in favor of combined access. Complex patterns may need these combined approaches<sup>(22)</sup>: whenever there is a posterior wall fracture a posterior K-L access is needed; if an anterior structure is combined with it, then a combined posterior plus anterior approach is mandatory. Distinction within transverse fractures group is very important as reduction and osteosynthesis of more distal patterns (yuxtatectal, and infratectal) can be performed within the same K-L, sparing one surgical approach.

Since acetabular fractures are articular injuries, a few cases can be treated percutaneously; non-communite out of the wall patterns are the best candidates for that. Also nowadays much attention is paid to acetabular fractures in the elderly<sup>(23)</sup>. In these cases, although reduction and osteosynthesis is

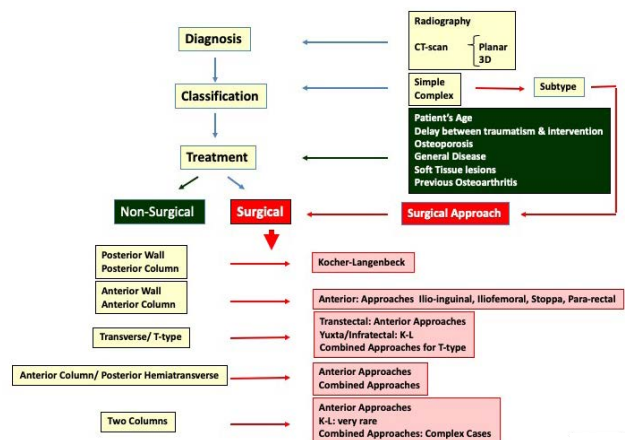


Figure 7: Acetabular Fractures

the common choice in the younger healthy patients, arthroplasty looks the appropriate indication in more complex cases, particularly under the suspicion of femoral head damage and older patients. In pure fractures of the anterior column, intra-acetabular osteosynthesis with arthroplasty<sup>(24)</sup> may be the indication (Fig.8), while whenever the posterior column is broken, it must always be synthesized, whether during arthroplasty or not.



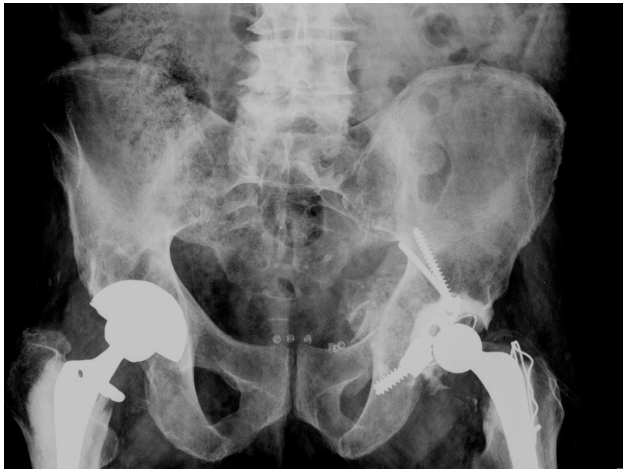

Figure 8: One step surgery: Intra-acetabular osteosynthesis (24) with total hip arthroplasty.

## References

1. The Trauma Audit & Research Network (TARN). <https://www.tarn.ac.uk/>. Last Accessed February 2022.
2. Guerado E, Bertrand ML, Valdes L, Cruz E, Cano JR. Resuscitation of Polytrauma Patients: The Management of Massive Skeletal Bleeding. *Open Orthop J*. 2015;9:283-95.
3. Galvagno SM, Nahmias JT, Young DA. Advanced Trauma Life Support® Update 2019: Management and Applications for Adults and Special Populations. *Anesthesiol Clin* 2019;37:13-32.
4. Guerado E, Medina A, Mata MI, Galvan JM, Bertrand ML. Protocols for massive blood transfusion: when and why, and potential complications. *Eur J Trauma Emerg Surg*. 2016;42:283-95.
5. Young JW, Burgess AR, Brumback RJ, Poka A. Pelvic fractures: value of plain radiography in early assessment and management. *Radiology* 1986;160:445-51.
6. Burgess AR, Eastridge BJ, Young JW, Ellison TS, Ellison PS Jr, Poka A, Bathon GH, Brumback RJ. Pelvic ring disruptions: effective classification system and treatment protocols. *J Trauma* 1990;30:848-56.
7. Dreizin D, Goldman F, LeBedis Ch, Boscak A, Dattwyler M, Bodanapally U, Li G, Andersin S, Maier A, Unberath M. An Automated Deep Learning Method for Tile AO/OTA Pelvic Fracture Severity Grading from Trauma whole-Body CT. *J Digital Imaging* 2021;34:53-65.
8. Guerado E, Bertrand ML, Cano JR, Cerván AM, Galán A. Damage control orthopaedics: State of the art. *World J Orthop*. 2019;10:1-13.
9. Pape HC, Andruszkow H, Pfeifer R, Hildebrand F, Barkatali BM. Options and hazards of the early appropriate care protocol for trauma patients with major fractures: Towards safe definitive surgery. *Injury* 2016;47:787-91.
10. Vallier HA, Wang X, Moore TA, Wilber JH, Como JJ. Timing of orthopaedic surgery in multiple trauma patients: development of a protocol for early appropriate care. *J Orthop Trauma*. 2013;27:543-51.
11. Barcello ALL, Rocha VM, Guimaraes JAM. Current Concepts in Spindylopelvic Dissociation. *Injury* 2017;48:S5-S11.
12. Denis F, Davis S, Comfort T. Sacral fractures: an important problem. Retrospective analysis of 236 cases. *Clin Orthop Rel Res*. 1988;227:67-81.

13. Yi C, Hak DJ. Traumatic spinopelvic dissociation or Ushaped sacral fracture: a review of the literature. *Injury* 2012;43:402-8.
14. Roy-Camille R, Saillant G, Gagna G, Mazel C. Transverse fracture of the upper sacrum. Suicidal jumper's fracture. *Spine (Phila Pa 1976)*. 1985; 10:838-45.
15. Isler B. Lumbosacral lesions associated with pelvic ring injuries. *J Orthop Trauma*. 1990; 4:1-6.
16. Lehman RA, Jr., Kang DG, Bellabarba C. A new classification for complex lumbosacral injuries. *Spine J*. 2012; 12:612-28.
17. Guerado E, Cervan AM, Cano JR. Spinopelvic Injuries. Facts and controversies. *Injury* 2018. 49:449-58.
18. Sevillano-Perez E, Postigo Pozo S, Guerado E, Zamora-Navas P, Prado-Novoa M. Biomechanical models of in vitro constructs for spinopelvic osteosynthesis. *Injury* 2021; 52:S16-S21.
19. Koning MA, Jehan S, Boszczyk AA, Boszczyk BM. Surgical management of U-shaped sacral fractures: a systematic review of current treatment strategies. *Eur Spine J*. 2012; 21:829-36.
20. Williams SK, Quinnan SM. Percutaneous Lumbopelvic Fixation for Reduction and Stabilization of Sacral Fractures with Spinopelvic Dissociation Patterns. *J Orthop Trauma* 2016;30:318-24.
21. Judet R, Judet J, Letournel E. Fractures of the Acetabulum : Classification and Surgical Approaches for Open Reduction. Preliminary Report. *J Bone Jt Surg. Am* 1964;46:1615-46.
22. Guerado E, Cano JR, Cruz E. Simultaneous ilioinguinal and Kocher-Langenbeck approaches for the treatment of complex acetabular fractures. *Hip Int*. 2010;20 Suppl 7:S2-10.
23. Guerado E, Cano JR, Cruz E. Fractures of the acetabulum in elderly patients: an update. *Injury*. 2012;43:S33-41.
24. Guerado E, Cano JR, Cruz E. Surgical Technique: Intracetabular Osteosynthesis with Arthroplasty for Acetabular Fracture in the Octogenarian. *Injury* 2012;43:509-12.

## Questions

1. A spinopelvic dissociation is defined when
  - a. A pelvic fracture is accompanied by a fracture of the lumbar spinous process, causing major instability.
  - b. There is a pelvic fracture through the sacrum and iliac bones.
  - c. There is a traumatic spondylolisthesis that causes pelvis instability.
  - d. A sacral fracture divides two fragments. proximal: spine; distal: rest of pelvis.
2. In a Denis type I comminuted fracture on the left side of the sacrum, the osteosynthesis would consist of:
  - a. Bilateral iliosacral screwing.
  - b. Left transilio-transsacral screwing.
  - c. b + left spinopelvic fixation.
  - d. b + bilateral spinopelvic fixation connected to each other.
3. In the event of fall by an elderly person at home, we must rule out and carry out:
  - a. A fracture of the anterior arch of the pelvis (rami): AP x-ray of the pelvis.
  - b. A pelvic fracture (anterior arch of pelvis and sacrum): CT with contrast.
  - c. A pelvic fracture (anterior arch of pelvis and sacrum): CT without contrast.



- d. A symphysis pubis fracture: obturator and iliac oblique X-ray projections.
- 4. An acetabular fracture requiring surgery must be operated on:
  - a. Immediately if he/she is an elderly patient.
  - b. After some 2-3 days.
  - c. Beyond 3 weeks to avoid intraoperative bleeding.
  - d. Immediately if he/she is a very young patient.
- 5. Of those presented here, the most recommended surgical approach for a fracture of both columns is usually
  - a. Extended Iliofemoral.
  - b. Iliofemoral.
  - c. Kocher-Langenbeck.
  - d. Ilioinguinal.

---

### Answers

1d; 2c; 3c; 4b; 5d



*Olof Wolf, MD, PhD, Associate Professor*

Department of Orthopaedics & Hand Surgery, Uppsala University Hospital, Uppsala, Sweden

Department of Surgical Sciences, Orthopaedics, Uppsala University, Uppsala, Sweden

Olof.wolf@uu.se

Correspondence: Department of Orthopaedics and Hand Surgery  
Uppsala University Hospital, 751 85 Uppsala, Sweden

## **Fractures: Femur, Tibia & Open Fractures**

Fractures in the lower extremities occur at all ages. Osteopenia or osteoporosis increase the risk of fracture even after low-energy trauma. In the lower extremity, fractures of the hip, distal femur and proximal tibia are all considered fragility fractures. The aim of the treatment should be unrestricted mobilization, with full weight bearing, as soon as possible, if not immediately postoperatively. This is particularly important in elderly or otherwise frail patients, who cannot cope with restricted weight bearing. Therefore, the goal should be a stable fixation that allows for full weight bearing<sup>(1)</sup>. The use of hip replacement instead of internal fixation in hip fracture is a good example of immediate stability resulting in better functional outcome. However, elderly frail patients should in most cases be allowed full weight-bearing after all lower extremity fractures in order to promote functional outcome<sup>(2)</sup>.

Always consider the risk of deep vein thrombosis and/or pulmonary embolism, and follow the local guidelines for prophylaxis. Usually, prophylactic antibiotics administered perioperatively are given for patients with fractures treated operatively. The type to choose depends on the mix of pathogens within the region, resistance pattern, any allergy etc. Adhere to local or national guidelines for specific recommendations in your region. Generally, antibiotics should be given immediately (<30–60 min) before surgery and should not exceed the 24-hour post-operative period (i.e. prophylactic versus treatment). There is limited evidence whether to use single or multiple doses of antibiotic doses, and no difference in infection risk has been found<sup>(3)</sup>.

## **1. Hip fractures**

Hip fractures are confirmed via conventional X-ray. If ambiguity, MRI will be useful<sup>(4)</sup>. Surgery should be performed at latest at the day after diagnosis in order to decrease complications and mortality<sup>(5)</sup>. Care should be a multi professional team work and given in close cooperation with geriatricians<sup>(6)</sup>.

Postoperative rehabilitation, during several months, is often necessary in order to regain function. Multidisciplinary teams may be useful when providing rehabilitation<sup>(7)</sup>.

See your local or national guidelines. Or have a look at the British NICE Guidelines for Hip Fractures, available at: <https://www.nice.org.uk/guidance/cg124>

## **2. Femoral neck fracture**

### **2.1. Undisplaced femoral neck fracture**

Undisplaced femoral neck fractures are usually treated with internal fixation and fixed in situ or with a slight reduction maneuver, regardless of patient's age<sup>(8)</sup>. That is, a valgus impaction is accepted, but dorsal tilt may be reduced. Currently, a well performed small randomized trial suggest arthroplasty to be considered for undisplaced fractures in some elderly patients, due to fewer reoperations and better functional outcome, at least in the short run<sup>(9)</sup>. Some larger RCTs are now running and results are expected within the coming years. The discussion also concerns how much dorsal tilt of the femoral head fragment that can be accepted for the fracture still to be regarded as undisplaced. In some reports, an increased failure rate has been associated with dorsal tilt over 20°<sup>(10, 11)</sup>. The more uncommon ventral tilt has also been associated with higher failure rates<sup>(11)</sup>.

Non-surgical treatment is not recommended due to the risk of secondary displacement and the need of frequent check-ups. Nevertheless, in case of contraindications for surgery, or late presentation, it may be an alternative.

### **2.2. Displaced femoral neck fracture**

Treatment options for displaced femoral neck fractures are internal fixation (after closed or open reduction), total hip arthroplasty (THA) or hemiarthroplasty<sup>(12)</sup>. The choice is guided by the patient's biological age, activity level, and comorbidities, or contrary the remaining life span. For a majority, those with functional and/or psychological limitations, hemiarthroplasty is the most suitable choice<sup>(13)</sup>. The benefits are: "forgiving" surgery (can be performed by surgeons with less experience, i.e. acute procedure), shorter surgery time, less bleeding and lower risk of dislocation. In active individuals with a longer remaining life span, hemiarthroplasty carries a high risk of acetabulum erosion. In those cases, THA has been suggested as a better option but recent metaanalyses have failed to detect any clinically relevant difference between THAs and modern hemiarthroplasties<sup>(14)</sup>. THA in fracture cases puts higher demands on the surgeon, as malpositioned implant parts increase the risk of dislocation and pain. The surgery time is longer, and altogether THA procedures may be demanding to cope with, within an acute setting. Arthroplasty in fracture patients should be cemented (less risk of periprosthetic fracture) and inserted via direct lateral approach (less risk of dislocation)<sup>(15–19)</sup>. Increased risk of perioperative death in connection with the cementation process

can be limited by proper anesthesiologic care and cementing technique (thorough lavage of the femoral canal, no excessive pressure etc)<sup>(20)</sup>. In addition, uncemented stems are associated with a higher risk of death after the first postoperative week, potentially due to their higher risk of periprosthetic fracture<sup>(21)</sup>.

Internal fixation may be suitable for younger individuals, as they may have a slightly lower risk of non-union than geriatric patients have. If healthy, the young patients can better withstand a secondary procedure if needed. And if they heal, they maintain their native hip joint. The age limit for primary arthroplasty is controversial. Age limits of 60 or 65 years are suggested. The important thing is to understand the concept of biological age. For example, a 55-year-old with pre-senile dementia and functional limitation may benefit from hemiarthroplasty with a more reliable mobilization. Regarding fracture reduction, there is no clear evidence that open reduction adds any benefit compared to closed ditto, but studies are very scarce. Also, in younger patients with displaced femoral neck fractures, early or open reduction does not reduce the rate of avascular necrosis or non-union<sup>(22)</sup>. Closed reduction and internal fixation can be performed first thing in the morning, with readiness to open reduction if necessary, instead of in the middle of the night.

### 2.3. Extracapsular hip fractures

Basicervical fractures constitute around 10% of femoral neck fractures<sup>(23)</sup>. Mostly, sliding hip screw (SHS), with or without an extra anti-rotational screw, is recommended. With increasing age and displacement arthroplasty is also a viable option.

For trochanteric fractures, there has been a debate for decades whether to use SHSs or intramedullary nails (IMN). Recent studies tend to attenuate this controversy, stating that both implants may yield similar results in terms of hip complications. However, for reverse oblique fractures, IMNs provide better stability<sup>(24, 25)</sup>.

It is more important to understand the "personality" of the fracture and to obtain a good fracture reduction and implant position, than what implant to use<sup>(26)</sup>. A thin lateral wall with a risk of fragmentation during surgery speaks against the use of a simple SHS. In cases with a thin lateral wall, adding a trochanteric stabilization plate to a SHS, or to use an IMN, may prevent medialization. Locking plates have no role in proximal femoral fractures in adults<sup>(27)</sup>.

Subtrochanteric and reverse oblique fractures should be treated with IMNs<sup>(25)</sup>.

### 3. Femoral shaft fractures

Femoral shaft fractures occur mostly due to high energy trauma in young patients, or from low-energy trauma in the elderly. Periprosthetic femoral fractures are an important subgroup that comes with specific challenges. With an earlier implant inserted in the femur, preoperative considerations are even more important. Any loosening of a joint prosthesis must be evaluated, and a loose implant should be revised. CT is useful in preoperative assessment. Use – and understand – the Vancouver classification, for developing a treatment algorithm for the periprosthetic femur fractures<sup>(28, 29)</sup>, and always cooperate with an arthroplasty surgeon!

Femoral shaft fractures can lead to great amount of blood loss. In

high energy trauma, muscular injury and subsequent necrosis can lead to renal insufficiency.

### 3.1. Treatment

Emergency room – temporary stabilization with traction or long posterior splint. In case of severe instability – both generally and/or locally – an immediate external fixation will serve as damage control. This leaves time for other live-saving interventions, and thereafter final internal fixation can take place.

Check vital parameters continuously as blood loss can be substantial, oxygen is often needed. Pain treatment is important, and femoral blocks may be an option.

Surgical treatment with IMN is the most common method for diaphyseal fractures. Plating (with locking screws) is used for metaphyseal fractures, as well as periprosthetic fractures.

### 4. Distal femoral fractures

Patients with distal femoral fractures are similar to hip fracture patients with regards to age, comorbidities and postoperative mortality<sup>(30, 31)</sup>. These patients should receive the same standards of care as hip fracture patients. These fractures are also common as periprosthetic fractures and can be treated with a locking plate or IMN depending on femoral component. There is limited evidence on which treatment is best for the patient as no difference in outcome or reoperation rates were found in a Cochrane review<sup>(32)</sup>.

### 5. Tibial plateau fractures

The treatment and understanding of tibial plateau fractures was for a long time based on the Schatzker classification, i.e. the presence of fracture split and/or depression of the joint, and the involvement of one or two condyles based on the anteroposterior radiograph<sup>(33)</sup>. The goal of treatment is restoration of a stable and congruent joint which is often achieved with a lateral proximal anatomical locking plate, sometimes in combination with filling of the void with bone graft or synthetic void fillers. The conversion to arthroplasty after tibial plateau fracture has been reported to be around 5–8% in large cohorts of patients<sup>(34–37)</sup>. Reduction quality and fracture type is associated with risk of conversion to arthroplasty<sup>(38)</sup>.

The assessment of the fracture configuration with CT scans have led to treatment algorithms taking the three columns of the proximal tibia into consideration<sup>(39)</sup>. The Schatzker classification has also been modified<sup>(40)</sup>.

### 6. Tibial shaft fractures

The tibial shaft is a common fracture localization for open fractures due to thin soft-tissue coverage. Higher impact equals higher risk of complications – the medical history and also progression of symptoms is important.

Compartment syndrome – devastating if not diagnosed and treated!

## 6.1. Treatment

Emergency room: temporary stabilization with long posterior splint, pain treatment and continuous monitoring regarding compartment syndrome.

Nonoperative treatment is suitable for closed fractures with minimal displacement; in a long leg cast. Encourage ambulation with weight-bearing as tolerated in simple transverse fractures but check fracture position with frequent radiographs. The risk is secondary displacement. Long leg cast is difficult to cope with in relation to personal hygiene and mobilization. The long leg cast can be changed to functional bracing or patella tendon bearing lower leg cast at approximately 6 weeks. Compared with surgical fixation, the risk with nonoperative treatment is noted as an increased nonunion and healing time. On the other hand, the risk of surgically related infections is absent. In modern fracture treatment the majority of these patients are offered operative treatment.

Surgical treatment is nowadays used in most unstable fractures. The gold standard is intramedullary nailing. Plating and external fixation with frames are options in specific cases. Intramedullary nailing is the most frequent option, as it leads to fewer non-unions and mal-unions, compared to other methods. It also admits immediate weight-bearing in most cases, leading to a faster return to activity. The major question is whether tibia should be reamed prior to insertion or not. The evidence is not clear, but suggests some advantage for reaming in closed fractures. Reaming also allows for larger diameter nails improving stability.

## 7. Open fractures

Open fractures of the long bones are increasing, now estimated to occur in 30 per 100,000 persons annually.

The injury leads to contamination with pathogens, damaged blood perfusion and soft tissue coverage, and decreased immune defense, which increases the risk of infection (six-folded compared to internal fixation of closed fractures) and healing disturbances. Therefore, treatment should aim at avoiding infection, improve healing and restore function.

### 7.1. Classification

The typical classification of open fractures is the Gustilo-Anderson system (see below) <sup>(41, 42)</sup>. Other classification systems are gaining popularity, for example the Ganga Hospital severity score, which may be better at predicting prognosis and outcome <sup>(43)</sup>.

The Gustilo-Anderson classification:

- i. Wound <1 cm and minimal/clean soft-tissue injury and minimal fracture comminution
- ii. Wound >1 cm and moderate soft-tissue injury/contamination and moderate fracture comminution. Coverage possible after wound revision.
- iii. High energy injury regardless of wound size. Either an open segmental fracture, an open fracture with extensive soft tissue damage, or a traumatic amputation.
  - a. Adequate coverage possible
  - b. Extensive loss of soft-tissue, periosteal stripping, bony exposure. Need for flap. Collaboration

with plastic surgeon.

- c. As B including major arterial injury requiring repair for limb salvage. Collaboration with vascular surgeon.

## 7.2. Treatment

Antibiotics intravenously should be given preferably within 1 hour postinjury (can be given in pre-hospital setting) – observe local guidelines for type of antibiotic drug. Initial pathogens may be less of a problem than secondary nosocomial infections. Protect the wound! The duration of antibiotics is debated. One recommendation is that antibiotics should be given until primary closure of the wound, or for 72 hours, whichever is sooner. Prolonged perioperative antibiotic treatment does not seem to be beneficial in infection prevention <sup>(44, 45)</sup>.

Tetanus prophylaxis should be considered.

Immediate simple reduction and temporary fixation with cast; wound covered in sterile dressings.

Do not irrigate open fractures of the long bones, hindfoot or midfoot in the emergency department before debridement. Initial bacterial culture of no use. Photography is useful for documentation.

## 7.3. Further treatment

Immediate operative treatment of highly contaminated open fractures – otherwise time frames as below:

Gustilo-Anderson III – surgery within 12 hours; exposure, debridement, low pressure lavage, temporary or final fixation, coverage (primary suture/negative pressure wound therapy (several liters of fluid), sterile dressing/graft).

Assistance by vascular (IIIc) and plastic surgeon (IIIb) might be needed. Soft-tissue grafting can be undertaken as a second procedure, preferably within 72 hrs. Final fixation when wound can be covered.

Gustilo II – surgery within 24 hours; treatment as Gustilo III

Gustilo I – similar to closed fracture.

The historical "6-hour rule" – study on guinea pigs by Friedrich in 1898 – has been questioned in recent papers <sup>(46)</sup>. Debridement can supposedly be performed within the first 12-24 hours without any increased risk of infection. This information is useful when transfer may be needed before surgery.

**Amputation** – may be primary treatment in certain cases, such as "a limb is the source of uncontrollable life-threatening bleeding, or a limb is salvageable but attempted preservation would pose an unacceptable risk to the person's life, or a limb is deemed unsalvageable after orthoplastic assessment" (NICE guidelines) <sup>(47)</sup>.

A recent review paper on open fracture is available in the EFORT Open Reviews <sup>(44)</sup>. Better scientific evidence is needed to determine the best treatment strategies for open fractures <sup>(48)</sup>.

## Questions:

1. What is correct about undisplaced femoral neck fracture (one alternative)?
  - a. The fracture should always be reduced to an anatomical



position.

- b. Internal fixation is the most common treatment.
  - c. Non-surgical treatment is regarded equally good as surgical treatment in a majority of patients.
2. Which type of hip complication is more common after uncemented femoral stems in fracture related hip arthroplasty, compared to cemented stems?
3. What is the most important part of emergency treatment for open fractures (one alternative)
- a. Antibiotics should be given intravenously within 1 hour from injury.
  - b. Bacterial cultures should be taken before anything else.
  - c. Thorough wash out of wound before dressings applied.
4. Why is it important to have knowledge upon the timeframes within open fractures can be safely operated on?
5. Mention one benefit and one risk with non-surgical treatment of tibial shaft fractures, compared to surgical treatment?

## Answers

1. b, 2. Periprosthetic fracture, 3. a, 4. To better organize the care chain, to have the possibility to transfer a patient to another hospital with proper competence (i.e. vascular surgeons, plastic surgeons, angiography facilities etc), 5. Benefits: absence of surgical complications such as infection, no need for subsequent hard-ware removal, may be less expensive. Risks: increased risk of nonunion and longer healing time

## References:

1. Trompeter A. A call to arms: it's time to bear weight! *Bone Joint J.* 2020;102-B(4):403-6.
2. British Geriatrics Society (BOAST). BOA Standard. The care of the older or frail orthopaedic trauma patient. 2019. Available from: <https://www.bgs.org.uk/resources/boast-the-care-of-the-older-or-frail-orthopaedic-trauma-patient>.
3. Ryan SP, Kildow BJ, Tan TL, Parvizi J, Bolognesi MP, Seyler TM, et al. Is There a Difference in Infection Risk Between Single and Multiple Doses of Prophylactic Antibiotics? A Meta-analysis. *Clin Orthop Relat Res.* 2019;477(7):1577-90.
4. Haj-Mirzaian A, Eng J, Khorasani R, Raja AS, Levin AS, Smith SE, et al. Use of Advanced Imaging for Radiographically Occult Hip Fracture in Elderly Patients: A Systematic Review and Meta-Analysis. *Radiology.* 2020;296(3):521-31.
5. Welford P, Jones CS, Davies G, Kunutsor SK, Costa ML, Sayers A, et al. The association between surgical fixation of hip fractures within 24 hours and mortality : a systematic review and meta-analysis. *Bone Joint J.* 2021;103-B(7):1176-86.
6. Patel JN, Klein DS, Sreekumar S, Liporace FA, Yoon RS. Outcomes in Multidisciplinary Team-based Approach in Geriatric Hip Fracture Care: A Systematic Review. *J Am Acad Orthop Surg.* 2020;28(3):128-33.
7. Beckmann M, Bruun-Olsen V, Pripp AH, Bergland A, Smith T, Heiberg KE. Effect of exercise interventions in the early phase to improve physical function after hip fracture - A systematic review and meta-analysis. *Physiotherapy.* 2020;108:90-7.
8. Nielsen LL, Smidt NS, Erichsen JL, Palm H, Viberg B. Posterior tilt in nondisplaced femoral neck fractures increases the risk of reoperations after osteosynthesis. A systematic review and meta-analysis. *Injury.* 2020;51(12):2771-8.
9. Dolatowski FC, Frihagen F, Bartels S, Opland V, Saltyte Benth J, Talsnes O, et al. Screw Fixation Versus Hemiarthroplasty for Nondisplaced Femoral Neck Fractures in Elderly Patients: A Multicenter Randomized Controlled Trial. *J Bone Joint Surg Am.* 2019;101(2):136-44.
10. Palm H, Gosvig K, Krashenninnikoff M, Jacobsen S, Gebuhr P. A new measurement for posterior tilt predicts reoperation in undisplaced femoral neck fractures: 113 consecutive patients treated by internal fixation and followed for 1 year. *Acta Orthop.* 2009;80(3):303-7.
11. Sjöholm P, Sundkvist J, Wolf O, Skoldenberg O, Gordon M, Mukka S. Preoperative Anterior and Posterior Tilt of Garden I-II Femoral Neck Fractures Predict Treatment Failure and Need for Reoperation in Patients Over 60 Years. *JB JS Open Access.* 2021;6(4).
12. Lewis SR, Macey R, Stokes J, Cook JA, Eardley WG, Griffin XL. Surgical interventions for treating intracapsular hip fractures in older adults: a network meta-analysis. *Cochrane Database Syst Rev.* 2022;2(2):CD013404.
13. Investigators H, Bhandari M, Einhorn TA, Guyatt G, Schemitsch EH, Zura RD, et al. Total Hip Arthroplasty or Hemiarthroplasty for Hip Fracture. *N Engl J Med.* 2019;381(23):2199-208.
14. Ekhtiari S, Gormley J, Axelrod DE, Devji T, Bhandari M, Guyatt GH. Total Hip Arthroplasty Versus Hemiarthroplasty for Displaced Femoral Neck Fracture: A Systematic Review and Meta-Analysis of Randomized Controlled Trials. *J Bone Joint Surg Am.* 2020;102(18):1638-45.
15. Enocson A, Hedbeck CJ, Tidermark J, Pettersson H, Ponzer S, Lapidus LJ. Dislocation of total hip replacement in patients with fractures of the femoral neck. *Acta Orthop.* 2009;80(2):184-9.
16. Fernandez MA, Achten J, Parsons N, Griffin XL, Png ME, Gould J, et al. Cemented or Uncemented Hemiarthroplasty for Intracapsular Hip Fracture. *N Engl J Med.* 2022;386(6):521-30.
17. Jobory A, Karrholm J, Hansson S, Akesson K, Rogmark C. Dislocation of hemiarthroplasty after hip fracture is common and the risk is increased with posterior approach: result from a national cohort of 25,678 individuals in the Swedish Hip Arthroplasty Register. *Acta Orthop.* 2021;92(4):413-8.
18. Lewis SR, Macey R, Parker MJ, Cook JA, Griffin XL. Arthroplasties for hip fracture in adults. *Cochrane Database Syst Rev.* 2022;2(2):CD013410.
19. Rogmark C, Natman J, Jobory A, Hailer NP, Cnudde P. The association of surgical approach and bearing size and type with dislocation in total hip arthroplasty for acute hip fracture. *Bone Joint J.* 2022;104-B(7):844-51.
20. Membership of Working P, Griffiths R, White SM, Moppett IK, Parker MJ, Chesser TJ, et al. Safety guideline: reducing the risk from cemented hemiarthroplasty for hip fracture 2015: Association of Anaesthetists of Great Britain and Ireland British Orthopaedic Association British Geriatric Society. *Anaesthesia.* 2015;70(5):623-6.

21. Costa ML, Griffin XL, Pendleton N, Pearson M, Parsons N. Does cementing the femoral component increase the risk of peri-operative mortality for patients having replacement surgery for a fracture of the neck of femur? Data from the National Hip Fracture Database. *J Bone Joint Surg Br.* 2011;93(10):1405-10.
22. Damany DS, Parker MJ, Chojnowski A. Complications after intracapsular hip fractures in young adults. A meta-analysis of 18 published studies involving 564 fractures. *Injury.* 2005;36(1):131-41.
23. Sundkvist J, Bruggeman A, Sayed-Noor A, Moller M, Wolf O, Mukka S. Epidemiology, classification, treatment, and mortality of adult femoral neck and basicervical fractures: an observational study of 40,049 fractures from the Swedish Fracture Register. *J Orthop Surg Res.* 2021;16(1):561.
24. Gronhaug KML, Dybvik E, Matre K, Ostman B, Gjertsen JE. Intramedullary nail versus sliding hip screw for stable and unstable trochanteric and subtrochanteric fractures : 17,341 patients from the Norwegian Hip Fracture Register. *Bone Joint J.* 2022;104-B(2):274-82.
25. Lewis SR, Macey R, Gill JR, Parker MJ, Griffin XL. Cephalomedullary nails versus extramedullary implants for extracapsular hip fractures in older adults. *Cochrane Database Syst Rev.* 2022;1(1):CD000093.
26. De Bruijn K, den Hartog D, Tuinebreijer W, Roukema G. Reliability of predictors for screw cutout in intertrochanteric hip fractures. *J Bone Joint Surg Am.* 2012;94(14):1266-72.
27. Streubel PN, Moustoukas MJ, Obremskey WT. Mechanical failure after locking plate fixation of unstable intertrochanteric femur fractures. *J Orthop Trauma.* 2013;27(1):22-8.
28. Duncan CP, Masri BA. Fractures of the femur after hip replacement. *Instr Course Lect.* 1995;44:293-304.
29. Masri BA, Meek RM, Duncan CP. Periprosthetic fractures evaluation and treatment. *Clin Orthop Relat Res.* 2004(420):80-95.
30. Smith JR, Halliday R, Aquilina AL, Morrison RJ, Yip GC, McArthur J, et al. Distal femoral fractures: The need to review the standard of care. *Injury.* 2015;46(6):1084-8.
31. Wolf O, Mukka S, Ekelund J, Moller M, Hailer NP. How deadly is a fracture distal to the hip in the elderly? An observational cohort study of 11,799 femoral fractures in the Swedish Fracture Register. *Acta Orthop.* 2021;92(1):40-6.
32. Claireaux HA, Searle HKC, Parsons NR, Griffin XL. Interventions for treating fractures of the distal femur in adults. *Cochrane Database of Systematic Reviews.* 2022(10).
33. Schatzker J. Compression in the surgical treatment of fractures of the tibia. *Clin Orthop Relat Res.* 1974(105):220-39.
34. Donovan RL, Smith JRA, Yeomans D, Bennett F, Smallbones M, White P, et al. Epidemiology and outcomes of tibial plateau fractures in adults aged 60 and over treated in the United Kingdom. *Injury.* 2022;53(6):2219-25.
35. Elsoe R, Johansen MB, Larsen P. Tibial plateau fractures are associated with a long-lasting increased risk of total knee arthroplasty a matched cohort study of 7,950 tibial plateau fractures. *Osteoarthritis Cartilage.* 2019;27(5):805-9.
36. Tapper VS, Pamilo KJ, Haapakoski JJ, Toom A, Paloneva J. Risk of total knee replacement after proximal tibia fracture: a register-based study of 7,841 patients. *Acta Orthop.* 2022;93:179-84.
37. Wasserstein D, Henry P, Paterson JM, Kreder HJ, Jenkinson R. Risk of total knee arthroplasty after operatively treated tibial plateau fracture: a matched-population-based cohort study. *J Bone Joint Surg Am.* 2014;96(2):144-50.
38. Olerud F, Garland A, Hailer NP, Wolf O. Risk of conversion to total knee arthroplasty after surgically treated tibial plateau fractures: an observational cohort study of 439 patients. *Acta Orthop.* 2024;95:206-11.
39. Luo CF, Sun H, Zhang B, Zeng BF. Three-column fixation for complex tibial plateau fractures. *J Orthop Trauma.* 2010;24(11):683-92.
40. Schatzker J, Kfuri M. Revisiting the management of tibial plateau fractures. *Injury.* 2022;53(6):2207-18.
41. Gustilo RB, Anderson JT. Prevention of infection in the treatment of one thousand and twenty-five open fractures of long bones: retrospective and prospective analyses. *J Bone Joint Surg Am.* 1976;58(4):453-8.
42. Gustilo RB, Mendoza RM, Williams DN. Problems in the management of type III (severe) open fractures: a new classification of type III open fractures. *J Trauma.* 1984;24(8):742-6.
43. Rajasekaran S, Naresh Babu J, Dheenadhayalan J, Shetty AP, Sundararajan SR, Kumar M, et al. A score for predicting salvage and outcome in Gustilo type-IIIA and type-IIIB open tibial fractures. *J Bone Joint Surg Br.* 2006;88(10):1351-60.
44. Elniel AR, Giannoudis PV. Open fractures of the lower extremity: Current management and clinical outcomes. *EFORT Open Rev.* 2018;3(5):316-25.
45. Vanvelk N, Chen B, Van Lieshout EMM, Zalavras C, Moriarty TF, Obremskey WT, et al. Duration of Perioperative Antibiotic Prophylaxis in Open Fractures: A Systematic Review and Critical Appraisal. *Antibiotics (Basel).* 2022;11(3).
46. Schenker ML, Yannascoli S, Baldwin KD, Ahn J, Mehta S. Does timing to operative debridement affect infectious complications in open long-bone fractures? A systematic review. *J Bone Joint Surg Am.* 2012;94(12):1057-64.
47. NICE guideline. Fractures (complex): assessment and management 2016. Available from: <https://www.nice.org.uk/guidance/ng37/>.
48. Chan JK, Aquilina AL, Lewis SR, Rodrigues JN, Griffin XL, Nanchahal J. Timing of antibiotic administration, wound debridement, and the stages of reconstructive surgery for open long bone fractures of the upper and lower limbs. *Cochrane Database Syst Rev.* 2022;4(4):CD013555.





Dr. Jose Vicente Andrés Peiró, MD, PhD  
[josevicente.andres@vallhebron.cat](mailto:josevicente.andres@vallhebron.cat), <https://orcid.org/0000-0002-5655-8658>

Dr. Jordi Tomás Hernández, MD  
[jordi.tomas@vallhebron.cat](mailto:jordi.tomas@vallhebron.cat)

Orthopaedic Trauma Unit, Department of Orthopaedic Surgery and Traumatology, Hospital Universitari Vall d'Hebron, Barcelona, Spain

## Fractures: Pilon, Ankle, Talus & Calcaneus

### Abstract

- True tibial pilon fractures result from high-energy axial loading, often causing significant soft tissue damage and comminution. Temporary external fixation is essential (span-scan-plan). The gold standard treatment involves open reduction and internal fixation with anatomically designed implants, with the combination of surgical approaches proving useful.
- Ankle fractures involve both bony and ligamentous injuries, affecting patients of all demographics. They present with varied clinical manifestations and fracture patterns, from stable lesions managed nonoperatively to highly unstable cases requiring temporary external fixation and soft tissue reconstruction. Emphasis on posterior malleolus fixation has increased for talocrural and distal tibiofibular congruence. Surgical treatment continues to evolve, offering many approaches and implants.
- Talus fractures are rare injuries resulting from high-energy mechanisms, primarily located in the neck region. Soft tissue injuries and open fractures are frequent, contributing to an overall poor prognosis.
- Calcaneus fractures represent the most frequent among tarsal bones, typically characterized by axial loading patterns involving the subtalar joint. Given the high rates of postoperative complications, nonoperative management is a viable option for nondisplaced fractures, patients unfit for surgery either locally or systemically, and noncompliant individuals.

fractures. They are rare injuries, representing <1% of all lower limb fractures and typically presenting in young males experiencing multiple trauma, such as traffic accidents or falls from great heights.

### 1.2. Diagnosis

As with any fracture, we will conduct a detailed medical history, including relevant comorbidities and mechanism of injury. The physical examination may reveal severe soft tissue contusion or even compartment syndrome. Neurovascular status should be carefully assessed. Adhering to acute trauma care guidelines is crucial in patients with high-energy mechanisms.

The initial radiographic evaluation must include plain X-Rays in orthogonal projections (AP and lateral) of the entire tibia, including the knee and foot. CT scan is essential for identifying the main fracture lines and, therefore, for surgical planning.

Various systems have been described to classify these fractures. The classic, by **Rüedi and Allgower**, categorizes injuries based on their displacement and comminution: type I fractures are non-displaced, type II are displaced but without comminution, and type III are impacted and highly comminuted. Within the **AO/OTA** classification, tibial pilon fractures encompass groups 43B (partial articular fractures) and 43C (complete articular fractures, with complete separation of the articular surface from diaphysis).

### 1.3. Treatment

Nonoperative treatment is reserved for stable patterns in patients with very low functional capacity. Therefore, most patients will benefit from surgical treatment. The surgical objectives include restoring joint alignment and congruence, reconstructing articular surfaces anatomically, achieving stable fixation to promote bone healing, and ultimately establishing a functional, pain-free ankle joint.

Effective **soft tissue management** is crucial for preventing complications. Injuries showing evident skin damage or having the potential to develop it, particularly axial-loading fractures, can benefit from staged treatment employing spanning external fixation, known as the "span-scan-plan" approach. Typically, squared or delta frames are utilized, featuring two anterior tibia pins and a transfixing pin in the calcaneus (Figure 1). It's imperative that pins are positioned to avoid future incisions and plates. The frame should be colinear with the ankle joint alignment to prevent inadvertent displacement, which could impede soft tissue recovery. Emergent fixation of the fibula is typically discouraged. Open

## 1. Pilon Fractures

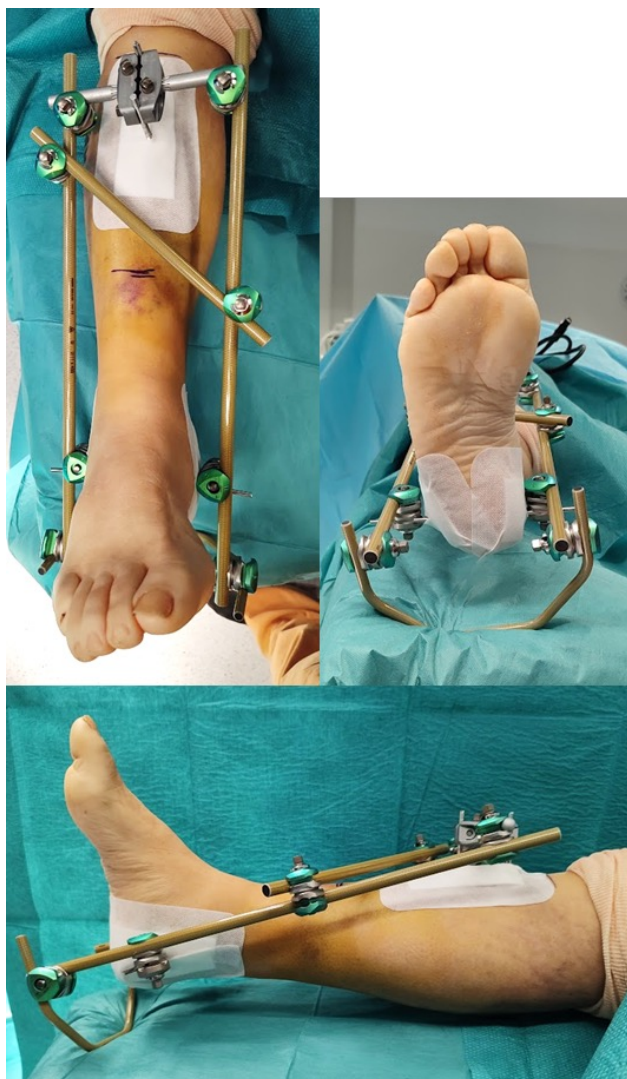### 1.1. Introduction

Pilon fractures are fractures of the tibia involving the distal weight-bearing articular surface. We distinguish two patterns depending on the injury mechanism:

- Low-energy **rotational** mechanisms cause spiral fractures of the tibia that extend with simple lines to the ankle joint. Soft tissue damage is usually minimal. They occur in all age groups.
- High-energy **axial-loading** fractures associate severe comminution and soft tissue damage, often presenting as open injuries. These are considered the true pilon



Figure 1: Authors' preferred method for spanning external fixation around the ankle: a squared frame configuration.

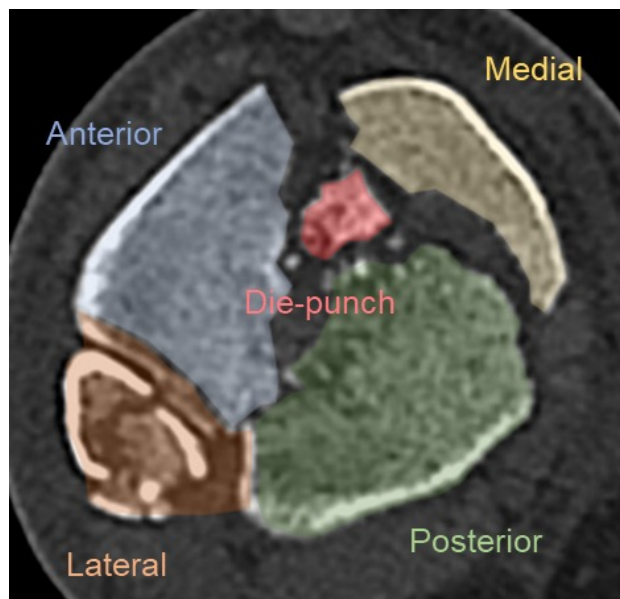


fractures require adherence to standardized protocols, involving early administration of antibiotics, thorough debridement and irrigation of flesh and bone in the operating room, sterile airtight coverage, and prompt assessment by plastic surgeons. The definitive fixation will only be performed when the soft tissues have reached sufficient improvement.

**Rotational fractures** can often be stabilized early and minimally invasively using intramedullary nails or plates. Articular fractures tend to be simple and can be managed percutaneously with forceps and cannulated screws.

The preferred treatment for most **axial loading fractures** is open reduction and internal fixation with plates, which can be technically demanding. The choice of approaches and implants should consider the soft tissue status and the main fracture lines (Figure 2). In fractures involving all four columns, fixation typically begins posteriorly, often through a posterolateral approach, to restore joint axis and length. Subsequently, fine joint reduction will be performed, with midline anterior approaches being very useful. It may be necessary to utilize bone grafts from the surrounding metaphysis or substitutes to provide support for articular fragments. For sequential approach, patients can be placed in a floating position or prone, and later supine. When combining

Figure 2: The constant set of lines and fragments divides the pilon into 4 columns: anterior and posterior, separated by the intermalleolar line; medial and lateral, the latter including the fibula and tibiofibular joint. Die-punch depressed fragments are frequent in the center.



approaches, there should be a minimum separation of 6-7cm to prevent necrosis of the skin bridge. Minimally invasive or stab incisions may be combined with shorter intervals. The fibula can usually be stabilized with elastic intramedullary implants (Figure 3).

In instances of extensive joint damage or among patients with minimal functional requirements, such as those with spinal cord injuries, primary arthrodesis may be contemplated, typically utilizing a retrograde tibiototalcanal nail. Circular external fixation is an option for cases with significant soft tissue involvement, irreparable metaphyseal comminution, or bone loss. Hybrid constructs are linked to higher rates of nonunion and are not recommended.

The aftercare usually entails immobilization with a posterior below-knee plaster splint, accelerating wound healing. Subsequently, an early rehabilitation process will begin. The timing of weight-bearing initiation will hinge upon the extent of joint involvement and the achieved stability of fixation.

## 1.4. Outcomes and complications

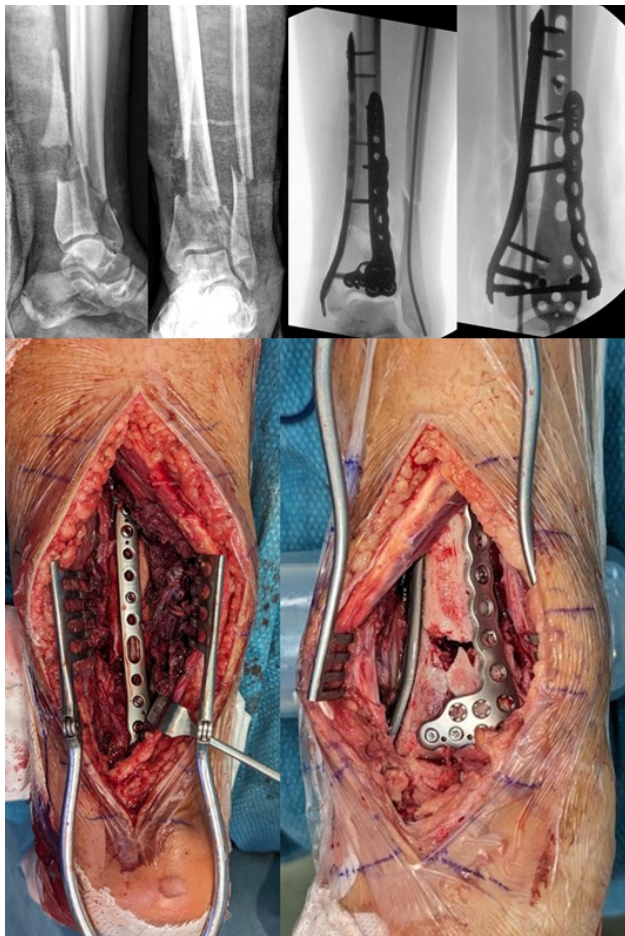
Low-energy fractures generally exhibit a favorable prognosis. Conversely, high-energy fractures often carry poor outcomes. They are associated with elevated complication rates, notably wound-healing issues and infections. In later stages, a significant proportion of patients experience joint stiffness and post-traumatic osteoarthritis, with varying clinical implications. It is important to emphasize the need for staged treatment and the management by surgeons with extensive experience in fracture fixation.

## 2. Ankle Fractures

### 2.1. Introduction

Ankle fractures result from rotational mechanisms, affecting the distal tibia and fibula (malleolar fractures) along with their

Figure 3: Sequential posterolateral and anterior midline approaches for treating an axial loading fracture.



surrounding ligaments. They are highly prevalent, comprising 10% of all fractures and ranking as the most common articular fractures and the second leading cause of fracture surgery, trailing fragility hip fractures. Their incidence shows a bimodal distribution, affecting young males and older females.

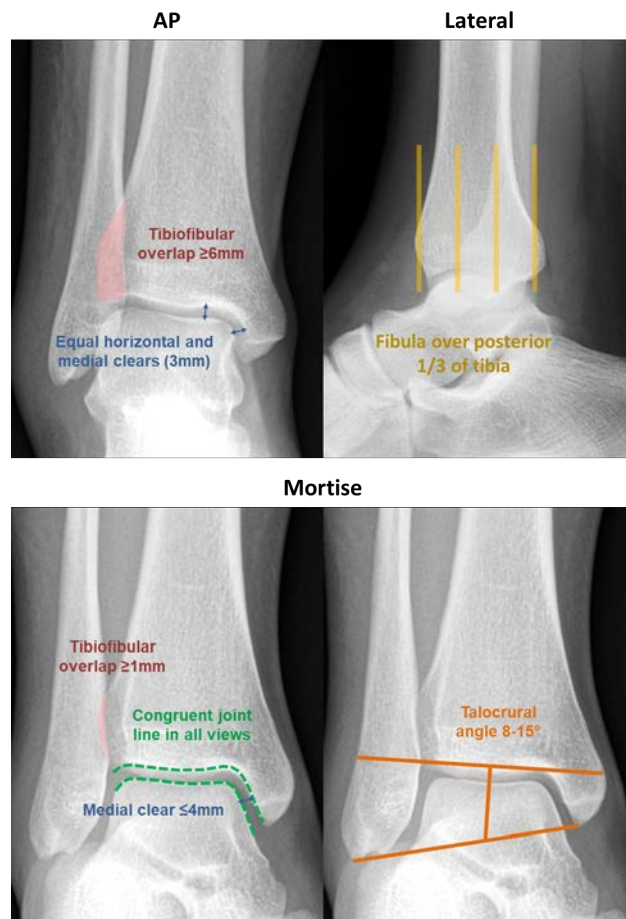
## 2.2. Diagnosis

Usually, these fractures present as isolated injuries caused by sprains. Comorbidities significantly impact outcomes, thus, our goal is to identify and optimize them whenever feasible, such as managing glycemic levels in diabetics and promoting smoking cessation.

Ankle fractures typically manifest as fracture-dislocations, requiring immediate reduction, or occasionally as open fractures, predominantly on the medial aspect. Temporary spanning external fixation may be necessary. The extent of soft tissue damage varies, depending on both the fracture pattern and the patient's underlying health conditions, with blister formation being a common feature.

The initial radiological evaluation will consist of **three X-Ray views**: AP, lateral, and mortise (AP with 15° internal rotation). Figure 4 outlines the normal radiographic anatomical relationships of the ankle, which are crucial for identifying associated injuries to the deltoid ligament and syndesmosis, as well as for intraoperative assessment of reduction. Stressed X-Rays play a limited role, often overestimating ligamentous instability. The utility of weight-

Figure 4: Normal ankle landmarks on the three necessary X-Ray views.



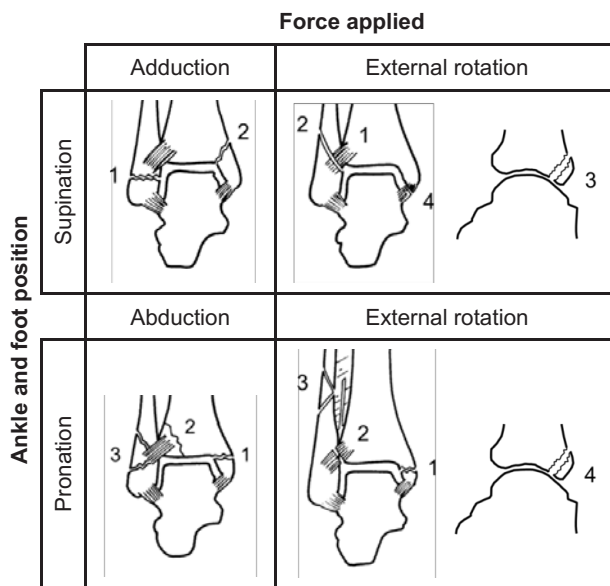
bearing X-Rays is constrained by patients' inability to bear weight immediately after the fracture.

Several classification systems based on plain X-Rays have been described, with the most used being the Danis-Weber, AO/OTA, and Lauge-Hansen classifications. The **Danis-Weber** classification categorizes fractures based on the level of the fibular fracture in relation to the syndesmosis into: infrasyndesmotom (A), transsyndesmotom (B), and suprasyndesmotom (C). In the **AO/OTA** classification, ankle fractures correspond to segment 44, following a scheme identical to that of Danis-Weber. The **Lauge-Hansen** classification is more intricate as it correlates the fracture with the mechanism of injury. According to these authors, the fracture pattern is affected by the position of the ankle and foot, as well as the direction of the applied force. They propose that osteoligamentous elements fail sequentially, leading to a progressive increase in instability (Figure 5):

- Supination-adduction: infrasyndesmal fracture of fibula → vertical shear fracture of tibial malleolus.
- Supination-external rotation: anterior syndesmosis (ligament or Wagstaffe-Le Fort fragment in fibula) → oblique fracture of fibula in coronal plane → posterior syndesmosis (ligament or Volkmann fragment in tibia) → tibial malleolus fracture or deltoid ligament injury (bimalleolar equivalent).
- Pronation-abduction: tibial malleolus fracture → syndesmosis (usually Tillaux-Chaput tibial fragment) → comminuted or oblique fracture in the sagittal plane of fibula.
- Pronation-external rotation: medial malleolus fracture



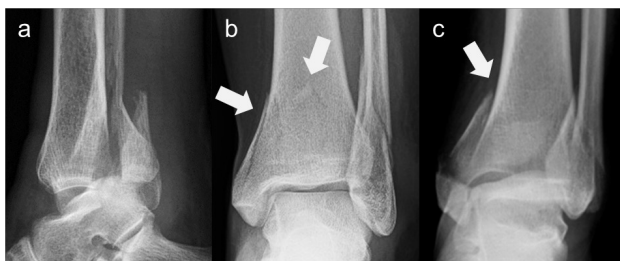Figure 5: Lauge-Hansen classification: sequential injury of ankle bones and ligaments.



→ anterior syndesmosis (ligament) → suprasyndesmal fibula (Dupuytren for diaphysis and Maisonneuve for surgical neck) → posterior syndesmosis (ligament or Volkmann fragment).

While less reproducible than the Danis-Weber and AO/OTA systems, this classification offers insight into ligamentous injuries, which has implications for treatment. However, not all fractures adhere to its patterns, and recent studies have questioned their correspondence with injury mechanisms. Indeed, fracture patterns like the **hyperplantarflexion posteromedial variant** fall outside the bounds of this classification (Figure 6).

Figure 6: X-Ray findings indicating substantial damage to the posterior malleolus: a) posterior fragment visible on lateral view; b) double medial contour and misty mountain sign; c) spur sign, which is pathognomonic of posteromedial variants.

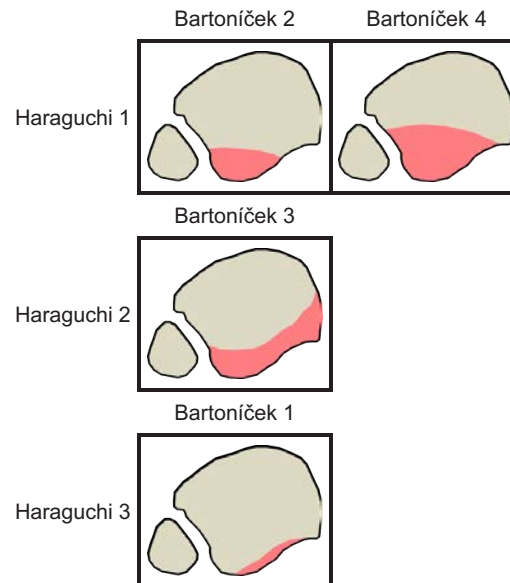


In recent years, a better understanding of ankle biomechanics has increased the importance attributed to posterior malleolus fractures. Consider obtaining a **CT scan** when significant posterior malleolar involvement is suspected (Figure 6). The classifications most frequently utilized in this context are those of **Haraguchi** and **Bartoníček**, both of which rely on CT findings (Figure 7).

## 2.3. Treatment

**Nonoperative treatment** is recommended for isolated fractures of the fibula, provided they are infrasyndesmotic and do not exhibit displacement compromising the ankle stability, or transsyndesmotic without involvement of the medial ligaments

Figure 7: Correspondence between Haraguchi and Bartoníček classifications. Roman numerals replaced with Arabic numerals to improve clarity.



(bimalleolar equivalent). The absence of medial involvement is determined by a combination of clinical signs (medial tenderness and bruising) and radiological findings. As previously mentioned, stressed X-Rays such as the gravity test have controversial utility. It may be also acceptable to consider conservative treatment for non-displaced bimalleolar fractures in patients with limited function. Nonoperative treatment involves immobilization with a cast for a minimum of 4 weeks, followed by an intensive rehabilitation process. Patients with stable joints on weight-bearing X-Rays may commence protected weight-bearing earlier.

The goals of **operative treatment** encompass achieving bony frame healing with precise alignment and restoration of the articular surface, alongside direct or indirect repair of ligaments. This aims to reestablish a joint that is stable, pain-free, and capable of weight-bearing, leading to good functional results. In most cases, fixation begins at the fibula, continues with the medial malleolus, and ends with the syndesmosis. In cases requiring fixation of the posterior malleolus, it is usually addressed first.

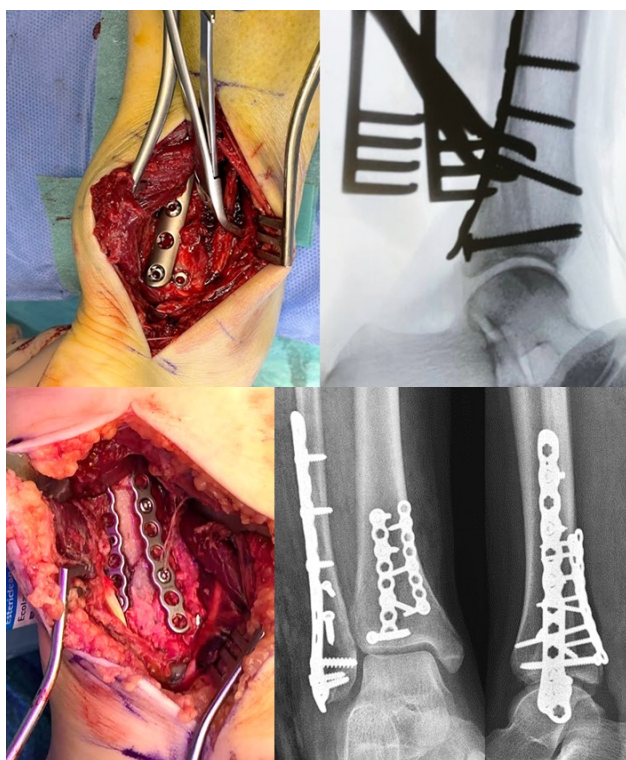
We should aim to restore the length and rotation of the **fibula**. Once reduced, most fibular fractures exhibit simple lines that can be stabilized with lag screws and neutralization plates. Bridging plates are useful for dealing with comminution. Displaced infrasyndesmotic fractures can be stabilized using intramedullary lag screws or tension band wiring. In recent years, fibular-specific intramedullary nails have emerged as a valid solution, particularly for transsyndesmotic fractures. The reduced exposure makes it particularly useful for patients at a higher risk of wound-related complications.

Proper exposure of the **medial malleolus** fracture is imperative to ensure anatomical reduction of the medial gutter and prevent periosteal interposition. Fixation is typically accomplished with two compression cannulated screws, although a single screw may be adequate for small fragments. In cases involving comminution or very small fragments, hook plates and tension bands serve as valuable options. For shearing vertical fractures, we will add an antiglide plate to enhance fixation.

There remains considerable controversy regarding the indications

for fixation of the **posterior malleolus**. Most authors agree that fixation is recommended whenever the fracture significantly disrupts the congruence of the talocrural or distal tibiofibular joints, having the potential to reduce the need for transsyndesmotic stabilization. Haraguchi type I fractures are addressed through posterolateral approaches, which also allow for instrumentation of the fibula. Haraguchi type II fractures are best managed through posteromedial approaches, providing sufficient skin bridge for independent fibular incisions (Figure 8). However, posterior

*Figure 8: Upper line: Posterior malleolus fixation and fibular reduction through a single-window posterolateral approach. Down: Fixation of a Haraguchi II posterior malleolus through a posteromedial approach.*



approaches have other drawbacks, such as wound-healing issues and neurological injuries, so they must be used rationally.

We'll assess **syndesmosis** stability after fixing all bony elements of the ankle, focusing on those crucial for distal tibiofibular joint congruence. The Cotton test, applying external rotation to the ankle in a neutral position, is the most sensitive dynamic radiological test. Unstable syndesmosis shows reduced tibiofibular overlap. Fibula reduction in the tibial notch precedes fixation. No consensus exists on screw configuration for transsyndesmotic stabilization or removal timing. Suture-buttons are increasingly used due to less frequent removal. In Maisonneuve fractures, with severe interosseous membrane injury, two tetracortical screws are advised. Diabetic neuropathy patients require stable constructs; thus, those with multiple transsyndesmotic screws are recommended.

In very low-demand patients or those at high risk of complications, such as those with Charcot arthropathy, primary arthrodesis with a retrograde tibiototalcalcaneal nail may be considered. It minimizes soft tissue aggression while providing resilient fixation, enabling nearly immediate weight-bearing, which is particularly beneficial for frail patients. The main complication is locking screw loosening.

As in pilon fractures, it is advisable to immobilize the ankle

with a below-knee splint until wound healing is complete. Once the wounds have healed, physical therapy will commence. At this stage, if the stability of the fixation is deemed adequate, most patients could initiate progressive weight-bearing.

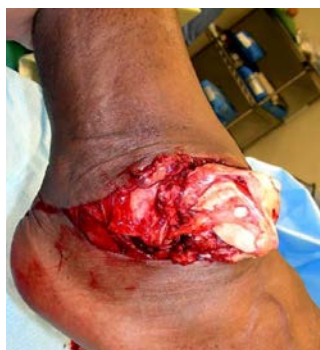## 2.4. Outcomes and complications

Surgical treatment of ankle fractures typically results in favorable outcomes at a low complication rate. However, due to their high incidence, managing their complications is a routine aspect of clinical practice. The most frequent complications involve wound-healing issues and infections, especially worrisome in the diabetic and the elderly. Mechanical complications are rare, with improper management of syndesmotic instability being the most notable. Long-term prognosis suggests that patients with more unstable injuries, such as fracture-dislocations, have an elevated risk of post-traumatic osteoarthritis.

## 3. Talus Fractures

### 3.1. Introduction

Fractures of the talus rank as the second most frequent fractures in the tarsus, following those of the calcaneus. However, they are uncommon, representing only 0.3% of all fractures. Talar fractures typically occur due to high-energy trauma and often result in severe soft tissue damage and open fractures. Many times, they occur in the context of mangled extremities in combination with multiple ankle and foot injuries, implying an elevated risk of amputation. Sometimes, they present as closed injuries with severe fragment displacement or, in extreme cases, as an extruded talus (Figure 9). Urgent closed or open reduction may be necessary to prevent necrosis of the overlying skin. It is also essential to maintain a high



*Figure 9: An extruded talus, requiring immediate debridement, irrigation, reduction and stabilization.*

index of suspicion for the possibility of compartment syndrome in the foot.

Up to 50% of these fractures occur in the talar neck. The remaining 50% are distributed among fractures of the body and processes. The "aviator's fracture" typically affects the neck of the talus and occurs due to a high-energy dorsiflexion. 70% percent of the talus surface is covered by hyaline cartilage, rendering its vascularization precarious and making it prone to avascular necrosis following trauma. The primary blood supply to the talar body originates from branches of the posterior tibial artery, which penetrate the bone from its medial aspect.



## 3.2. Diagnosis

The initial imaging evaluation will include the three classic X-ray views of the ankle (anteroposterior, lateral, and mortise) and three foot views (anteroposterior, lateral, and oblique). **Canale's medial oblique view** allows for precise assessment of neck alignment and is primarily used intraoperatively. CT scan is essential in all cases for preoperative planning, while MRI may offer valuable insights for early detection of avascular necrosis. During postoperative follow-up, the subchondral lucency of the talar dome in the X-ray AP view is a sign of bone viability and a reduced risk of osteonecrosis (Hawkins' sign).

Fractures of the **talus neck** are typically classified according to the system proposed by **Hawkins**. This classification takes into consideration the disruption of medial vascularization, which correlates with the risk of avascular necrosis. In type III and IV fractures, typically induced by high-energy axial loading mechanisms, the likelihood of this complication is significantly higher. Fractures of the talus body are classified according to the **Sneppen** and **AO/OTA** systems, both referring to the location and morphology of the fracture line within the talocrural joint. Fractures of the talus processes are included as types D and E in the Sneppen classification.

## 3.3. Treatment

**Nonoperative treatment** is indicated for most nondisplaced fractures. It entails immobilization in a below-the-knee cast for a period of 6-8 weeks and restriction of weight-bearing up to 12 weeks, for which patient compliance is paramount. In the event of secondary displacement, surgery may be necessary.

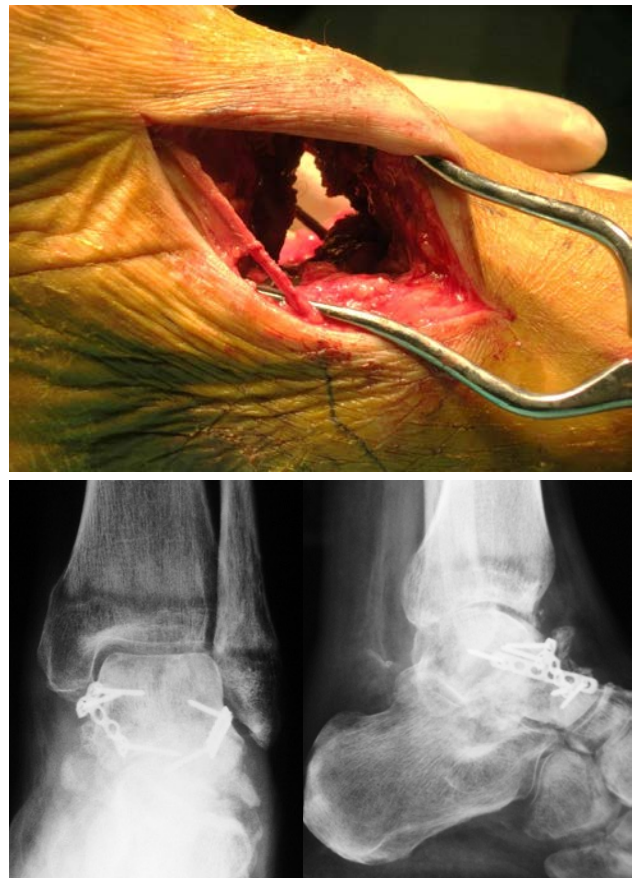The goal of **surgical intervention** is to restore articular surfaces using a rigid construct to maintain alignment until bony consolidation is complete. In cases of simple displaced talar neck fractures, closed reduction may suffice, with fixation achieved via percutaneous screws. However, open reduction is typically necessary, and **various approaches** are available:

- Anteromedial: in line with the posterior aspect of the tibialis anterior tendon to access the neck.
- Anterolateral: provides access to the neck by splitting the extensor digitorum brevis.
- Posteromedial: typically, between the flexor hallucis longus and the flexor digitorum longus, allowing to the posterior process and body.

It is worth noting that the approach options must adapt to the soft tissue condition. Both the anteromedial and anterolateral approaches can be posteriorly extended to access the talus body by performing an osteotomy of the corresponding malleolus, typically stabilized with predrilled screws. Fixation is commonly achieved with countersunk interfragmentary headless screws. In cases of neck comminution, plate utilization is favored. In such scenarios, a combination of the anteromedial and anterolateral approaches is beneficial (Figure 10). Fixation of fractures involving the talus processes is necessary when significant displacement of weight-bearing articular surfaces is associated with fragments big enough to permit internal fixation. Likewise, arthroscopic excision of small symptomatic fragments is feasible.

In the immediate postoperative period, fractures will be immobilized with a below-knee plaster splint. Rehabilitation will commence once soft tissues have healed. Weight-bearing will be

Figure 10: Dual plate fixation of a comminuted talar neck fracture through a dual approach.



gradually initiated once there is clinical and radiological evidence of consolidation, typically not occurring before 6 weeks.

## 3.4. Outcomes and complications

The most typical complication is osteonecrosis, occurring in approximately 50% of Hawkins III and IV fracture cases. It is also more frequent in open fractures. However, the most prevalent complication is post-traumatic osteoarthritis, which affects 100% of these fractures and is also highly incident in body fractures.

## 4. Calcaneus fractures

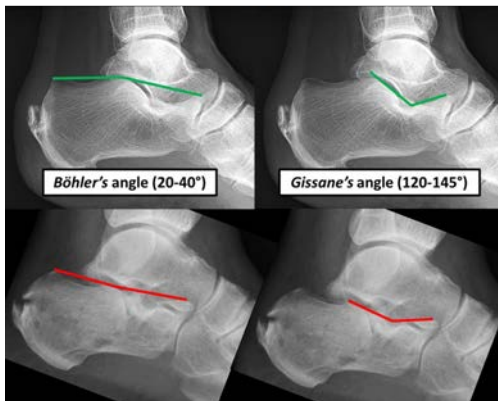
### 4.1. Introduction

Calcaneus fractures are the most common fractures of the tarsus, accounting for 1-2% of all fractures. 75% occur due to high-energy axial loading mechanisms (such as falls from great heights and motor vehicle accidents), often associating joint involvement, comminution, and severe soft tissue damage, as well as injuries in other bodily locations. Extra-articular fractures typically result from twisting or avulsion mechanisms, including stress injuries seen in athletes. Tongue-type fractures can produce inside-out decubitus on the overlying skin, requiring immediate reduction and fixation, which can often be performed percutaneously. Up to 10% of calcaneus fractures may be associated with compartment syndrome.

## 4.2. Diagnosis

The medical history will focus on identifying risk factors associated with poor prognosis, including the detection of potentially non-compliant individuals, which will impact therapeutic decisions. Initial imaging evaluation typically requires AP, lateral, and oblique X-ray views of the foot. In the lateral view, Böhler and Gissane angles are defined, which are affected in depression fractures (Figure 11). The standard axial view may be useful for identifying fractures in the tuberosity. The **Broden's view** is a specialized view at varying cephalic angles that examines the large posterior calcaneal facet and the subtalar joint, with its utility primarily intraoperative. Currently, as with any complex articular fracture, a CT scan is essential for decision-making in calcaneus fractures.

Figure 11: The Böhler and Gissane angles are disrupted in depressed calcaneal fractures. Top: normal images. Down: fractures.



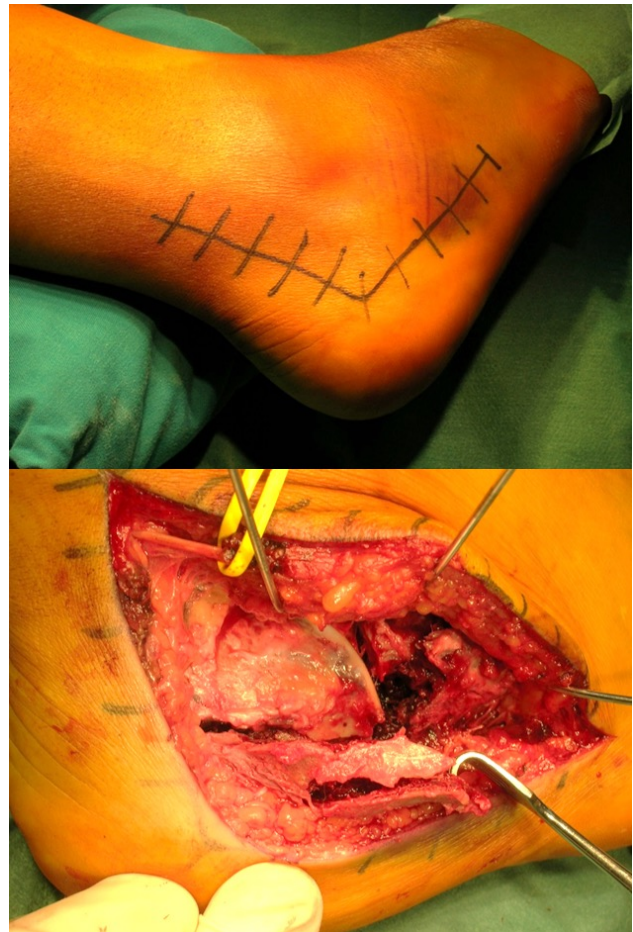
For **articular fractures**, the most commonly used classification is that proposed by **Sanders**. Its foundation lies in determining the number of articular fragments observed on the coronal CT image at the widest point of the posterior facet: type I for nondisplaced fractures, type II for two fragments, type III for three, and type IV for more than three (comminuted). The AO/OTA and Essex-Lopresti classifications are less frequently used.

## 4.3. Treatment

**Nonoperative treatment** is indicated in nondisplaced fractures (Sanders type I), in patients with risk factors such as diabetes, chronic smokers, and peripheral arterial disease, as well as in noncompliant patients or those with prolonged contraindications for surgery due to soft tissue damage or systemic compromise resulting from multiple trauma. Weight-bearing will be limited for a period of approximately 3 months. Physical therapy and range of motion will commence as soon as soft tissue status permits.

The goal of **surgical treatment** is to achieve anatomical restoration of the subtalar joint and calcaneal shape, promoting proper biomechanics of the hindfoot. Initially, a well-padded splint and elevation are necessary to facilitate soft tissue healing, which may take 2-4 weeks. Surgery can only be scheduled once sufficient improvement of the skin around the fracture is ensured. The preferred approach is the **L-shaped lateral extensile** (Figure 12). It is crucial to handle soft tissue with utmost care, elevating a full thickness flap. A series of Kirschner wires will be used as retractors to prevent breakdown of wound margins. Many specific plates are available, and it may be necessary to graft bone defects.

Figure 12: Extensile L-shaped lateral approach to the calcaneus.



In patients with compromised baseline profile or soft tissues requiring reduction and fixation, reduction via mini-open approach and stabilization with percutaneous implants, mainly Kirschner wires and cannulated interfragmentary screws, may be considered.

Primary arthrodesis is an option for the most highly comminuted fractures (Sanders IV). It can be technically demanding and typically yields better outcomes when performed following prior fixation. Management by external fixation allows for early weight bearing with minimal injury to the skin. Similarly, in recent years, locked intramedullary fixation of calcaneus fractures has been described.

## 4.4. Outcomes and complications

Outcomes are correlated with the accuracy of reduction and the severity of the injury. Up to 40% of patients experience complications, with 25% experiencing wound-related complications and infections in open reductions. Another typical complication is nonunion or avascular necrosis of the posterior fracture lines. Frequent long-term complications include calcaneal valgus malunion, leading to gait abnormalities and impingement of the peroneal tendons, and post-traumatic subtalar osteoarthritis.

## References:

1. Buckley RE, Moran CG, Apivatthakakul T (2018). *AO Principles of Fracture Management 3rd edn*. Thieme.

2. Tornetta P, Ricci W, Court-Brown C, McQueen M, McKee M (2019). *Rockwood and Green's Fractures in Adults*, 9th edn. Wolters Kluwer.
  3. Wiss D (2012). *Master Techniques in Orthopaedic Surgery. Fractures*, 2nd edn. Wolters Kluwer.
  4. Sannard JP, Schimdt AH (2015). *Surgical Treatment of Orthopaedic Trauma*, 2nd edn. Thieme.
  5. Simon RR, Koenigsknecht SJ (2007). *Emergency Orthopaedics: The Extremities*. 5th edn. McGraw-Hill.
  6. Toth MJ, Yoon RS, Liporace FA, Koval KJ (2017). What's new in ankle fractures. *Injury* 48(10):2035–41.
  7. Pflüger P, Braun KF, Mair O, Kirchhoff C, Biberthaler P, Crönlein M (2021). Current management of trimalleolar ankle fractures. *EFORT Open Rev* 10;6(8):692–703.
  8. Tomás-Hernández J (2017). High-energy pilon fractures management: State of the art. *EFORT Open Rev* 13;1(10):354–361.
  9. Vallier HA (2015). Fractures of the Talus: State of the Art. *J Orthop Trauma* 29(9):385–92.
  10. Allegra PR, Rivera S, Desai SS, Aiyer A, Kaplan J, Gross CE (2020). Intra-articular Calcaneus Fractures: Current Concepts Review. *Foot Ankle Orthop*. 2020 Jul; 5(3).
- a. Transyndesmotic fibula fracture and oblique medial malleolus fracture.
  - b. Suprasyndesmotic comminuted fibula fracture and deltoid complex avulsion.
  - c. Maissonneuve fracture with posterior syndesmosis injury.
  - d. Dupuytren fracture without posterior syndesmosis injury.
  - e. None of the above.
5. 40 days after a talar neck surgery, the patient comes to your visit. On the control X-Ray you see a radiolucent line immediately under the talar dome. What needs to be done?
- a. MRI to rule out avascular necrosis.
  - b. Tibiotalar fusion, as it is a sign of chondral damage.
  - c. It is a poor prognostic sign. The weight-bearing has to be delayed until the 6th postoperative month.
  - d. Continue normal follow-up.
  - e. Inject cortisone and see the patient in two weeks.
6. Definitive open reduction and internal fixation of a pilon fracture is not indicated in which of the following circumstances?
- a. Unbroken blisters around ankle in absence of any skin wrinkling
  - b. Articular fragments with a gap >3mm
  - c. Articular fragment with a step >1mm
  - d. Varus malalignment at the tibia fracture
  - e. Presence of die-punch central fragments

## Questions

1. Which of the following measures is the least appropriate when initially dealing with high-energy pilon fractures?
  - a. Delta frame.
  - b. Spanning external fixation.
  - c. CT scan.
  - d. Fibula fixation.
  - e. Debridement and irrigation of open wounds.
2. A 65-years-old obese, diabetic and smoker woman arrives at the emergency department with a history of limping after a fall 3 days ago. On the examination, the ankle is swollen and unstable, but there's no pain. The X-Ray shows a transyndesmotic displaced fibula fracture with great opening of the medial clear on weight-bearing images. Which of the following treatment strategies is incorrect?
  - a. Percutaneous reduction and fixation of fibula using a rod.
  - b. Posterolateral approach and fibula fixation with plate and screws.
  - c. Lateral approach and fixation with plate and 2 syndesmotic screws.
  - d. Conservative treatment with long cast for 8 weeks
3. A 75-years-old lady comes to your emergency department after a twist on the foot when going down stairs. On the clinical examination, you palpate increased pressure on the upper part of the heel and discoloration of the surrounding skin. The lateral X-Ray shows a tongue-type fracture of the calcaneus. Which is the best treatment option?
  - a. Emergent surgical reduction and fixation.
  - b. External fixation.
  - c. Splinting and delayed surgical treatment.
  - d. Lateral approach when the swelling disappears.
  - e. Primary subtalar fusion.
4. According to the Lauge-Hansen classification of ankle fractures, which of the following description coincides with a pronation-external rotation stage IV fracture?

## Answers

1d, 2e, 3a, 4c, 5d, 6a.







*Prof. Mehmet Demirhan*

Koc University, School of Medicine Department of Orthopaedics and Traumatology - Istanbul, Turkey

*mdermirhan@ku.edu.tr*

*Dr. Olgar Birsell*

Koc University - Istanbul, Turkey

**Fractures: Shoulder, Arm, Elbow & Forearm**

## 1. Clavicle Fractures

The clavicle is the only bony bridge between axial and the appendicular skeleton. It maintains the distance of the arm to the body as a strut, contributes to shoulder motion and protects the subclavian neurovascular sheath <sup>(1)</sup>.

Clavicle fractures comprise 5-10% of all fractures and 35% to 40% of all shoulder girdle fractures <sup>(4)</sup>. Majority of the fractures (80%) are in the midshaft region. The most common cause is a lateral blow to the shoulder as in falls over outstretched hand; direct blow over the clavicle is relatively rare. Clavicle fractures may be accompanied with pneumothorax, rib fractures, neurovascular injuries, scapulothoracic dissociations in high energy trauma patients <sup>(1)</sup>.

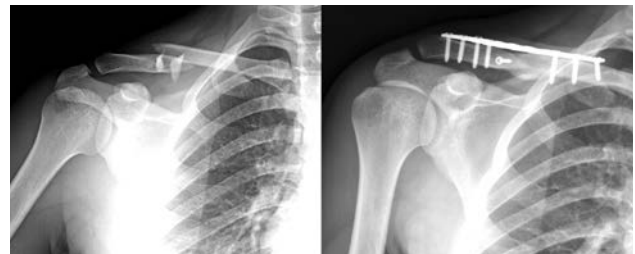A recent registry data revealed a 67% increase in the incidence of clavicle fractures, and a seven-fold increase in the rate of surgically treated clavicle fractures from 2001 to 2012 <sup>(8)</sup>.

Laying right beneath the subcutaneous tissue and with a poor muscle envelope, the clavicle is prone to direct blow traumas. Distally, the clavicle participates in a functional unit called superior shoulder suspensory complex (SSSC) which is consisted of glenoid neck, acromion, coracoid process and acromioclavicular joint and coracoclavicular ligaments. This is a dynamic unit that maintains the stable relationship between axial skeleton and upper extremity. The fractures of the clavicle jeopardize this functional ring since a second structure that fails along with the clavicle results in an unstable injury, referred as double disruptions of the SSSC <sup>(12)</sup>.

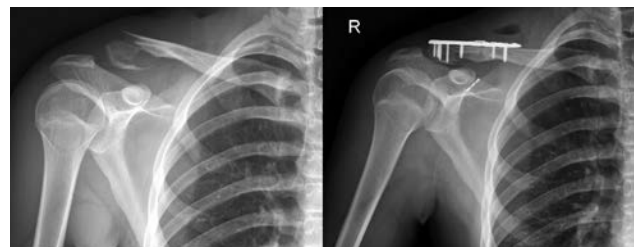The anteroposterior X-ray is almost always sufficient for diagnosing a clavicle fracture, but an additional projection is reported to have changed the treatment strategy in 33.9% of midshaft fracture cases. Particularly a 15 degree caudocranial projection is suggested to have increased the choice of surgical treatment <sup>(5)</sup>.

The Allman classification is a simple anatomical classification system that divides the bone into three parts, proximal-mid-third-lateral, and lateral part fractures are further evaluated by Neer's classification system based on the integrity of the coracoclavicular (CC) ligament.

Minimally or non-displaced fractures of the distal clavicle are treated successfully with immobilization. The surgical treatment of distal clavicle fractures depends on the fragment size and the deforming forces that apply on these fragments (Figure 1). Types II and V fractures, according to Neer classification, are especially exposed to deforming forces and are known to be unstable. Surgical treatment is indicated particularly for type II in which non-union is more common. Discontinuity of coracoclavicular ligaments requires



*Figure 1: Midshaft fracture of the clavicle treated with open reduction and plate fixation. A lag screw is utilized to establish interfragmentary compression.*



*Figure 2: A distal clavicular fracture type IIB, which occurred between the conoid and the trapezoid ligaments. The patient is treated with a distal clavicular plate along with the endobutton technique for the reinforcement of the ruptured conoid ligament.*

coracoclavicular fixation via sutures or screws. Several techniques have been described such as hook plates, figure of eight wiring with pins, coracoclavicular (CC) loop and combined techniques (Figure 2) <sup>(6)</sup>. CC loop technique is reported to be superior to the hook plate in a recent retrospective study. The complications related to the hook plate alone are peri-implant fracture, subacromial osteolysis and impingement syndrome.

Recently, excellent mid term results have been reported for arthroscopic single tight rope technique for the fixation of Neer type II distal clavicle fractures <sup>(1, 2)</sup>. Despite several modifications to the original technique described by Pujol <sup>(3)</sup>, the arthroscopy assisted method is based on the restoration of the vertical stability, through reconstruction of the coracoclavicular ligament complex <sup>(4)</sup>. Although being technically demanding, the minimal invasive method provides good stabilization with less complications without requiring implant removal (Figure X).

Identifying the patients who will benefit from operative treatment remains challenging for midshaft fractures. Nonsurgical treatment is incontrovertibly appropriate for minimally or nondisplaced fractures of middle third clavicular fractures. A broad arm sling is suggested to be superior to the figure of eight bandage in early pain control and ease of application <sup>(3)</sup>.

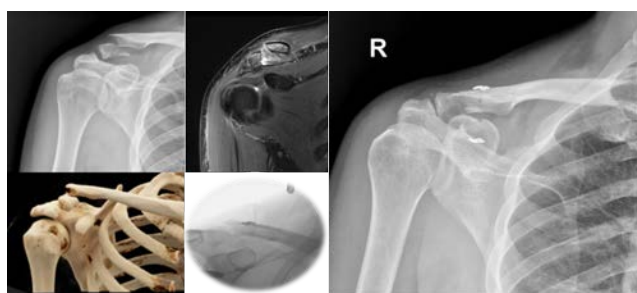

Figure 3: Radiological images depicting preoperative Xray, CT and MRI to a patient with Neer Type IIB distal clavicle fracture with peroperative fluoroscopic image and a postoperative Xray. Note that the reduction is established through the restoration of coracoclavicular distance.

When it comes to displaced fractures, a very recent meta-analysis revealed that the plate fixation for the midshaft fractures dramatically lowers the non-union rate but does not provide any significant clinical advantage at the final functional outcome. However, plate fixation is suggested to be a better option for patients prone to non-union such as comminuted fractures or smokers and for the patients with superior expectations such as quick recovery or optimal arm function<sup>(14)</sup>. In a multicenter randomized controlled trial Jensen et al suggested that plate and locking screws provide faster functional recovery and a higher rate of union, even if the shoulder functions equal at the sixth month and at the first year<sup>(11)</sup>. Moreover, the operative treatment of displaced midshaft fractures is suggested to be more cost effective if the clinical benefit lasts more than 3 years<sup>(9)</sup>. Traditionally, patients with concomitant neurovascular injuries, multiple trauma, floating shoulder, 100% displacement, skin irritation by fragments, comminuted fractures and more than 15 mm of shortening are considered for the surgery (Figure 1)<sup>(1)</sup>. High percentage of non operative treatment is recently questioned with a new perspective of scapulothoracic abnormal motion. Emerging data suggest that even 8% of shortening can have a functional impact on scapulothoracic harmony. These factors should also be considered when weighing the risks and benefits of immediate repair versus delayed reconstruction (delayed or acute). marginally inferior outcomes in terms of shoulder muscle endurance and in surgeon based outcome scores have been reported with delayed surgery<sup>(10)</sup>. Several techniques are described for the internal fixation of the midshaft fractures. Superior and anterosuperior locking plating is reported to offer more favorable biomechanical properties than anterior plating. However, the anterior plating is known to be a safer approach with lower rates of vascular injury<sup>(13)</sup>. Various intramedullary fixation methods have been described and reported to have successful outcomes<sup>(2)</sup>.

Conservative treatment will usually be adequate for medial third fractures of the clavicle. Plate fixation can be advocated for displaced fractures with maximum care to the central vascular structures lying right beneath. Free pins that tend to migrate must be avoided.

Multiple disruptions of the SSSC require surgical intervention in order to stabilize the ring either to the clavicular or to the scapular sides.

As a subcutaneous bone with a poor muscle envelope and very limited vascularity (no nutrient artery, only periosteal), the clavicle is prone to complications. In a large recent series, a 12.2% of major complication rate is reported<sup>(4)</sup>. Neurovascular injury is rare and the risk is even lower with anterior plating<sup>(7)</sup>. The overall reoperation rate

for hardware removal is 1/3<sup>(4)</sup>.

Non-union or delayed union are relatively common complications of conservative treatment. Infections, non-unions, damage to the neurovascular structures are among the major postoperative complications. A prominent plate in thin patients that become sensitive is the most common cause of implant removal<sup>(2)</sup>. Smoking is identified to be the only risk factor to increase the failure rate in a recent series<sup>(4)</sup>.

## 2. Scapular fractures

Fractures of the scapula are rare, comprising less than 1% of all fractures<sup>(1)</sup>. Approximately 90% result from high energy injuries such as motor vehicle accidents and 12.5% of the scapular fractures are reported to be missed or remain out of focus along with life threatening injuries, such as hemothorax and pneumothorax. Concomitant ipsilateral clavicular fractures are common (19%) and must be ruled out. The most common fracture site, in a large series in the literature, was scapular body with 52%, followed by glenoid fossa with 29% and processes (11%)<sup>(17)</sup>. Scapular body fractures occur predominantly in men (M/F: 5.2/1) whereas neck fractures do not differ in gender.

A broad arm sling is applied in the emergency room in order to immobilize and to avoid further damage until the exclusion of major thorax trauma<sup>(16)</sup>. Neurovascular examination is essential due to the close proximity and the overlaying skin must be evaluated for abrasions or open wounds.

Shoulder trauma radiographs are the first line of investigation, however three dimensional CT is almost always necessary for visualizing the fracture configuration.

### 2.1. Body fractures

Majority of scapular body fractures can be managed non-operatively, owing to be splinted internally by the strong musculature. The treatment is tailored according to the degree of displacement and the patient's expectations<sup>(15)</sup>. Functional outcomes, usually satisfying, can be followed up with external rotation tests in the site that is primarily affected<sup>(16)</sup>.

### 2.2. Glenoid Fractures

Glenoid fractures comprise approximately 10% of scapular fractures<sup>(18)</sup>. Anterior avulsion or rim fractures predominate and the most common mechanism of injury is shoulder dislocation. The impaction of the humeral head on the glenoid fossa can occur as a result of a high energy trauma.

Three dimensional CT images of the glenoid after the humerus has been digitally subtracted, are the gold standard images for the diagnosis and the primary factor that switches the flow of the treatment algorithms.

The majority of glenoid fractures can be successfully treated conservatively. The fractures of the glenoid surface must be addressed surgically if the displacement is larger than 5 mm. to avoid glenohumeral joint congruity, whereas, glenoid rim fractures are evaluated based on glenohumeral joint stability<sup>(15)</sup> (Figure 3).

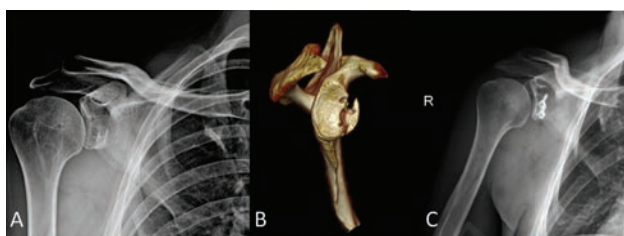


Figure 3: 32-year-male patient. Arthroscopic anterior shoulder stabilization, ski accident and right shoulder fracture dislocation 3 years before; AP Radiograph (A) and 3D computerized tomography, with digitally subtraction of the humerus (B) of the anterior glenoid rim fracture of a trauma patient. (C) Early postoperative radiograph of the patient who underwent an open reduction and plate fixation using a "Latarjet plate" as a buttress plate, to avoid the displacement of the large fragment.

## 3. Proximal humeral fractures

### 3.1. Introduction

The fractures of the proximal humerus consist of 5% of all adult fractures<sup>[33]</sup>. It is the third most frequent fracture site in the elderly following wrist and proximal femur<sup>[31]</sup>. A recent study of a large cohort suggested a higher prevalence in women, an increased incidence with older age and during the winter months<sup>[33]</sup>. Particularly, valgus impacted fractures are prevalent in osteoporotic elderly with low energy indoor injuries<sup>[19]</sup>.

### 3.2. Anatomy and biomechanics

Four different anatomical parts can be identified on proximal humerus, namely the head, diaphysis, greater and lesser tuberosities. Periscapular muscles attach onto these different parts, coupled as agonists and antagonists, in order to create a perfect equilibrium that maintains the humeral head right in front of the glenoid. The concept of fracture lines that separate these parts following the insertions of periscapular muscles is first propounded by Neer<sup>[30]</sup>. Moreover, the muscles' pull is also implicated as the deforming forces to be addressed in reduction methods. In that purpose, suture fixation of rotator cuff tendons to the proximal humerus plate enables the control of the attached fragments, facilitating the anatomical reduction and neutralizing the deforming action of RC muscles during the osteosynthesis.

The major blood supply of humeral head and greater tuberosity is provided by the arcuate artery of Liang, a branch of anterior humeral circumflex artery. Posterior circumflex artery also contributes to the vascularity of the head and tuberosities. Fracture patterns that involve these structures compromise the blood supply and result in the avascular necrosis of the fragments<sup>[27]</sup>. A recent study has investigated the fracture line morphology on three dimensional CT and reported an intra-capsular fracture incidence as high as 68%<sup>[26]</sup>. Considering the insertion point of the joint capsul only 3 to 4 mm distal to the articular cartilage, a majority of the fractures carry the risk of avascular necrosis.

### 3.3. Clinical presentation

Severe pain, particularly during active and passive joint motion predominates the scene. A large ecchymosis over anteromedial humerus may be present in subacute cases, and is suggestive of an

underlying fracture. Neurological and vascular involvement should be evaluated in high energy traumas as well as bone mineral density for the patients with low energy injuries<sup>[29]</sup>. Vascular injuries are more likely in association with fracture dislocations and, distal ischemia can be clouded by rich collateral circulation. Digital subtraction angiography is the most reliable investigation in the presence of large expanding haematoma, pulsatile bleeding, unexplained hypotension and coexisting plexus injury (Figure 6). Neurological insult can manifest as axillary nerve compression due to a fracture dislocation or a tractional injury of the brachial plexus.

Shoulder trauma series radiographs are the first line investigation of a suspected patient, including true AP, axillary (if possible) and scapular Y views. Computerized tomography (CT) with three dimensional reconstruction is essential to evaluate the fracture pattern and to rule out associated injuries such as glenoid fractures. The magnetic resonance imaging has limited indications in selected patients, such as assessing rotator cuff or capsulolabral integrity in fracture-dislocation cases.

### 3.4. Classification of proximal humeral fractures

The proximal humeral fractures are classified in order to evaluate the surgical indication and to predict the potential of healing through the viability of the various fragments and based on the fracture pattern<sup>[36]</sup>. The 4-segment system first described by Neer, that has been used worldwide, focuses on displacement of segments rather than fracture lines. The displacement of a fragment is recognized when there is more than 1 cm of displacement or more than 45 degrees of angulation. In the binary system developed by Hertel, the 4 parts that constitutes proximal humerus are regrouped to enlist the possible configurations<sup>[27]</sup>. Valgus impacted Neer type 4 fractures consist of a special subgroup that requires particular interest<sup>[19]</sup> (Figure 4). A novel concept of a pattern based classification has been recently introduced by Mayo Clinic and the Fundación Jiménez Díaz including seven common fracture patterns. The Mayo-FJD classification scheme has been validated with adequate intraobserver and interobserver agreement and has become prevalent as an easy and comprehensive method.

### 3.5. Conservative treatment

A majority of proximal humerus fractures have a stable configuration and can be managed non-operatively<sup>[29,31]</sup>. However, frequent radiographic evaluation of the alignment is necessary until the callus formation is documented around the fourth week. Recently, a multicenter randomized controlled study evoked substantial reaction due to its contradictory deductions concerning surgical indications of displaced fractures. However, this study was criticized in many ways because of its vague exclusion criteria, lack of standardization, absence of a major treatment group and utilization of patient reported outcomes<sup>[34]</sup>. Metaanalyses reporting similar outcomes along with 3.3 times higher complication rate for the surgical treatment must be interpreted with caution considering the high risk of bias in the included studies.

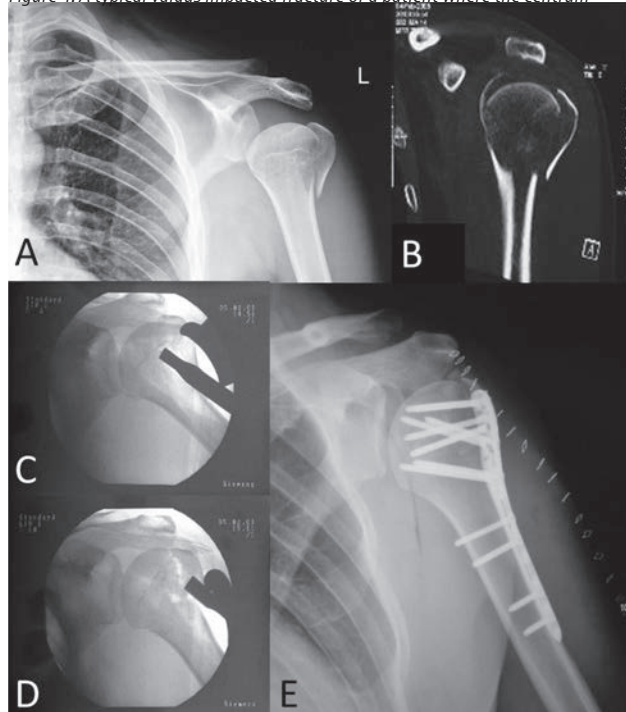
Moreover, a recent retrospective comparative study opposed the latter reporting better functional outcomes with reverse shoulder arthroplasty treatment of proximal humeral fractures with 3-part or 4-part displaced fractures in elderly<sup>[23]</sup>

A recent randomized controlled study reported that in patients



with impacted osteoporotic fractures, the aggressive and conventional regimens at the first phase of rehabilitation have similar outcomes of shoulder functions<sup>(21)</sup>. Passive range of motion exercises are safe to start immediately (at the first week) and continued as long as the shoulder is not painful. Active assisted exercises such as overhead elevation with pulley and stick along with self-assisted closed chain exercises are initiated following the radiographic documentation of callus formation. Conservative management of displaced and multi-part fractures should be reserved for very elderly, cognitively-impaired, highly comorbid and osteoporotic patients. Non-union, symptomatic malunion and osteonecrosis are three major complications of conservative approaches<sup>(29)</sup>.

Figure 4: A typical valgus impacted fracture of a patient where the centrum



collum diaphyseal angle is diminished (normally approx: 135°) and humeral articular surface faces upwards (A). Sagittal image showing the head collapsed between the tubercles (B). Under fluoroscopic imaging, the head collapses is elevated through an anterolateral window without compromising the intact medial hinge, and supported with structural allografts (C and D). Finally the fixation of the system is established with a proximal humerus locking plate.

### 3.6. Surgical Approaches

Deltopectoral approach is the most commonly used way to reach the shoulder. Cephalic vein is compromised and should be identified and preserved. Biceps tendon groove and coracoid process are the benchmarks. The incision can be expanded distally as an anterolateral approach to the humerus.

Deltoid splitting approach grants a better visualization of the greater tubercle and posterior of the humeral head. Axillary nerve traversing the field horizontally at approximately 5 cm to the acromion limits its distal expansion. We do not recommend utilization of this approach which severely jeopardizes the axillary nerve.

Posterior approach is occasionally used to reach posterior structures in trauma cases. Infraspinatus can be splitted or detached for arthrotomy.

### 3.7. Surgical treatment

Surgical treatment of proximal humerus fractures comprises osteosynthesis and arthroplasty. The decision making is remarkably multifactorial and should be tailored for each patient. Age, level of activity and functional expectations are patient-related parameters, whereas fracture configuration, viability of the humeral head, quality of the bone, the complexion of the cartilage and rotator cuff tendons are parameters related to the fracture. Displaced two-three-or four-part fractures and valgus impacted fractures require plate fixation, and displaced four-part varus fractures, fracture dislocations and head-split fractures of the elderly are considered for arthroplasty<sup>(29)</sup>.

As for all trauma cases, preoperative planning improves the results of surgical management. Computer assisted virtual surgical technology and three-dimensional (3D) printing technology are currently available, and virtual surgical technologies are proven to be more convenient and efficient with shorter time of planning and more accurate in the achievement of the planning<sup>(22)</sup>

Minimally invasive percutaneous reduction and fixation is a technically demanding method that has been discredited in the last decade, due to the concerns of fixation stability. With recent technological improvements, this technique regained a certain workspace particularly in elderly patients with poor bone quality. Minimally invasive reduction of the fragments is challenging and requires a thorough understanding of the fracture configuration and deforming forces<sup>(31)</sup>. In cases where anatomical reduction and fixation is impossible due to extreme comminution, the minimal invasive methods should be considered. The complications and the outcomes of MIPO are comparable with open techniques, if the radial nerve is explored and protected adequately. (figure X)

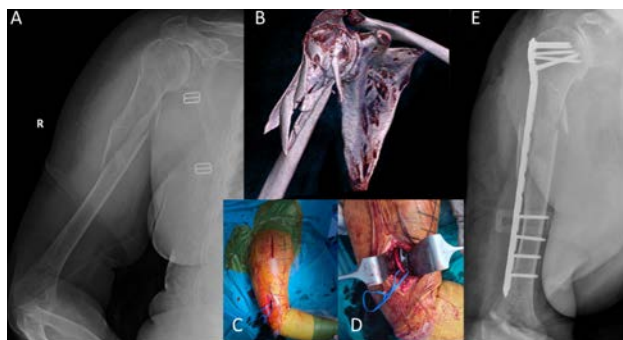


Figure X: (A) Major comminution prohibits open anatomical reduction and fixation of the multiple fragments. (B) CT Scan of the patient demonstrates the comminution (C) Minimal invasive locking plate is inserted using bridging plate technique. (E) 3 months postoperative x-rays demonstrated healing and acceptable alignment.

Proximal humerus locking plate became an eminent fixation method following recent innovations in its surgical approach, technique and implant design. In patients with lower bone density, the stability of the locking plate is reported to be superior to the conventional plating techniques<sup>(29)</sup>.

Deltopectoral approach is the favorable approach and the biceps groove is a reliable benchmark since fracture lines almost never include this anatomical landmark<sup>(32)</sup>. The recommended position of the plate is lateral to the bisipital groove and 5 mm. distal to the tip of major tubercle, in order to avoid head penetration and for the optimal insertion of the crucial calcar screw<sup>(32)</sup>. Considerable impaction of the head occurs in Neer type 4 valgus impacted fractures and requires autografting if disimpaction is necessary to



restore the alignment<sup>(19)</sup>. Inadequate filling of the cavity, and thus failing to support the head, is reported to be the cause of major complications in all osteosynthesis techniques. Independent of whether harvested autografts or structural allografts have been preferred, only cortical grafts can provide structural support.

Promising results of the third generation intramedullary nails were reported by Boileau et al, for the treatment of 2-part surgical neck fractures. The authors suggest that if the optimal entry point is chosen according to the valgus or varus deformity of the head fragment, there would be no cartilage damage or rotator cuff tendon morbidity<sup>(22)</sup>.

Prosthetic replacement in a fracture setting is technically demanding. The position of the tuberosities are suggested to be related with the results, as lateralization improves the outcomes while distal transfer can be detrimental<sup>(24)</sup>. Reverse shoulder arthroplasty is the best option for comminuted fractures in the elderly with concomitant rotator cuff deficiency<sup>(25,37)</sup>. In high demand younger patients, hemiarthroplasty must be reserved for the patients in whom it is impossible to achieve an acceptable anatomical reconstruction, or severe comminution warrants osteonecrosis of the fragments<sup>(31)</sup>. In these cases, meticulous anatomical reconstruction of the tuberosities is essential, as a primary determinant of the outcomes (Figure 5)<sup>(37)</sup>. Recently Koeppe et al reported that the primary reverse shoulder arthroplasty has more favorable outcomes than a revision in the setting of a failed osteosynthesis in elderly. This study emphasizes the importance of adequate evaluation of the prognostic factors for the osteosynthesis in elderly patients, as well as the correct identification of the fracture configuration.

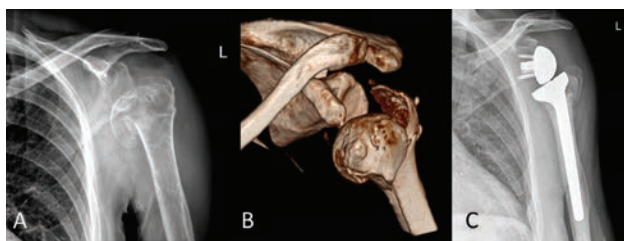

Figure 5: (A) Radiograph and (B) 3D CT image showing a head split fracture of a 78-years-old female patient, treated successfully with a reverse shoulder arthroplasty. Note the anatomical restoration of the tuberosities (C).

### 3.8. Fracture dislocations

It is not uncommon that a greater tuberosity fracture complicates an anterior shoulder dislocation in elderly. The reduction should be attempted under general anaesthesia and through gentle tractions and manoeuvres. If surgical neck fracture is suspected, open reduction may be advocated following its confirmation with a CT. Overlooking of such an occult fracture may result in iatrogenic displacement of the humeral head into the axilla, ensuring the need of an arthroplasty<sup>(31)</sup> (Figure 6).

### 3.9. Complications

Hertel indicated a calcar length shorter than 8 mm, a disrupted medial hinge and a basic fracture pattern as good predictors of ischemia and thus a less favorable outcome<sup>(27)</sup>. Although Neer type 3 and type 4 fractures are prone to avascular necrosis, valgus impacted fractures are more resistant to this detrimental

complication owing to well preserved integrity of medial calcar.

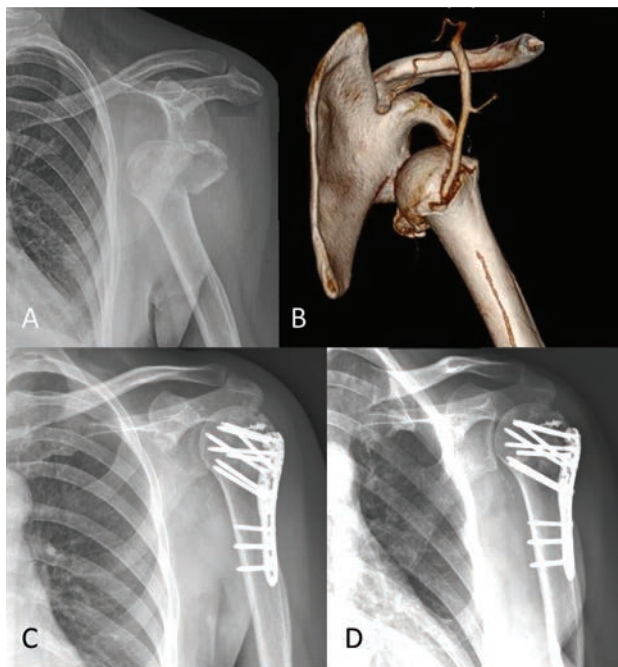


Figure 6: (A) Radiograph showing a fracture dislocation of a female patient whose assessment revealed an acute disturbance of circulation in the affected extremity. CT angiography (B) revealed axillary artery entrapment into the fracture site. The patient underwent open reduction immediately, vascular repair and her fracture is fixed with a proximal humerus locking plate along with an open repair of her rotator cuff tendons (C, D).

The most common early complication of locking plates is screw penetration with an incidence up to 23%. The screw length may be measured inaccurately during the operation or more often, a correct length screw may protrude following the collapse of the humeral head. A combination of four projections, especially an axial view with 30° of abduction is suggested to be necessary for early diagnosis of screw cut-outs<sup>(35)</sup>. Subacromial impingement of the implant, fixation loss and infections are among other complications.

Failure of fixation rates for patients older than 60 years are reported to be as high as 20%. Reverse shoulder arthroplasty is suggested to be a valuable salvage procedure in these patients to improve shoulder function and pain levels<sup>(25)</sup>.

Restriction of range of motion and degenerative changes on the glenoid are major complications of the hemiarthroplasty. Infections seem to occur more often in reverse shoulder arthroplasty and its larger intraarticular space is accused of being a predisposing factor.

## 4. Humerus shaft fractures

Diaphyseal fractures of the humerus comprises 3% of all adult long-bone fractures and most commonly occur in the middle third<sup>(42)</sup>. Humerus shaft fractures manifest as a bimodal distribution with high energy traumas in young patients and lower energy fractures in elderly osteoporotic individuals. Humerus is the second most common long bone affected by metastatic bone disease, particularly arising from breast, kidney, thyroid, lung, prostate and multiple myeloma<sup>(40)</sup>.

Clinical evaluation reveals a painful deformity, usually as shortening and varus due to the deforming forces of the muscles. The skin is examined for an open fracture and distal pulses are evaluated to rule out a vascular insult. The neurological examination is performed with a particular focus on the radial nerve, and a deficit is noted prior to any further treatment. Adjacent joints are carefully assessed for a concomitant injury.

Standard AP radiography and the transthoracic lateral view is acquired. Forceful external rotation and abduction in order to obtain a lateral X-ray risks further nerve and soft-tissue damage. Standard radiographs of the adjacent joints should also be acquired as per the rule 'joint above and joint below'. Advanced imaging is required only when there is suspicion of an intraarticular extend or a pathological fracture.

The classification of the Orthopaedic Trauma Association (OTA) is widely accepted and reported to have a moderate interobserver and a substantial intraobserver agreement for fracture types and groups <sup>(39)</sup>.

When treating humeral shaft fractures, the primary objective is to achieve union with an acceptable alignment and to restore the functions of the extremity. The limits of an angular and rotational deformity that does not compromise the function are determined by Klenerman. Accordingly, 20 degrees of anterior and 30 degrees of varus deformities are later expanded by the addition of 30 degrees of valgus, 15 degrees of rotation and less than 3 mm of shortening as the limit radiographic criteria for an acceptable alignment. Later, Sarmiento introduced his functional brace as a treatment method that maintains joint motion while stabilizing the fracture and reported very favorable outcomes <sup>(41)</sup>. Non-operative treatment is initiated with a coaptation splint used for 7 to 10 days which is later replaced with a functional brace until the healing is documented. Close radiological follow-up is necessary to ensure

the maintenance of the alignment.

Operative indication should be considered when an acceptable alignment cannot be achieved with functional bracing <sup>(42)</sup>. Moreover, severe soft-tissue injuries associated with open fractures or wide areas of skin problems that precludes bracing, fractures with an intraarticular extend, pathological fractures, segmental fractures, brachial plexus injuries and radial nerve injury following manipulation, are treated surgically. The most common surgical treatment method for diaphyseal humerus fracture is open reduction and plate fixation with a very high union rate and low infection and iatrogenic nerve injury incidences (Figure 7). The fracture site is usually approached laterally for midshaft and posteriorly for distal third fractures <sup>(38)</sup>.

We do not recommend the use of intramedullary nailing unless the patient has an unstable segmental or comminuted fractures of the humeral shaft. The length of the bone can be maintained without compromising the blood supply of the fragments. However, the distraction that occurs over the fracture site during implantation and limited compression capability are deterrent factors that limit its indications. Union rates of intramedullary nails are also lower than plate fixation. Shoulder pain after antegrade nailing is an other drawback for its use.

External fixation should be reserved for highly comminuted fractures, infected pseudoarthrosis, burns and severe soft-tissue coverage problems. It can also be indicated in polytrauma patients according to damage control orthopaedics. External fixators are implemented in the treatment of humeral shaft non-unions and are reported to have favorable outcomes similar to plate fixation <sup>(38)</sup>.

Radial nerve lies along the spiral groove with deep humeral artery and the injury of these structures is reported to be from 4% to 22%. Approximately 12.6 cm proximal to the lateral epicondyle, radial nerve exits the spiral groove and passes into the anterior compartment at a 10 cm distance from the distal articular surface <sup>(1)</sup>. This location is where Holstein-Lewis fracture occurs with a potential injury to the nerve <sup>(42)</sup>. Considering the high rate of spontaneous recovery, early nerve exploration is not indicated in cases of radial palsy in closed fractures.

Radial nerve disfunctions are the most troublesome complications of the surgical treatment. Non-unions occur more often with intramedullary nailing, due to instability, avascularity, gap and infection <sup>(1)</sup>.

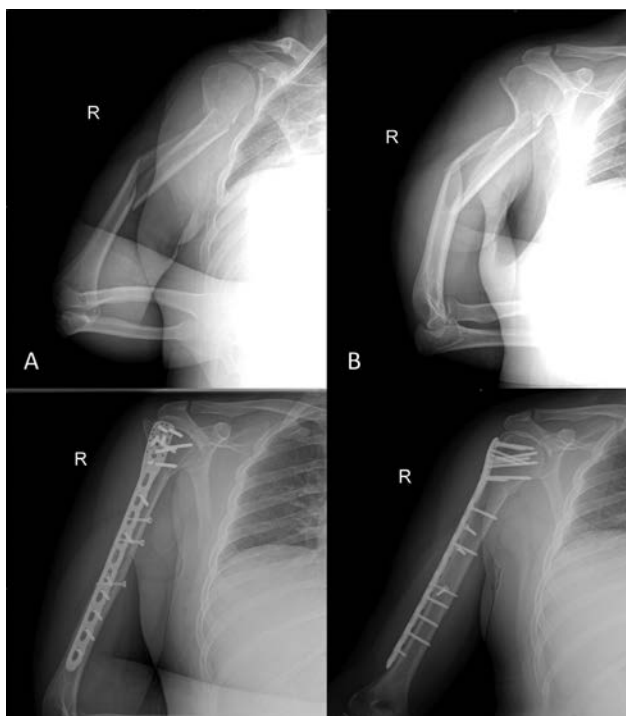


Figure 7: (A and B) Anteroposterior and oblique shoulder radiographs that depict a proximal humerus fracture with a segmented diaphyseal extension. The patient is treated with a long proximal humeral locking plate with multiple interfragmentary screws.

## 5. Distal humerus fractures

### 5.1. Introduction

Two percent of all adult fractures occur at distal humerus and intercondylar fractures are the most common type. The distribution is bimodal with high energy injuries in young adults and usually due to an indoor fall in the elderly <sup>(46)</sup>. The loss of functional range of motion seriously affects the placement of the hand in the space and thus, compromises daily activities. The complex anatomy, poor soft-tissue coverage and frequent comminution renders these fractures difficult to manage <sup>(55)</sup>.

### 5.2. Anatomy and biomechanics

The humerus participates in the elbow joint with a rather amorphous articular surface. Trochlea resembles to a pulley and

accepts the slight ridge of the semilunar or trochlear notch of the ulna to form the elbow hinge. The reconstruction of the spatial position of the articular surface is challenging with an inclination of 30° anteriorly, the frontal plane is tilted into 6° of valgus and the transvers plane is rotated medially about 5°. Articular reaction forces are transferred to the proximal humerus through medial and lateral columns that form the distal metaphysis.

## 5.3. Clinical presentation

The clinical examination focuses on the integrity of the skin to rule out open fractures. Severe pain and diffuse swelling is typically present and measures should be taken to avoid compartment syndrome. Any attempt to move the elbow joint reveals crepitus or gross instability and should not be insisted to prevent further damage to radial and ulnar nerves or brachial artery. Neurovascular status is meticulously assessed since the elbow is a dense crossing of vital structures.

Apart from the standart AP and lateral radiographs, traction radiographs are helpful for the assesment of fracture configuration and possible reduction through ligamentotaxis. Three dimentional computed tomograph is almost always necessary for the evaluation of the articular surface and preoperative planning of complexe fractures <sup>(46)</sup>. A double arc sign is a characteristic radiological finding of a capitellar shear fracture and must be evaluated <sup>(49)</sup>.

## 5.4. Classification of distal humeral fractures

The classification systems for distal humerus fractures are descriptive and based on the fracture location and involment of medial and lateral columns. According to AO classification type A represents extraarticular fractures, type B partially articular and type C complete articular fractures. Jupiter and Mehne described 3 similar grades except that grade 2 is extraarticular but 'intracapsular' and intraarticular fractures are further divided into 4 subgroups: Single column, two-columns, capitellar and trochlear fractures. High rates of interobserver agreement have been reported for the main divisions of these systems, however,

reliability decreases with the identification of the subtypes <sup>(46)</sup>.

Capitellar shear fractures occur when radial head impacts a shear force over the capitellum <sup>(49)</sup>. These fractures are almost always displaced because of a lack of soft-tissue attachment. Bryan and Morrey proposed a descriptive classification for this particular injury, consisting of four types. In type 1 (Hahn-Steinthal) complete capitellar fracture occurs but the trochlea remains intact. Type 2 (Kocher-Lorenz) is an anterior osteochondral fragment with minimal subchondral bone. In Type 3 (Broberg-Morrey) the capitellum is comminuted and in type 4, the fracture line extends medially and includes a large part of the trochlea (Figure 8). Other injuries commonly accompany capitellar fractures such as up to 40% of lateral collateral ligament disruption and 30% radial head fracture <sup>(49)</sup>.

Non operative treatment has a very limited jurisdiction in distal humerus fractures <sup>(52)</sup>. Besides the undisplaced fractures, patients with dementia, active infection, and very severe comorbidities that preclude anesthesia or surgery are managed nonsurgically. Only a modest functional result has been reported with the traditional bag of bones technique, in low-demand elderly when the risk of anesthesia or the surgery is substantial <sup>(43)</sup>. Type 2 capitellar shear fractures can initially be treated conservatively and loose body removal can be planned if the patient becomes symptomatic <sup>(49)</sup>.

## 5.5. Surgical approaches

In cases with severe articular comminution, adequate exposure of the entire distal humerus can be achieved through a transolecranon osteotomy. Exploration of the ulnar nerve is recommended previous to the distally pointing chevron osteotomy and it must be decided whether to anteriorly transpose the nerve. Predrilling and tapping of proximal ulna is suggested to ease the fixation. The olecranon osteotomy is repaired using tension band with Kirschner wires or a 6.5 mm spongiosa screw.

The lateral approach enables direct access to the lateral column and is preferred particularly in the exposure of capitellum shear fractures. Sharp dissection of the extensor wad from the lateral supracondylar ridge (anteriorly) and the triceps (posteriorly) is required.

## 5.6. Surgical treatment

Surgical managemet of intraarticular distal humerus fractures is challenging. The outcomes are multifactorial, where each and every factor can deteriorate the whole such as articular congruity, cartilage loss, traumatized sof-tissue envelope, alignment and fixation stability. Internal fixation with double plates is the gold standard treatment for intraarticular fractures, but the optimal plate configuration is still a point of issue. A recent biomechanical study reported that orthogonal plating provides equal stability to the parallele plating <sup>(45)</sup> (Figure 9).

The principles of the double plate fixation in comminuted distal humerus fractures are described by O'Driscoll <sup>(51)</sup>. We recommend to acknowledge and pursue each and every technical objective he proposed, that clearly enhances the biomechanical stability of the fixation (Table 1).

Osteosynthesis of a comminuted distal humeral fracture in an osteoporotic patient is challenging. Often, they cannot tolerate the immobilization because of an already impaired fonctionnality and various comorbidities. A prospective randomized controlled

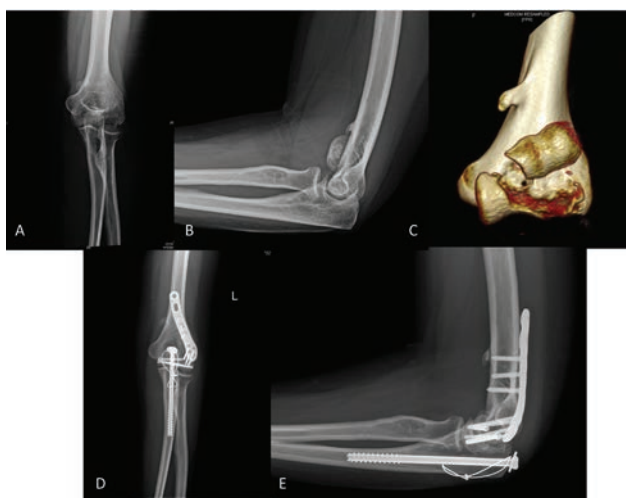


Figure 8: Plate and screw osteosynthesis of a type IV capitellum shear fracture according to Bryan and Morrey Classification. Preoperative AP and lateral radiographs (A, B) and fourth postoperative month radiographs (D, E). A preoperative 3D computerized tomography with digital subtraction of the forearm is showing the fragment that includes capitellum and half of the trochlea.



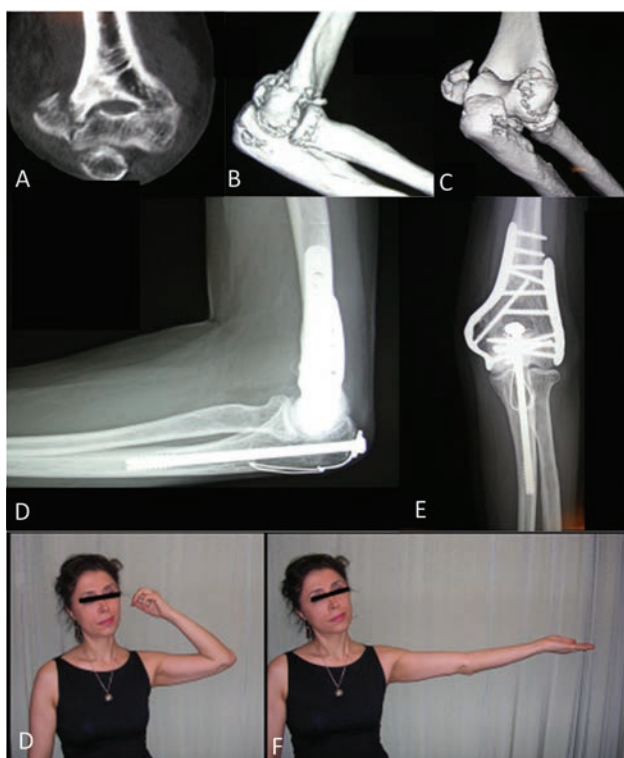

Figure 9: Distal humerus fracture managed with double plating through an olecranon osteotomy. Preoperative radiographs (A) and 3D CT images (B and C), postoperative AP and lateral radiographs (D and E) and clinical images showing the range of motion at the first postoperative year.

study supports the use of total elbow arthroplasty in comminuted fractures of the elderly, with better outcomes scores and a shorter surgical time <sup>(48,50)</sup>. Phadnis et al, reported comparable outcomes following osteosynthesis and elbow hemiarthroplasty for the treatment of complex distal humerus fractures in elderly. High complication rate in ORIF group decreased with proper ORIF technique and patient selection.

## 5.7. Complications

Elbow stiffness, mal or non-union, implant failure, and ulnar neuropathy are commonly encountered complications of the

Table 1: O'Driscoll Distal Humerus Fractures Fixation
1. Every screw that engages a distal fragment should be placed through a plate.
2. Every screw that engages a fragment on the opposite side, that is also fixed to a plate.
3. Place as many screws as possible in the distal fragments.
4. Each screw should be as long as possible.
5. Aim to engage as many articular fragments as possible with each screw.
6. Create a fixed-angle structure with the interdigitation of the screws, locking together the distal fragments.
7. Apply the plates so that compression is exerted onto the supracondylar level for both columns
8. Enable the overall structure strong enough to resist breaking or bending until the union occurs

Table 1. O'Driscoll's technical objectives for fixation of distal humerus fractures

osteosynthesis in distal humerus fractures; overall complication rates are reported to be over 35% <sup>(50)</sup>. In a recent large series the limitation in the elbow range of motion is reported to be very common and AO types C2 and C3, along with a delay in intervention significantly increase the risk for elbow stiffness <sup>(54)</sup>. In cases with implant failure and mal or non-union, total elbow arthroplasty is a very proficient option to restore elbow functions, along with the revision osteosynthesis. Infection in osteosynthesis is relatively rare unless it is a high grade open fracture. Skin irritation has been reported in thin and elderly patients and posterolateral plating can overcome this minor complication <sup>(45)</sup>. Post-traumatic arthritis is a late complication owing to a devastating initial injury or improper restoration of the joint congruity.

Loosening, implant failure and subsequent revision surgery are common complications of total elbow arthroplasty in the osteoporotic bone of the elderly <sup>(43)</sup>.

## 6. Fractures of the elbow

### 6.1. Radial head fractures

Radial head fractures are common and comprise 20% of the fractures around the elbow<sup>(1)</sup>. They may occur in isolation or as a component to a more complex injury such as a collateral ligament injury or a fracture dislocation <sup>(68)</sup>. The most common trauma mechanism is a fall on an outstretched hand while the transmission of the axial load causes a burst fracture of the fovea radialis and results in a rate of comminution as high as 22% <sup>(59)</sup>. Carpal fractures, distal radioulnar joint or interosseous membrane injuries, coronoid fractures, Monteggia fractures, capitellar fractures and collateral ligament injuries are commonly associated with radial head fractures.

Radiocapitellar joint bears 60% of the load that is transmitted through the elbow with maximal load occurring between 0 to 30 degrees of flexion <sup>(64)</sup>. Radial head plays an important part in the forearm articular complex along with the interosseous membrane and the distal radioulnar joint (DRUJ). Radial head contributes to the forearm pronosupination and the elbow hinge through humeroradial joint. It is also involved in the stability of the elbow joint as a secondary valgus stabilizer, along with the stabilization against posterolateral and axial loads <sup>(65)</sup>. Radial head contribution to the valgus stabilization is calculated as 30% in an elbow with intact MCL. If the MCL fails, radial head undertakes 60% of the valgus load <sup>(65)</sup>. Considering that radial head fractures are associated with MCL injuries in 54%, LCL injuries in 80% and both ligament injuries in 50% of the cases, concomitant ligament injuries should be thoroughly evaluated <sup>(62)</sup>.

Essex Lopresti lesion is defined as an association of a severely comminuted fracture of the radial head with the disruptions of interosseous membrane and distal radioulnar joint and it requires particular attention <sup>(66)</sup>. Failure to maintain the length of the radial head will result in proximal migration of the radius and a painful dysfunction of the DRUJ. Thus, it is imperative that all patients with radial head fracture undergo a complete examination of the forearm and the wrist <sup>(60)</sup>.

The patient complains of a sudden sharp pain over lateral elbow and painful pro and supination of the forearm. Localised swelling is palpable on the lateral soft spot of the elbow (triangular area



between olecranon, radial head and lateral epicondyle), implying an haemorrhagic effusion<sup>(1)</sup>. Radial head is painful to palpation and valgus stress. We suggest that the further evaluation of the radiohumeral joint motion and stability should be performed following the aspiration of the haemorrhage and infiltration of local anesthetics. Any sensation of block to prosupination or flexion to extension must be noted. The elbow joint must be carefully examined for the signs of instability and ligament injury. The forearm and wrist should be examined for tenderness along the interosseous membrane or distal radioulnar joint to rule out the Essex-Lopresti lesion<sup>(60)</sup>.

Along with the routine, anteroposterior and lateral radiographs of the elbow, a radiocapitellar view is obtained as a lateral view with the tube tilted 45 degree to the axis of humerus, in order to clear away the ulnar superposition. The elevation of anterior and posterior fat pads is suggestive of intraarticular haematoma (Sail sign). For complex fractures and concomitant injuries, a CT scan is helpful.

Mason classification is based on the displacement and the comminution of the fragments. Accordingly, a type I fracture is minimally displaced, type II is a displaced marginal fracture and type III has a displaced comminution. A type IV is added by Johnston, describing a radial head fracture associated with dislocation of the ulnohumeral joint. Another treatment oriented modification has been described by Hotchkiss, regrouping fractures that do not require surgery in type I, fixable displaced fractures in type II and unfixable fractures in type III. Charalambous emphasized the limitations of these classifications and proposed

an extensive descriptive system referring the radial head fractures as 2-part partial articular, comminuted partial and total articular and isolated radial neck fractures<sup>(58)</sup>.

Radial head fractures with 2 millimeters or less displacement can be treated conservatively if there is no mechanical block to the joint motion<sup>(58)</sup>. Gentle active flexion exercises are initiated as soon as the inflammation subsides, following few days of immobilization with a broad armsling. The range of motion is extended as much as tolerated, and active pro-supination is started after two to three weeks. An articulated brace is the most favorable orthosis with its adjustable ranges.

Significant comminution or displacement, blocking to the rotation or association with a complex injury are surgical indications. Surgical treatment comprises open reduction and screw or plate osteosynthesis, radial head excision and radial head prosthesis. Mason type II injuries with up to 30% of articular involvement and over 2 mm of displacement require surgical intervention if there is a mechanical block or a ligamentous injury. Screw fixation provides better outcomes than plating. Safe zone is a 120 degrees arc over the radial head that does not articulate with the radial notch of the proximal ulna. The implants should be placed in this zone which can be estimated between the lines projected through the radial styloid and Lister tubercle. Comminution is the major drawback to the osteosynthesis in Mason type III fractures. Excision or replacement of the radial head is advocated. Radial head excision cannot be performed if the primary stabilizer of the elbow, such as ulnar and radial collateral ligament or the coronoid process are non functional. We recommend an interposition arthroplasty

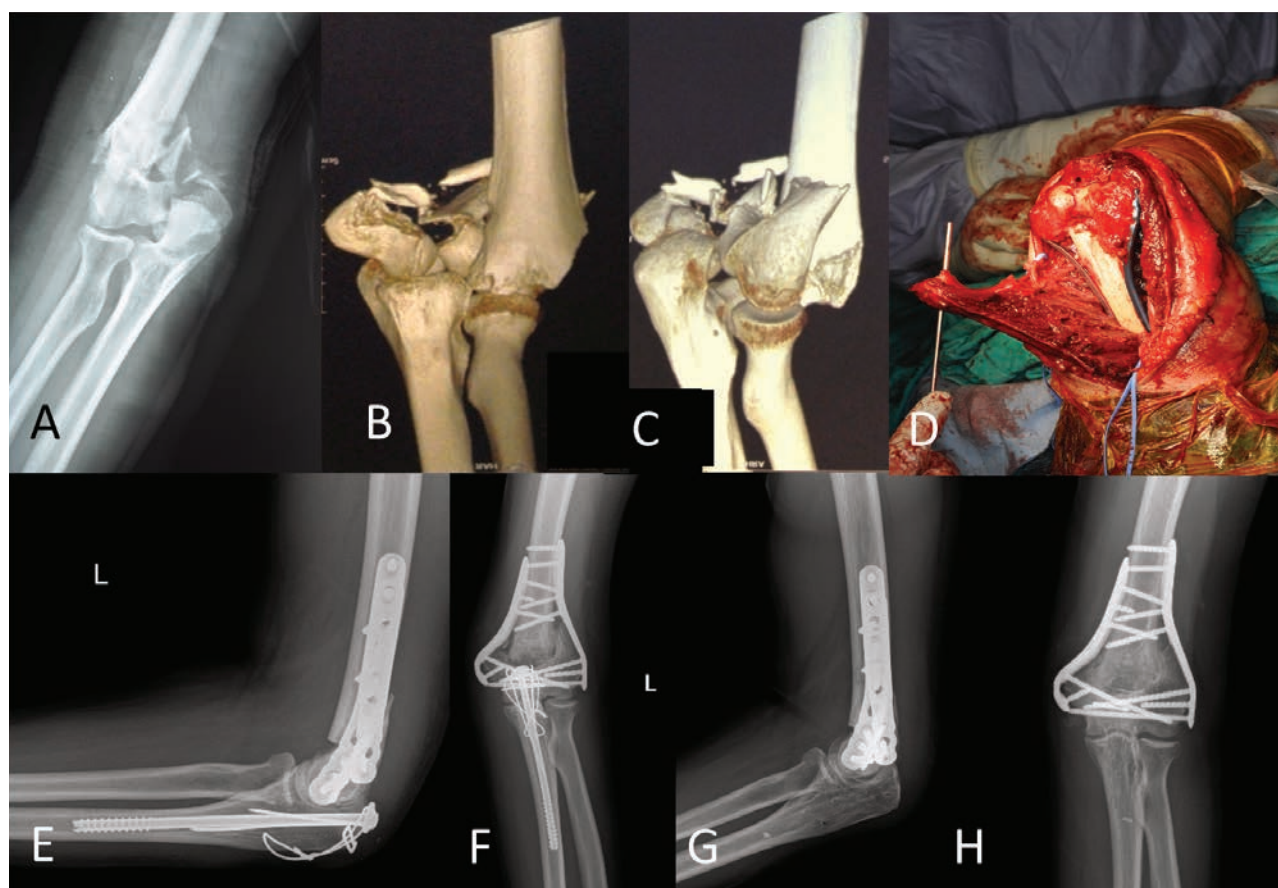


Figure 10: Radiograph (A) and 3D CT (B and C) images of a 57-years-old male patient who sustained a grade 2 open distal elbow fracture in a car accident. Parallel plating with shortening and compression of the supracondylar colons through an olecranon osteotomy was implemented (D). Early postoperative radiographs (E and F) along with 2 years follow-up results after the olecranon screw was removed (G and H). Open reduction and internal fixation with headless compression screws or plates can be implemented in the management of capitellar fractures.

using anconeus or achilles tendon allografts along with radial head excision to avoid proximal migration of the radius<sup>(57)</sup>. Radial head excision has favorable short-term outcomes without concomitant injury however, long-term degenerative changes are inevitable<sup>(61)</sup>.

The radial head is usually boarded laterally, through an incision starting from the supracondylar ridge and extending through the Kocher interval. An intermuscular plane can be developed between extensor carpi radialis brevis and extensor digitorum communis for the exposure of the radial head, coronoid process and distal anterolateral humerus. We recommend this approach should only be used by experienced surgeons, familiar with the complex anatomy, considering the high risk of posterior interosseous nerve injury. Boyd approach can also be utilized for the exposure of both ulna and radius in complex injuries. Exposure with Hohmann type retractors must be avoided over the anterior neck of the radius, in

head replacement<sup>(63)</sup>. Correct sizing is crucial to avoid overstuffing and restriction of the range of motion. A morphometric study suggested that for estimation of the radial head size, measurement of the contralateral side or length of the radius or ulna is the most accurate<sup>(67)</sup>. Although very often encountered, osteolysis around stem is reported to be unrelated with the outcomes.

Stiffness, particularly in the forearm pro-supination, and heterotopic ossification are the most common complications of radial head prosthesis. Overstuffing of the radiocapitellar joint also negatively affects ROM. Infections, loss of fixations or displacement and long-term radiocapitellar arthritis are among other complications.

## 7. Olecranon Fractures

The most common trauma mechanism is a direct blow or a fall on a hand with the elbow in flexion. As the energy of the trauma intensifies, the injury becomes more complex with the association of the elbow dislocation and radial head or coronoid fractures. A sudden, intense contraction of the triceps may also cause an avulsion fracture from the tip of the olecranon<sup>(69)</sup>. Mayo classification distinguishes olecranon fractures based on displacement and stability.

The fracture may be directly palpable subcutaneously. The pain and the typical swelling are localised in the posterior elbow. As a main determinant of the surgical indication, the integrity of the extensor mechanism must be carefully assessed.

Isolated fractures of the olecranon may be evaluated on an AP and a true lateral radiograph, however, a CT scan is imperative to identify the fragments of a complex injury.

A majority of olecranon fractures are displaced due to the strong deforming force of the triceps thus, non-operative treatment is occasional. Subcutaneous location of the olecranon facilitates its exposure. Patient may be positioned supine or lateral decubitus. The incision is longitudinal over the ulna and curves radially to eliminate the tip of the olecranon. Ulnar nerve is protected beneath the large medial soft-tissue flap.

The anatomical reduction must be established with direct visualisation of the articular surface, to avoid step-off or incongruity. Tension band technique using Kirschner wires is favorable for basic transvers fractures, as long as technical requirements are met<sup>(70)</sup>. Dynamic or locking compression plates with an intramedullary longitudinal screw (the home-run screw), at the most proximal hole, are indicated in comminuted fractures<sup>(69)</sup>. The fixation can be augmented with interfragmentary compression screws in oblique fractures.

The patient is placed in a long arm splint at 80 degrees of flexion and passive flexion and extension exercises are initiated following the inflammation phase subsides. The control of the pain is essential at postoperative phase and we recommend brachial plexus block to tolerate early ROM exercises. Resistive extension is delayed until the 6th week, or when clinical and radiological healing are established.

Reoperation is a common disadvantage of the osteosynthesis of the olecranon fractures<sup>(69)</sup>. The tension band technique is reported to have a higher rate of complications, such as back out of the wires and higher rate of implant removal in symptomatic patients<sup>(69)</sup>. However, complications encountered in plates were more

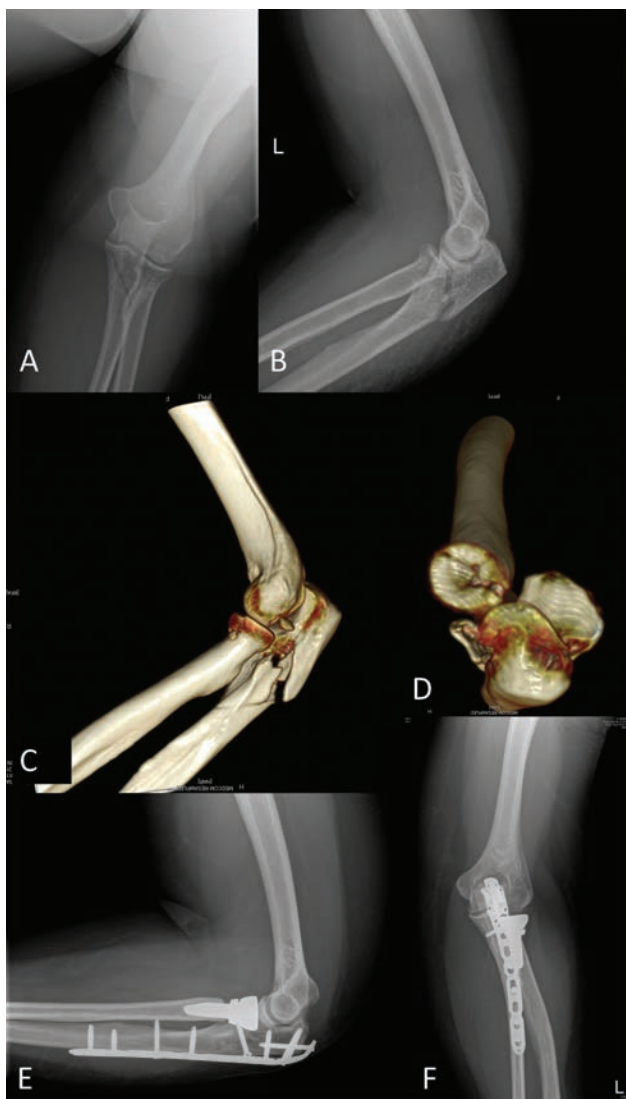


Figure 11: (A and B) radiographs and 3D CT of a transolecranon basal coronoid fracture with a comminuted radial head fracture. The patient is treated with a radial head replacement with the open reduction plate fixation of the proximal ulnar fracture.

order to spare posterior interosseous nerve compression.

A comminuted radial head fracture in an instable elbow joint is a good candidate for a radial head replacement (Figure 11). A modular, metallic and uncemented prosthesis is implemented for radial

serious such as infection and the need of revision surgery <sup>(69,70)</sup>.

8. Coronoid Fractures

Coronoid process is the primary constraint to posterior subluxation of the elbow. Coronoid fractures consist in 10 to 15% of the elbow injuries and are encountered isolated or as a part of a more complex pattern <sup>(74)</sup>. The association of a coracoid fracture with an unstable radial head fracture and an elbow dislocation is referred as the 'terrible triad of the elbow' because of the difficulties encountered in its management <sup>(75)</sup>.

The patient must be assessed for the elbow instability, because the sublime tubercle, insertion of the medial collateral ligament, is located at the basis of the coronoid. Moreover, anteromedial facet fractures of the coronoid result from a varus stress which often damages the lateral collateral ligament, referred as the posteromedial rotatory instability of the elbow <sup>(73)</sup>.

CT scan is recommended in patients with severe comminution and superpositions on standard radiographs hinder adequate visualization <sup>(71)</sup>.

Regan and Morrey's anatomical classification is further elaborated by O'driscoll in order to include 'unclassifiable fractures' and improve its clinically oriented aspect <sup>(76)</sup>. The fractures are classified into 3 main groups such as tip, anteromedial and basal, and into subtypes with precise clinical descriptions (Figure 12, Table 2). Anteromedial fractures involving the sublime tubercle, show

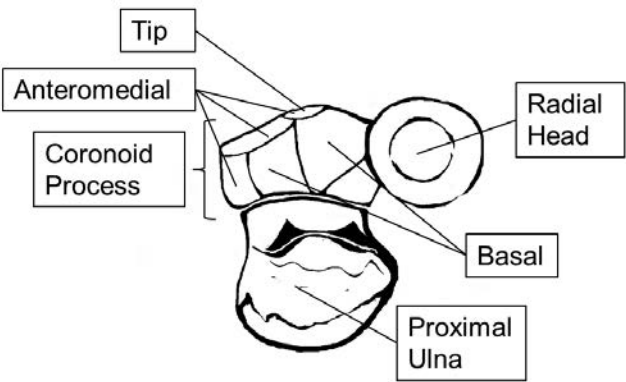


Figure 12: Illustration of the proximal ulna, depicting O'Driscoll's coronoid fracture classification

particular clinical features because the insertion of the medial collateral ligament is disrupted. Subsequent elbow instability must be addressed in these patients for favorable outcomes <sup>(72)</sup>.

Conservative treatment is reserved for isolated minimally displaced fractures with no insult to the elbow stability. Most coronoid fractures are addressed surgically, in order to restore the stability or as a component of a complex injury. A lateral approach is preferred when concomitant injuries are laterally accessible such as LCL or radial head. Coronoid process can be directly visualized after the removal of the radial head fragments. In cases with intact radial head, a medial approach is preferred. The exposure of the anteromedial fractures are easier from a medial incision.

Suture passing fixation is adequate for small coronoid tip fragments however, larger fragments require a more stable fixation

Table 2: O'Driscoll Classification for Coronoid process fractures.

Fracture Tip	Subtype	Description
	1	≤2 mm of coronoid height
	2	≥2 mm of coronoid height
Anteromedial	1	Anteromedial rim
	2	Anteromedial rim and tip
	3	Anteromedial rim and sublime tubercle (+/-) tip
Basal	1	Coronoid body and base
	2	Transolecranon basal coronoid fracture

Table 2: O'Driscoll Classification for Coronoid process fractures.

with either a retrograde screw or a buttress plate <sup>(74)</sup>.

9. Forearm fractures

Along with the isolated fractures of radius or ulna, complex injuries including more than one anatomical location of the radioulnar association are described. Namely Monteggia fracture is defined as a fracture of the ulna along with a radial head dislocation and Galeazzi fracture is diagnosed when ulnar shaft is fractured with an injury to distal radioulnar joint.

The pain and deformity are the major clinical findings of a patient with forearm fracture. Vascular compromise is assessed through capillary filling and pulses along with an adequate neurological evaluation. The compartment syndrome is a common and devastating complication of the forearm fractures and awareness must be maintained all along the treatment process <sup>(78)</sup>.

Imaging of a patient with a forearm injury includes plain orthogonal radiographs of the forearm, wrist and elbow. In cases of complex injuries, MRI is required to rule out ligament distortions<sup>(1)</sup>.

AO classification for long bones is the most widely used system for the forearm fractures. Monteggia fractures are further classified by Bado, using a four type descriptive system. In fractures type I, a middle or proximally located ulnar fracture accompanies an anterior dislocation of the radial head. As an opposite to this trauma, in type II, radial head is dislocated posteriorly along with a posterior angulated proximal ulnar fracture. This is the most common type (70 to 80%) of the adult Monteggia cases. Type III describes a laterally dislocated radial head and an ulnar fracture distal to the coronoid process. In type IV, which is the rarest type, both radius and ulna are fractured proximally, regardless of the direction of the radial head dislocation<sup>(1,79)</sup>.

Radius and ulna compose a complex articular unit through the interosseous membrane, thus even diaphyseal fractures of these bones should be considered intraarticular. Failure to restore the radial bowing and the integrity of the interosseous membrane results in loss of rotation and grip strenght. Hereby, conservative treatment is not an option in both bone fractures of the adult population, except for the patients that cannot be operated due to severe comorbidity. High rates of non-union are reported in patients treated non-operatively <sup>(77,79)</sup>.



Open reduction and plate fixations are considered gold standard treatments for adult forearm fractures. The most commonly used approach to radius shaft is volar, namely Henry approach. Radius can also be exposed dorsally (Thompson) and posterior interosseous nerve must be identified and protected while either exposures. Ulna can be directly exposed due to its subcutaneous location and poor muscle envelope. External fixation can be applied in cases of open fracture and caution must be taken while placing pins on proximal radius.

Stability of the ulnar fixation is crucial in the surgical management of Monteggia fractures. If ulnar alignment and length cannot be securely restored, radial head dislocation must be addressed with an open reduction and annular ligament repair or reconstruction.

## References:

1. AAOS Comprehensive Orthopedic Review. Martin I. Boyer, MD, FRCS(C), Editor 2014 Rosemont, IL, American Academy of Orthopaedic Surgeons.
2. Endrizzi DP, White RR, Babikian GM, Old AB. Nonunion of the clavicle treated with plate fixation: a review of forty-seven consecutive cases. *J Shoulder Elbow Surg.* 2008 Nov-Dec;17(6):951-3. doi: 10.1016/j.jse.2008.05.046
3. Ersen A, Atalar AC, Birisik F, Saglam Y, Demirhan M. Comparison of simple arm sling and figure of eight clavicular bandage for midshaft clavicular fractures: a randomised controlled study. *Bone Joint J.* 2015 Nov;97-B(11):1562-5. doi: 10.1302/0301-620X.97B11.35588.
4. Jarvis NE, Halliday L, Sinnott M, Mackenzie T, Funk L, Monga P. Surgery for the fractured clavicle: factors predicting nonunion. *J Shoulder Elbow Surg.* 2017 Dec 19. pii: S1058-2746(17)30670-5. doi: 10.1016/j.jse.2017.10.010
5. Hoogervorst P, Appalsamy A, Meijer D, Doornberg JN, van Kampen A, Hannink G. Does altering projection of the fractured clavicle change treatment strategy? *J Shoulder Elbow Surg.* 2018 Oct 19. pii: S1058-2746(18)30603-7. doi: 10.1016/j.jse.2018.08.008
6. Hsu KH, Tzeng YH, Chang MC, Chiang CC. Comparing the coracoclavicular loop technique with a hook plate for the treatment of distal clavicle fractures. *J Shoulder Elbow Surg.* 2018 Feb;27(2):224-230. doi: 10.1016/j.jse.2017.08.017
7. Hussey MM, Chen Y, Fajardo RA, Dutta AK. Analysis of neurovascular safety between superior and anterior plating techniques of clavicle fractures. *J Orthop Trauma.* 2013 Nov;27(11):627-32. doi: 10.1097/BOT.0b013e31828c1e37.
8. Huttunen TT, Launonen AP, Berg HE, Lepola V, Felländer-Tsai L, Mattila VM. Trends in the Incidence of Clavicle Fractures and Surgical Repair in Sweden: 2001-2012. *J Bone Joint Surg Am.* 2016 Nov 2;98(21):1837-1842. Doi: 10.2106/JBJS.15.01284
9. Liu J, Srivastava K, Washington T, Hoegler J, Guthrie ST, Hakeos W. Cost-Effectiveness of Operative Versus Nonoperative Treatment of Displaced Midshaft Clavicle Fractures: A Decision Analysis. *J Bone Joint Surg Am.* 2019 Jan 2;101(1):35-47. doi: 10.2106/JBJS.17.00786.
10. Potter JM, Jones C, Wild LM, Schemitsch EH, McKee MD. Does delay matter? The restoration of objectively measured shoulder strength and patient-oriented outcome after immediate fixation versus delayed reconstruction of displaced midshaft fractures of the clavicle. *J Shoulder Elbow Surg.* 2007 Sep-Oct;16(5):514-8. Doi: 10.1016/j.jse.2007.01.001
11. Qvist AH, Væsel MT, Jensen CM, Jensen SL. Plate fixation compared with nonoperative treatment of displaced midshaft clavicular fractures: a randomized clinical trial. *Bone Joint J.* 2018 Oct;100-B(10):1385-1391. doi: 10.1302/0301-620X.100B10.BJJ-2017-1137.R3
12. Schroder LK, Gauger EM, Gilbertson JA, Cole PA. Functional Outcomes After Operative Management of Extra-Articular Glenoid Neck and Scapular Body Fractures. *J Bone Joint Surg Am.* 2016 Oct 5;98(19):1623-1630.
13. Uzer G, Yildiz F, Batar S, Bozdag E, Kuduz H, Bilsel K. Biomechanical comparison of three different plate configurations for comminuted clavicle midshaft fracture fixation. *J Shoulder Elbow Surg.* 2017 Dec;26(12):2200-2205. doi: 10.1016/j.jse.2017.06.034
14. Woltz S, Krijnen P, Schipper IB. Plate Fixation Versus Nonoperative Treatment for Displaced Midshaft Clavicular Fractures: A Meta-Analysis of Randomized Controlled Trials. *J Bone Joint Surg Am.* 2017 Jun 21;99(12):1051-1057. doi: 10.2106/JBJS.16.01068.
15. Mighell MA, Hatzidakis AM, Otto RJ, Watson JT, Cottrell BJ, Cusick MC, et al. Complex trauma to the shoulder girdle, including the proximal humerus, the clavicle, and the scapula: current concepts in diagnosis and treatment. *Instr Course Lect.* 2015;64:121-37
16. Schofer MD, Sehrt AC, Timmesfeld N, Störmer S, Kortmann HR. Fractures of the scapula: long-term results after conservative treatment. *Arch Orthop Trauma Surg.* 2009 Nov;129(11):1511-9. doi: 10.1007/s00402-009-0855-3
17. Tuček M, Chochola A, Klika D, Bartoniček J. Epidemiology of scapular fractures. *Acta Orthop Belg.* 2017 Mar;83(1):8-15
18. van Oostveen DP, Temmerman OP, Burger BJ, van Noort A, Robinson M. Glenoid fractures: a review of pathology, classification, treatment and results. *Acta Orthop Belg.* 2014 Mar;80(1):88-98.
19. Atalar AC, Eren I, Uludağ S, Demirhan M. Results of surgical management of valgus-impacted proximal humerus fractures with structural allografts. *Acta Orthop Traumatol Turc.* 2014;48(5):546-52. doi: 10.3944/AOTT.2014.14.0115.
20. Boileau P, d'Ollonne T, Bessière C, Wilson A, Clavert P, Hatzidakis AM, et al. Displaced humeral surgical neck fractures: classification and results of third-generation percutaneous intramedullary nailing. *J Shoulder Elbow Surg.* 2019 Feb;28(2):276-287. doi: 10.1016/j.jse.2018.07.010
21. Carbone S, Razzano C, Albino P, Mezzoprete R. Immediate intensive mobilization compared with immediate conventional mobilization for the impacted osteoporotic conservatively treated proximal humeral fracture: a randomized controlled trial. *Musculoskelet Surg.* 2017 Dec;101(Suppl 2):137-143. doi: 10.1007/s12306-017-0483-y

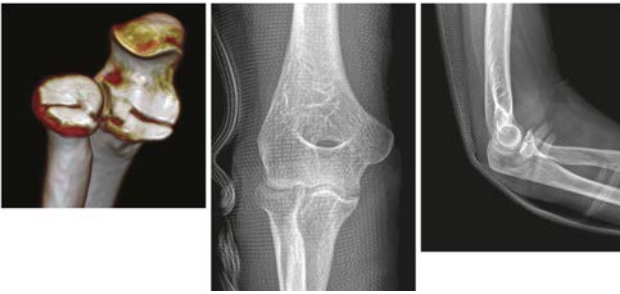

22. Chen Y, Jia X, Qiang M, Zhang K, Chen S. Computer-Assisted Virtual Surgical Technology Versus Three-Dimensional Printing Technology in Preoperative Planning for Displaced Three and Four-Part Fractures of the Proximal End of the Humerus. *J Bone Joint Surg Am.* 2018 Nov 21;100(22):1960-1968. doi: 10.2106/JBJS.18.00477.
23. Chivot M, Lami D, Bizzozero P, Galland A, Argenson JN. Three- and four-part displaced proximal humeral fractures in patients older than 70 years: reverse shoulder arthroplasty or nonsurgical treatment? *J Shoulder Elbow Surg.* 2019 Feb;28(2):252-259. doi: 10.1016/j.jse.2018.07.019
24. Demirhan M, Kilicoglu O, Altinel L, Eralp L, Akalin Y. Prognostic factors in prosthetic replacement for acute proximal humerus fractures. *J Orthop Trauma.* 2003 Mar;17(3):181-8; discussion 188-9.
25. Grubhofer F, Wieser K, Meyer DC, Catanzaro S, Schürholz K, Gerber C. Reverse total shoulder arthroplasty for failed open reduction and internal fixation of fractures of the proximal humerus. *J Shoulder Elbow Surg.* 2017 Jan;26(1):92-100. doi: 10.1016/j.jse.2016.05.020
26. Hasan AP, Phadnis J, Jaarsma RL, Bain GL. Fracture line morphology of complex proximal humeral fractures. *J Shoulder Elbow Surg.* 2017 Oct;26(10):e300-e308. doi: 10.1016/j.jse.2017.05.014
27. Hertel R, Hempfing A, Stiehler M, Leunig M. Predictors of humeral head ischemia after intracapsular fracture of the proximal humerus. *J Shoulder Elbow Surg.* 2004 Jul-Aug;13(4):427-33
28. Jain NP, Mannan SS, Dharmarajan R, Rangan A. Tuberosity healing after reverse shoulder arthroplasty for complex proximal humeral fractures in elderly patients-does it improve outcomes? A systematic review and meta-analysis. *J Shoulder Elbow Surg.* 2018 Dec 26. pii: S1058-2746(18)30696-7. doi: 10.1016/j.jse.2018.09.006
29. Murray IR, Amin AK, White TO, Robinson CM. Proximal humeral fractures: current concepts in classification, treatment and outcomes. *J Bone Joint Surg Br.* 2011 Jan;93(1):1-11. doi: 10.1302/0301-620X.93B1.25702.
30. Neer CS 2nd. Four-segment classification of proximal humeral fractures: purpose and reliable use. *J Shoulder Elbow Surg.* 2002 Jul-Aug;11(4):389-400
31. Neviaser RJ, Resch H, Neviaser AS, Crosby LA. Proximal humeral fractures: pin, plate, or replace. *Instr Course Lect.* 2015;64:203-14.
32. Padegimas EM, Zmistowski B, Lawrence C, Palmquist A, Nicholson TA, Namdari S. Defining optimal calcar screw positioning in proximal humerus fracture fixation. *J Shoulder Elbow Surg.* 2017 Nov;26(11):1931-1937. doi: 10.1016/j.jse.2017.05.003.
33. Passaretti D, Candela V, Sessa P, Gumina S. Epidemiology of proximal humeral fractures: a detailed survey of 711 patients in a metropolitan area. *J Shoulder Elbow Surg.* 2017 Dec;26(12):2117-2124. doi: 10.1016/j.jse.2017.05.029
34. Rangan A, Handoll H, Brealey S, Jefferson L, Keding A, Martin BC, et al. Surgical vs nonsurgical treatment of adults with displaced fractures of the proximal humerus: the PROFHER randomized clinical trial. *JAMA.* 2015 Mar 10;313(10):1037-47. doi: 10.1001/jama.2015.1629.
35. Spross C, Jost B, Rahm S, Winklhofer S, Erhardt J, Benninger E. How many radiographs are needed to detect angular stable head screw cut outs of the proximal humerus - a cadaver study. *Injury.* 2014 Oct;45(10):1557-63. doi: 10.1016/j.injury.2014.05.025
36. Sukthankar AV, Leonello DT, Hertel RW, Ding GS, Sandow MJ. A comprehensive classification of proximal humeral fractures: HGLS system. *J Shoulder Elbow Surg.* 2013 Jul;22(7):e1-6. doi: 10.1016/j.jse.2012.09.018
37. Szerlip BW, Morris BJ, Edwards TB. Reverse Shoulder Arthroplasty for Trauma: When, Where, and How. *Instr Course Lect.* 2016;65:171-9
38. Atalar AC, Kocaoglu M, Demirhan M, Bilsel K, Eralp L. Comparison of three different treatment modalities in the management of humeral shaft nonunions (plates, unilateral, and circular external fixators). *J Orthop Trauma.* 2008 Apr;22(4):248-57. doi: 10.1097/BOT.0b013e31816c7b89.
39. Mahabier KC, Van Lieshout EM, Van Der Schaaf BC, Roukema GR, Punt BJ, Verhofstad MH, et al. Reliability and Reproducibility of the OTA/AO Classification for Humeral Shaft Fractures. *J Orthop Trauma.* 2017 Mar;31(3):e75-e80. doi: 10.1097/BOT.0000000000000738.
40. Sarahrudi K, Wolf H, Funovics P, Pajenda G, Hausmann JT, Vécsei V. Surgical treatment of pathological fractures of the shaft of the humerus. *J Trauma.* 2009 Mar;66(3):789-94. doi: 10.1097/TA.0b013e3181692132.
41. Sarmiento A, Zagorski JB, Zych GA, Latta LL, Capps CA. Functional bracing for the treatment of fractures of the humeral diaphysis. *J Bone Joint Surg Am.* 2000 Apr;82(4):478-86.
42. Updegrave GF, Mourad W, Abboud JA. Humeral shaft fractures. *J Shoulder Elbow Surg.* 2017 Dec 29. pii: S1058-2746(17)30688-2. doi: 10.1016/j.jse.2017.10.028
43. Aitken SA, Jenkins PJ, Rymaszewski L. Revisiting the 'bag of bones': functional outcome after the conservative management of a fracture of the distal humerus. *Bone Joint J.* 2015 Aug;97-B(8):1132-8. doi: 10.1302/0301-620X.97B8.35410.
44. Atalar AC, Demirhan M, Saldiz A, Kiliçoğlu O, Seyahi A. Functional results of the parallel-plate technique for complex distal humerus fractures. *Acta Orthop Traumatol Turc.* 2009 Jan-Feb;43(1):21-7. doi: 10.3944/AOTT.2009.021
45. Atalar AC, Tunalı O, Erşen A, Kapıcıoğlu M, Sağlam Y, Demirhan MS. Biomechanical comparison of orthogonal versus parallel double plating systems in intraarticular distal humerus fractures. *Acta Orthop Traumatol Turc.* 2017 Jan;51(1):23-28. doi: 10.1016/j.aott.2016.11.001
46. Beazley JC, Baraza N, Jordan R, Modi CS. Distal Humeral Fractures-Current Concepts. *Open Orthop J.* 2017 Nov 30;11:1353-1363. doi: 10.2174/1874325001711011353
47. Bilsel K, Atalar AC, Erdil M, Elmadag M, Sen C, Demirhan M. Coronal plane fractures of the distal humerus involving the capitellum and trochlea treated with open reduction internal fixation. *Arch Orthop Trauma Surg.* 2013 Jun;133(6):797-804. doi: 10.1007/s00402-013-1718-5
48. Erşen A, Demirhan M, Atalar AC, Atıcı T, Kapıcıoğlu M. Is Coonrad-Morrey total elbow arthroplasty a viable option for treatment of distal humeral nonunions in the elderly? *Acta Orthop Traumatol Turc.* 2015;49(4):354-60. doi: 10.3944/AOTT.2015.14.0309.
49. McKee MD, Jupiter JB, Bamberger HB. Coronal shear fractures of the distal end of the humerus. *J Bone Joint Surg Am.* 1996 Jan;78(1):49-54.

1. McKee MD, Veillette CJ, Hall JA, Schemitsch EH, Wild LM, McCormack R, et al. A multicenter, prospective, randomized, controlled trial of open reduction--internal fixation versus total elbow arthroplasty for displaced intra-articular distal humeral fractures in elderly patients. *J Shoulder Elbow Surg.* 2009 Jan-Feb;18(1):3-12. doi: 10.1016/j.jse.2008.06.005
2. O'Driscoll SW. Optimizing stability in distal humeral fracture fixation. *J Shoulder Elbow Surg.* 2005 Jan-Feb;14(1 Suppl S):186S-194S.
3. Prasad N, Dent C. Outcome of total elbow replacement for distal humeral fractures in the elderly: a comparison of primary surgery and surgery after failed internal fixation or conservative treatment. *J Bone Joint Surg Br.* 2008 Mar;90(3):343-8. doi: 10.1302/0301-620X.90B3.18971.
4. Sanchez-Sotelo J. Distal humeral fractures: role of internal fixation and elbow arthroplasty. *J Bone Joint Surg Am.* 2012 Mar 21;94(6):555-68. doi: 10.2106/JBJS.9461cl.
5. Tunalı O, Erşen A, Pehlivanoglu T, Bayram S, Atalar AC, Demirhan M. Evaluation of risk factors for stiffness after distal humerus plating. *Int Orthop.* 2018 Apr;42(4):921-926. doi: 10.1007/s00264-018-3792-3
6. Zimmer ZR, Horneff JG 3rd, Taylor RM, Levin LS, Kovach S, Mehta S. Evaluation and Treatment of Open Distal Humeral Fractures. *JBJS Rev.* 2017 Jan 3;5(1). pii: 01874474-201701000-00005. doi: 10.2106/JBJS.RVW.16.00024.
7. Athwal GS, Frank SG, Grewal R, Faber KJ, Johnson J, King GJ. Determination of correct implant size in radial head arthroplasty to avoid overlengthening: surgical technique. *J Bone Joint Surg Am.* 2010 Sep;92 Suppl 1 Pt 2:250-7. doi: 10.2106/JBJS.J.00356.
8. Baghdadi YM, Morrey BF, Sanchez-Sotelo J. Anconeus interposition arthroplasty: mid- to long-term results. *Clin Orthop Relat Res.* 2014 Jul;472(7):2151-61. doi: 10.1007/s11999-014-3629-3.
9. Charalambous CP, Stanley JK, Mills SP, Hayton MJ, Hearnden A, Trail I, Gagey O. Comminuted radial head fractures: aspects of current management. *J Shoulder Elbow Surg.* 2011 Sep;20(6):996-1007. doi: 10.1016/j.jse.2011.02.013
10. Davidson PA, Moseley JB Jr, Tullos HS. Radial head fracture. A potentially complex injury. *Clin Orthop Relat Res.* 1993 Dec;(297):224-30.
11. Duckworth AD, Clement ND, Aitken SA, Ring D, McQueen MM. Essex-Lopresti lesion associated with an impacted radial neck fracture: interest of ulnar shortening in the secondary management of sequelae. *J Shoulder Elbow Surg.* 2011 Sep;20(6):e19-24. doi: 10.1016/j.jse.2011.02.017
12. Herbertsson P, Josefsson PO, Hasselius R, Besjakov J, Nyqvist F, Karlsson MK. Fractures of the radial head and neck treated with radial head excision. *J Bone Joint Surg Am.* 2004 Sep;86-A(9):1925-30.
13. Itamura J, Roidis N, Mirzayan R, Vaishnav S, Learch T, Shean C. Radial head fractures: MRI evaluation of associated injuries. *J Shoulder Elbow Surg.* 2005 Jul-Aug;14(4):421-4.
14. Lott A, Broder K, Goch A, Konda SR, Egol KA. Results after radial head arthroplasty in unstable fractures. *J Shoulder Elbow Surg.* 2018 Feb;27(2):270-275. doi: 10.1016/j.jse.2017.10.011
15. Morrey BF, An KN, Stormont TJ. Force transmission through the radial head. *J Bone Joint Surg Am.* 1988 Feb;70(2):250-6.
16. Morrey BF, Tanaka S, An KN. Valgus stability of the elbow. A definition of primary and secondary constraints. *Clin Orthop Relat Res.* 1991 Apr;(265):187-95.
17. Phadnis J, Watts AC. Longitudinal instability of the forearm. *Orthopade.* 2016 Oct;45(10):861-9. doi: 10.1007/s00132-016-3329-7.
18. Rausch V, Wegmann S, Hackl M, Leschinger T, Neiss WF, Scaal M, et al. The radial head size in relation to osseous landmarks of the forearm. *Surg Radiol Anat.* 2018 Dec 12. doi: 10.1007/s00276-018-2160-8
19. van Riet RP, Morrey BF. Documentation of associated injuries occurring with radial head fracture. *Clin Orthop Relat Res.* 2008 Jan;466(1):130-4. doi: 10.1007/s11999-007-0064-8
20. Duckworth AD, Clement ND, McEachan JE, White TO, Court-Brown CM, McQueen MM. Prospective randomised trial of non-operative versus operative management of olecranon fractures in the elderly. *Bone Joint J.* 2017 Jul;99-B(7):964-972. doi: 10.1302/0301-620X.99B7.BJJ-2016-1112.R2
21. Duckworth AD, Clement ND, White TO, Court-Brown CM, McQueen MM. Plate Versus Tension-Band Wire Fixation for Olecranon Fractures: A Prospective Randomized Trial. *J Bone Joint Surg Am.* 2017 Aug 2;99(15):1261-1273. doi: 10.2106/JBJS.16.00773.
22. Adams JE, Sanchez-Sotelo J, Kallina CF 4th, Morrey BF, Steinmann SP. Fractures of the coronoid: morphology based upon computer tomography scanning. *J Shoulder Elbow Surg.* 2012 Jun;21(6):782-8. doi: 10.1016/j.jse.2012.01.008
23. O'Driscoll SW, Jupiter JB, Cohen MS, Ring D, McKee MD. Difficult elbow fractures: pearls and pitfalls. *Instr Course Lect.* 2003;52:113-34
24. Pollock JW, Brownhill J, Ferreira L, McDonald CP, Johnson J, King G. The effect of anteromedial facet fractures of the coronoid and lateral collateral ligament injury on elbow stability and kinematics. *J Bone Joint Surg Am.* 2009 Jun;91(6):1448-58. doi: 10.2106/JBJS.H.00222
25. Ring D, Horst TA. Coronoid Fractures. *J Orthop Trauma.* 2015 Oct;29(10):437-40. doi: 10.1097/BOT.0000000000000326
26. Ring D, Jupiter JB, Zilberfarb J. Posterior dislocation of the elbow with fractures of the radial head and coronoid. *J Bone Joint Surg Am.* 2002 Apr;84-A(4):547-51.
27. Sanchez-Sotelo J, O'Driscoll SW, Morrey BF. Medial oblique compression fracture of the coronoid process of the ulna. *J Shoulder Elbow Surg.* 2005 Jan-Feb;14(1):60-4.
28. Bot AG, Doornberg JN, Lindenhovius AL, Ring D, Goslings JC, van Dijk CN. Long-term outcomes of fractures of both bones of the forearm. *J Bone Joint Surg Am.* 2011 Mar 16;93(6):527-32. doi: 10.2106/JBJS.J.00581.
29. Duckworth AD, Mitchell SE, Molyneux SG, White TO, Court-Brown CM, McQueen MM. Acute compartment syndrome of the forearm. *J Bone Joint Surg Am.* 2012 May 16;94(10):e63. doi: 10.2106/JBJS.K.00837.
30. Konrad GG, Kundel K, Kreuz PC, Oberst M, Sudkamp NP. Monteggia fractures in adults: long-term results and prognostic factors. *J Bone Joint Surg Br.* 2007 Mar;89(3):354-60.

## Questions

1. A 67-years-old concert pianist sustained a fall on a pronated outstretched hand. She was admitted to the emergency clinic complaining of a severe pain over laterel elbow, and over the antecubital fossa aggravating during active elbow flexion. A restriction to the elbow motion is documented following an

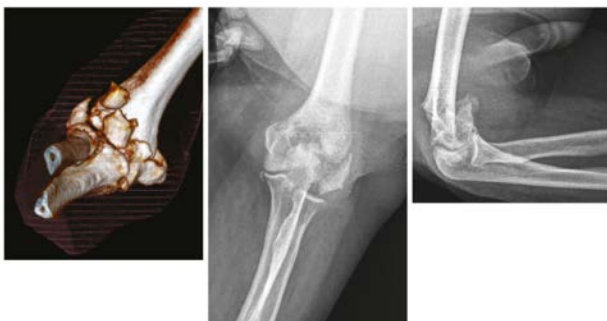

haemorrhagic aspiration and local anesthetic infiltration of the joint. Valgus stress test is positive. Her radiographs and CT scan revealed a Mason type II radial head fracture and an anteromedial rim and tip fracture of the coronoid process. Your management would be:

- Sling immobilization until the pain subsides, followed by active mobilization.
  - Long arm cast immobilization for 2 weeks, followed by active mobilization.
  - Radial head replacement along with an open reduction internal fixation of the coronoid process
  - Open reduction and internal fixation of the radial head
  - Excision of the radial head fragment, collateral ligament repair or reconstruction.
2. A 31-years-old male patient is brought to the hospital after sustaining a motor vehicle accident. He has a severe pain and a gross angular deformity over his left arm. The radiographs show a long oblique shaft fracture at the middle and distal third junction of the humerus and the patient has a drop hand and no sensation over the dorsal thumb. Which of the following is an indication for a surgical exploration of the radial nerve
- Only brachioradialis regain on EMG at 2nd month.
  - No improvement on the extensor indicis at 4th month
  - Fibrillations seen at 3-4 months on EMG.
  - Weakness on the pinch strenght at the first year
  - Severe neuropathic pain at 4th month.

3. Which of the following ligaments is ruptured in type IIB distal clavicle fractures according to Neer?

- Ligamentum trapezoideum
  - Ligamentum conoideum
  - Ligamentum acromioclaviculare superior
  - Ligamentum coracohumerale
  - Ligamentum coracoacromiale
4. A 79-years-old female patient referred to the emergency after a low energy fall injury. Her X-rays and 3D CT views are as below. She lives alone and is under teriparatide treatment due to severe osteoporosis. Which of the following is the most appropriate treatment?



- Brace for 3 weeks and range of motion exercises
- Cast immobilization for 6 to 8 weeks
- Olecranon osteotomy, anatomic reduction and double plate
- Elbow prosthesis with triceps sparing approach
- Arthrodesis with posterior approach

5. A 45-years-old female patient referred following an injury to her shoulder. She has tenderness and swelling on the distal part of the right clavicle. Following X-Rays you classify her fracture as Type IIB injury. Which of the following is the most appropriate treatment?

- Conservative treatment with arm sling for 6 weeks
- Anatomic plate with coracoacromial ligament reconstruction
- Multiple transacromial threaded Kirschner wire fixation
- Hook plate and single transacromial Kirschner wire fixation
- Bosworth screw fixation with acromioclavicular ligament reconstruction

## Answers

1d, 2c, 3b, 4d, 5b.



*Prof. Pawel Reichert*

*pawel.reichert@umw.edu.pl*

Department of Trauma Surgery

Clinical Department of Trauma and Hand Surgery

Wroclaw Medical University – Wroclaw, Poland

## Fractures: Hand & Wrist

### A. Distal Radius Fractures

#### 1. Anatomical Remarks

The distal radius is a vital component of the wrist and forms the supporting articular surface. The hand and its radius together form a unit that is articulated to the ulna and rotates around it. The distal radius has three concave joint surfaces, namely fossa scaphoidea, fossa lunata, and fossa of the distal radioulnar joint (sigmoid notch).

The wrist is a highly flexible joint and allows extension/flexion of about 120 degrees and radial/ulnar deviation of about 50 degrees. About 80% of the axial load is put upon the forearm via the radiocarpal articular surface. Twenty percent of axial load is passed through the ulnar compartment. Required stability for power transmission and mobility are secured through the complex ligament and soft-tissue structures. Forearm rotation pronation/supination amounts 150 degrees a. It occurs in the distal radioulnar joint (DRUJ) by rotation of the radius with the hand around the ulnar head, which is fixed by the ulna and the structure of the elbow joint.

The ulnar-carpal articular surface is formed by the triangular fibrocartilage disc, TFC, and the ligamentous structures, composing the triangular fibrocartilage complex, TFCC. The function of the TFCC is to stabilize the distal radioulnar joint and the ulnar side of the carpus. The TFCC inserts at the distal ulnar-sided articular surface and extends via the distal ulna to the ulnar styloid process and the ulnar head fovea alike.

#### 2. Injury mechanism

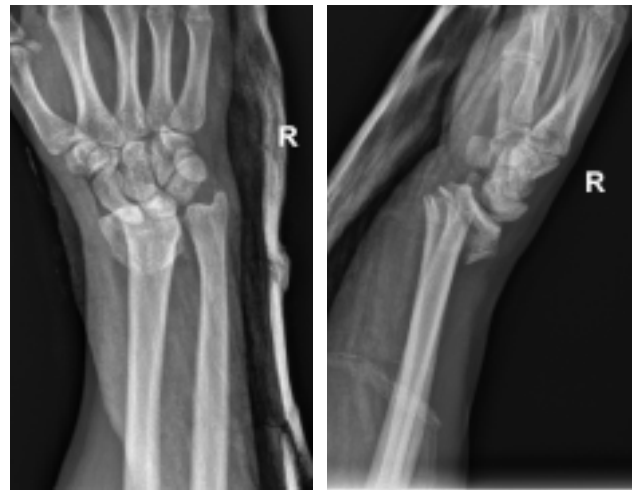
Fractures of the distal radius occur mainly during a fall on an outstretched hand. Depending on the position of the hand, the acting bending forces change, resulting in different fracture types with axial compression or shear fractures. Three types of fractures are to be differentiated at the distal radius: extension fractures, compression fractures of the joint, and shearing fractures of the joint surface.

#### 3. Clinical signs

Distal radius fractures usually result in a shortening of the radius and a deviation of the hand to dorsal and radial sides. Classic signs of the distal radius fractures are swelling, a normally painful restriction of wrist movement, and deformation with a fork or bayonet adjustment.

#### 4. Imaging procedures

In most cases, the two standard X-ray imaging allow for assessing and classifying a distal radius fracture to determine what further therapy might be necessary (Figure 1,2). The degree of the dorsal or palmar tilt must be assessed along with the involvement of the articular surface accompanying injuries of distal radial ulnar joint, DRUJ and fractures of the radial styloid process.



*Figure 1,2: 36 yo female. Intra-articular radius fracture AO Type 23-C2 with minimal displaced fracture of the ulna styloid*

The articular surface is inclined between 20-25 degrees to the ulnar side and between 10-15 degrees to the palmar side. The palmar area of the radius is shallow, and the dorsal area has a slightly convex shape and serves as an abutment for the six dorsal extensor tendons (Figure 3 and Figure 4).

In recent years, magnetic resonance imaging, MRI has been proven an effective method used in diagnosing wrist injuries. Particularly occult fractures and TFC injuries and ligament ruptures can be detected directly by MRI imaging.

Computed tomography (CT), specifically, is used to assess bony injuries and fractures. However, it is worth mentioning, that thin lines amounting to 1 mm are required (Figure 5 and Figure 6).

The arthroscopy of the wrist, on the other hand, is an invaluable yet invasive method for the evaluation of accompanying injuries, such as intercarpal ligament ruptures or TFCC injuries.



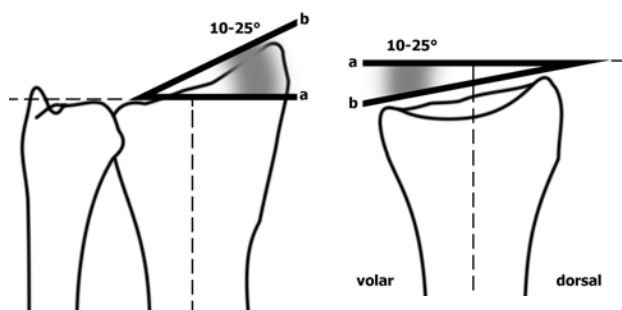


Figure 3,4: Anatomical remarks of distal radius

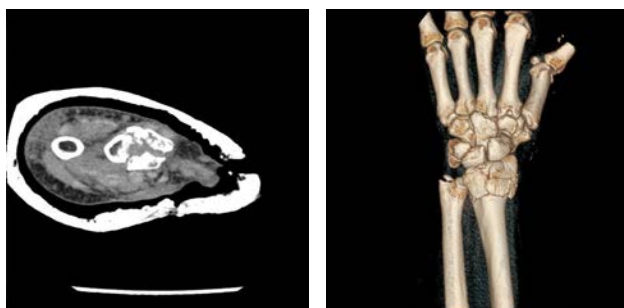


Figure 5,6: CT-scan, 42 yo female. Intra-articular radius fracture AO Type 23-C3 with minimal displaced fracture of the ulna styloid

## 5. Nonoperative treatment

Conservative therapy is used for stable or insignificantly dislocated fractures, therefore also falling under the definition of stable, fractures. This has been seen to affect the most frequently occurring metaphyseal flexion fractures (dorsal malposition). The dislocation here must not exceed a shortening of 3 mm or a tilt of 20 degrees. Displacements, for instance, to the palmar or radial side should not be accepted. A nonsurgical procedure can also be specified if there are very small fragments or if there is no dislocation. There should be no joint step > 2mm or suspected accessory injuries. Conservative treatment is based on the ligamentotaxis mechanism (Figure 7). However, ligamentotaxis does not correct volar tilt, does not correct radial dislocation, and does not correct articular surface compression.

A plaster cast must be carefully modeled and also sufficiently support the distal radius joint fragment. During immobilization period, additional clinical and radiological follow-up is imperative. A clinical evaluation of the plaster cast is routinely carried out 24 hours after its application. An X-ray follow-up and the circular closure of the plaster cast are carried out between 4 and 6 days. At any point in time, the continuation of conservative therapy must be reviewed in a critical manner. X-ray criteria for satisfactory repositioning are: palmar tilt > 0 degrees, radial tilt

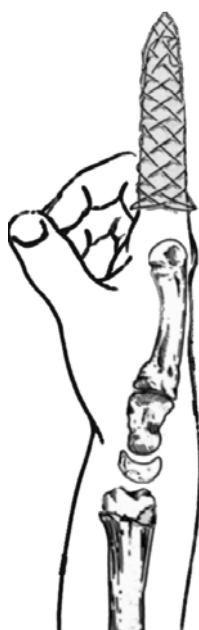

Figure 7:  
Ligamentotaxis  
mechanism

15 degrees, ulnar variance 2 mm, DRUJ congruency, displacement of the articular surface < 1 mm, no disturbances in the wrist architecture. On the other hand, if anywhere, the following three criteria are found: crushing of the palmar or dorsal cortex, dorsal tilt > 20 degrees, shortening > 5mm, radial transposition > 1cm, ulna fracture, impression of the articular surface, or osteoporosis, it is unquestionably a fact that it is to be treated as an unstable fracture and surgery is to be performed.

## 6. Operative treatment

Surgical treatment is usually reserved for relevant dislocation such as distal radius shortening over 3 mm and tilting over 20 degrees, compression (over 1 mm), instabilities or joint luxations (e.g., accompanying fractures of the ulna, subluxation the DRUJ, comminuted areas) and significant accompanying injuries (scapholunate, SL ligament rupture). Reduction and stabilization of the fracture are to take place as early as possible. Concomitant injuries such as damage to the median nerve or a compartment syndrome must also be dealt with immediately.

A standard and well-established procedure has come to be the palmar plate osteosynthesis of the distal radius (Figure 8, Figure 9). Based on AO classification, the surgery has the following indications extra-articular fracture of the radius with dorsal malposition (extension fracture, Colles fracture, extra-articular fracture of the radius with volar deformity, Smith fracture), partial intraarticular fracture of the radius to reconstruct the articular surface from the radial styloid process, beginning at the ulnar side, partial intraarticular fracture of the radius with the detachment of the volar edge, and fully articular fracture of the radius if the dorsal edge fragments are without joint relevance or can be stabilized in an indirect manner.

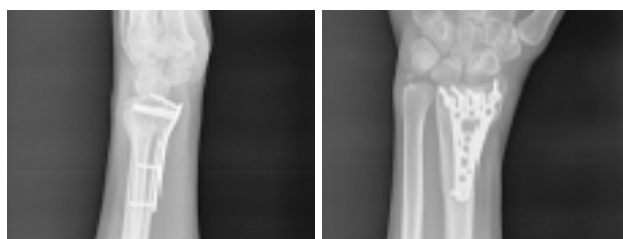


Figure 8,9: 44 yo female. Intra-articular radius fracture AO Type 23-C1 with minimal displaced fracture of the ulna styloid

The dorsal plate osteosynthesis has been criticized for its position in the region of the extensor tendons and the resulting possible irritation of these structures. Improved plate systems (lower profile with smaller implants) have significantly reduced these problems. It should be considered though, that the visibility of the articular surface and its reconstruction is a major advantage. Indications for posterior plate osteosynthesis are constituted of the following fracture types.

Fractures with relevant dorsal articular fragments that cannot be indirectly repositioned and stabilized, partial intraarticular fractures with dislocation, which impair the function of the DRUJ, partial intraarticular fractures that can be dislocated and not safely indirectly stabilized, complete articular fractures when dorsal edge fragments must be directly reduced (ulnar key fragment), completely articular fractures, which can be reduced and "clashed" by means of a plate all fall under the above-mentioned indicators.

## 7. Complications

Bleeding and swelling of soft tissues may lead to the development of post-traumatic carpal tunnel syndrome or compartment syndrome in the forearm both residing in the conservative and surgical treatment of distal radius fractures. In both forms of therapy, the development of Sudeck's dystrophy, now referred to as Complex Regional Pain Syndrome, CRPS. Tendon ruptures are found to be present between 1-2% and mainly affect the extensor pollicis longus tendon.

## 8. After treatment

In the case of conservative treatment in a plaster cast, treatment by an external fixator or the combination of Kirschner wire osteosynthesis and plaster cast, marked attention must be paid to movement exercises of the fingers accompanied by restraint of the wrist, in order to prevent their own restraint. The exercise therapy of the wrist then begins after the removal of the plaster cast or succeeding the release of the wrist. The operative treatment through the means of plate osteosynthesis always hopes to achieve early functional after-treatment. In most cases, after completing wound healing and removal of the cast, the physiotherapy is able to be intensified.

## 9. Subsequent interventions and metal removal

The indication for metal extraction is based on potential complications or possible irritants left by the implants. Individual screws may not be taken out, but due to an increased irritation of flexor tendons, extraction of the palmar plates should be performed or, at the very least, discussed with the patient. Dorsal plate systems are usually extracted due to a possible irritation of soft tissue.

Further follow-up interventions result from the treatment of distal radius fractures or out of functional limitations associated with a more or even less severe injury. An irritant or development of post-traumatic carpal tunnel syndrome may necessitate carpal tunnel release. Other nerve irritations (e.g. superficial branch of radial nerve) may require neurolysis. Ruptures of any tendons must be reconstructed then in follow-up interventions to prevent any sort of functional deficit. The replacement of the extensor pollicis longus tendon by transferring the tendon of the extensor index finger must be included here.

## B. Scaphoid Fracture

### 1. Anatomical remarks

Accounting for up to 60% of all cases, the scaphoid tends to be the most commonly fractured carpal bone. More than 80% of the surface of the scaphoid is covered with articular cartilage, leaving surgeons with no room for error. An improperly treated scaphoid fracture can lead to non-union, degeneration, and avascular necrosis. Up to 80% of immobilized patients do not have a technical scaphoid fracture. Up to 40% of patients with a scaphoid fracture have normal primary radiographs. Non-union occurs in up to 12% of patients if an occult fracture is not detected and treated.

The right way of solving the problem to the matter of correct diagnosis and appropriate treatment of scaphoid fractures is found within the scaphoid's blood supply. The main blood being supplied to the scaphoid is that from the radial artery. The dorsal scaphoid branches from the radial artery pour into the nonarticular part of the scaphoid at the dorsal ridge at the waist level and supply the proximal 70% to 80% of the scaphoid. The volar scaphoid branches from either the radial artery or the superficial palmar branch enter at the distal tubercle and supply the distal 20% to 30% of the scaphoid. With that, the vascularity of the proximal pole depends solely on intraosseous blood flow. This tenuous supply of blood to the proximal pole of the scaphoid begins to explain the increased frequency of delayed union, non-union, and avascular necrosis (AVN) of scaphoid fractures.

### 2. Classifications

A large number of useful sources come from Herbert and Fisher's Classification of Scaphoid Fractures that distinguish following types: A: Stable acute fracture; A1: Tubercle fracture; A2: Incomplete waist fracture; B: Unstable acute fracture; B1: Distal oblique fracture; B2: Complete or displaced waist fracture; B3: Proximal pole fracture; B4: Transscaphoid perilunate dislocation fracture; B5: Comminuted fracture; C: Delayed union; D: Established non-union; D1: Fibrous union; D2: Pseudarthrosis.

### 3. Diagnostic

Clinically, three positive tests, namely scaphoid compression test, anatomical snuffbox tenderness, and scaphoid tubercle tenderness demonstrate statistical significance.

Finally, special attention is to be emphasized on the patient being male, having sustained a sports injury, falling on an outstretched palm of the hand, having anatomical snuff box pain on ulnar deviation of the wrist and pain on thumb-index finger pinch.

An X-ray of the suspected scaphoid fracture is the first step to be made. If there is a fracture the next step depends on whether it is that of a displaced example or not. In case of an apperceived nondisplaced fracture, a CT scan is to be proposed, and depending on the result, a cast or open reduction and internal fixation is suggested. Dispute arises when there is a suspected fracture, but there is no sign on the X-ray. To choose the appropriate course of action, such factors are to be considered: clinical tests results, age, type of work, and average physical activity of the patient. If the MRI scans are normal exclusion of fracture is generally to be accepted. If there is a fracture the course of treatment depends on whether

it is displaced or not. The location of the fracture should also be considered. In scaphoid non-union, preoperative gadolinium-enhanced MRI is recommended to assess the vascularity of the proximal pole. MRIs shows nearly 100% sensitivity and approximately 90% specificity for scaphoid fractures but are limited because they are not available in most settings and are relatively expensive. In addition, studies concerning the MRI usage have focused on specificity and sensitivity instead of accuracy and predictive values, which may be more meaningful diagnostic performance characteristics. CTs have shown up to 95% sensitivity and around 85% specificity, but the diagnostic inaccuracy may have arisen from a misinterpretation of the vascular foramina as fractures. Bone scintigraphy has demonstrated about 95% sensitivity and 60% to 95% specificity. The third (static) phase, obtained 2 to 4 hours p.j., visualizes any osteoblast activity. A standard MRI will show only 68% accuracy for assessing proximal pole vascularity, whereas a gadolinium-enhanced MRI has an 83% accuracy.

#### 4. Treatment

Nondisplaced, uncomplicated fractures can be treated conservatively with immobilization and casting with union rate of up to 95%. Displaced fractures are treated with operation and an interfragmentary screw fixation with a success rate of 92%. Symptomatic scaphoid non-unions are treated surgically with conventional or vascularized bone graft and interfragmentary screw fixation. Non-unions having to do with osteonecrosis of the proximal pole are treated with vascularized bone graft and interfragmentary screw fixation. Reasons cited for unsatisfactory results include size of the proximal fragment, degree of displacement, bone grafting method, surgical techniques, and presence of osteonecrosis of the proximal fragment, that of which is the most important factor in foreseeing the likelihood of success or failure.

If treatment is delayed for 3 weeks or longer, the fracture is to be immobilized in a below-elbow cast without a thumb in light opposition, with free IP joint. Duration of immobilization is as follows: Tuberosity fractures: 6 weeks. Undisplaced waist fracture: 8 weeks depending on CT scan or polyaxial tomography after 8 weeks. If union is not achieved by or within this time, continue with immobilization for an additional 4 weeks. If the fracture heals during this period, start physiotherapy. Otherwise consider operative treatment.

When using internal fixation techniques, bone healing is faster than in a nonoperative treatment, and the period of postoperative immobilization is truncated. The position of the wire should be as perpendicular as possible to the fracture line.

According to the operative treatment, the palmar approach preserves the vital dorsal blood supply and gives access to distal pole and waist fractures; however, this disrupts the carpal ligaments and gives poor or inadequate exposure of the proximal pole.

On the other hand, the dorsal approach gives improved exposure of the proximal pole and allows easier screw placement. This can, however, disrupt the tenuous blood supply.

Even though the choice of approach may be dependent on any given surgeon's preference and experience, the dorsal approach is certainly strongly recommended for fixation of proximal pole fractures because it is technically easier to insert the screw into a

small fractured fragment of the proximal pole.

The palmar approach to the scaphoid provides for access to displaced fractures of the waist that cannot be reduced and fixed with the help of percutaneous techniques.

The danger of this fracture is that of something known as "humpback deformity". This means the distal pole tends to rotate into flexion in relation to the proximal pole, the lunate, and the triquetrum, which are in extension. This can create a rotational and angular deformity at the fracture site. The screw should be as perpendicular as possible to the fracture plane.

With more oblique fractures, the insertion point of the screw will tend to be more ulnar on the distal pole of the scaphoid. In transverse fractures, the insertion point of the screw will tend to be more radial on the distal pole of the scaphoid. The palmar approach to the scaphoid gives access to displaced waist fractures that cannot be reduced and fixed by percutaneous techniques.



Dr. Bernd Grimm, MEng, PhD

Sylvia Lawry Centre – The Human Motion Institute  
Munich, Germany  
grimm@slcmsr.org

## Biomechanics & Biomaterials For Musculoskeletal Application

### 1. Introduction

Biomechanics and Biomaterials are major fields of basic science which can cover semesters of teaching even when limited to musculoskeletal applications, orthopaedics or implants only. This lecture will focus on major concepts, terminology and applications of biomechanics and biomaterials most important to orthopaedic surgery and the curriculum.

This chapter will highlight the clinical relevance of basic biomechanics and biomaterials to motivate a reader of medical background. Concepts of biomechanics and biomaterials which are essential for understanding the beautiful interplay of biology, mechanics and materials in medicine are listed here.

For instance, all cells, in particular bone cells are mechanosensitive by mechanotransduction referring to the molecular mechanisms by which cells sense and respond to mechanical signals. This interplay of physical forces, movement and the mechanical or materials' properties of cells and tissues and, the response in cell development, cell differentiation and thus tissue (re-) generation are referred to as **mechanobiology**. This interface of biology, mechanics and materials' science is increasingly being recognized besides the traditional genetic and biochemical components as a basis of disease development and cure.

The **Wolff's law** is a long established and commonly known expression of this principle, which says that the osseous bone structure, such as trabecular orientation and bone density optimizes itself in adaptation to the mechanical load.

### 2. Biomechanics

One common way to differentiate the disciplines of (bio)mechanics is referring to kinematics, statics and dynamics. **Kinematics** describes the **motion** of objects independent of the forces that originated it. Using kinematics, one can calculate a trajectory or momentary **velocity** of an object, using terminology such as **translation** for straight line movement, **rotation** for any curved movement and the **degrees of freedom** to refer to the number of independent translational and rotational coordinates available to describe an object's position. In orthopaedics, a kinematic approach is common for instance in clinical movement analysis describing e.g. the phases of gait or outcome assessment of joint mobility such as range of motion or the screw-home mechanism common in natural knee kinematics.

**Statics** describe the **forces** and **moments** acting on an object at rest (or in steady motion with zero acceleration) keeping an

**equilibrium**. A force is defined as any influence that causes an object to undergo a certain change, either concerning its movement, direction, or geometrical construction (e.g. deformation, which depends on the material's properties and linking biomechanics to biomaterials). Depending on the direction of effect, forces are described as in **tension**, **compression** or **shear**. When the force is calculated per area it is acting upon, the term **stress** is used.

A moment is defined as the tendency of a force to rotate an object around an axis. A moment (also called torque) affects rotational movement or causes **bending** or **torsional** deformation. In musculoskeletal applications, moments are introduced e.g. by the muscle contraction forces acting via their tendinous insertion points (deduced from insertion area) onto the bones via a lever arm around the joint axis biomechanically considered the fulcrum. Both moments and forces (and thus also stresses) are **vectors** which means we have a direction and orientation in space and a scalar magnitude. For force vectors one also refers to the line and point of application and the sense. Thus, a numerical value by its own does not sufficiently describe a situation in static biomechanics. Common units are: Newton [N] for force, Newtonmeter [Nm] for moments and [N/mm<sup>2</sup>, MPa] for stress.

A major principle in statics with many applications in orthopaedic considerations is the static **equilibrium**. For static equilibrium of an object (solid body), all forces and moments acting upon it cancel each other out, mathematically meaning that the sum (also called resultant) of forces are zero and the sum of moments about a point are also equal to zero. With forces and moments being 3D vectors, this leads to 6 scalar equations in space or 3 scalar equations in a simplified plane scenario (see Fig. 1). Being vectors, when calculating the **lever arm** length for a force causing a moment with reference to a fulcrum, the perpendicular distance to the "line of action" is considered.

To derive the relevant equilibrium equations, a so-called a **free body diagram** is made which is a graphical illustration used to visualize the forces and moments applied to a solid body and calculate the resulting reactions. As an example, the biceps force to statically and horizontally hold in hand an object can be calculated. For an object with mass  $m = 1\text{ kg}$ , a weight (gravitational force) of 10N results. The forearm mass is assumed at 2kg resulting in a 20N weight, with its center of mass and thus line of action at 13cm horizontal distance (lever arm) to the elbow joint considered as fulcrum. Based on anatomic assumptions the distances (lever arms) from elbow joint to hand centre and biceps insertion point are 30cm and 5cm respectively. Resolving the equilibrium equations results in a biceps force of 112N, almost 4 times the weight of forearm and mass.



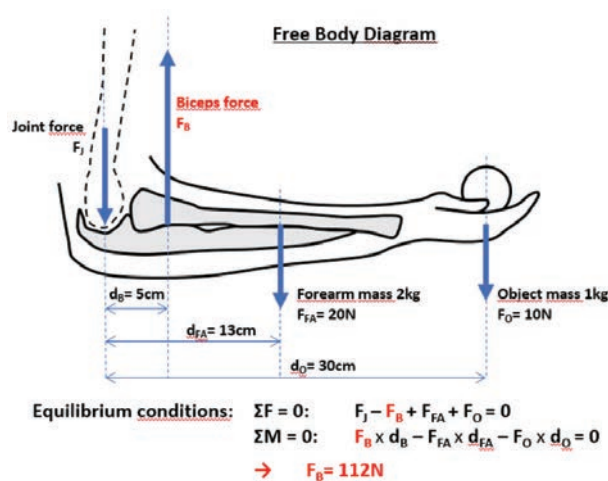


Figure 1: Free Body Diagram to calculate the biceps force required to hold in hand a 1kg mass

**Dynamics** (or **kinetics**) describes the interactions between forces and moments and the motions caused, taking into account the translational and rotational **inertia** of the moving objects such as swinging limbs or carried loads involved. In orthopaedics, dynamics is applied e.g. to calculate the loads and fracture risk of bone or implants during impacts from falls or accidents. Complex dynamic analysis is also applied e.g. in workplace or sports ergonomics, including also computer simulations.

In this context, the famous **Newton's laws of motion** can be considered as the foundation of classic mechanics. The First law states that an object either remains at rest or continues to move at a constant velocity, unless acted upon by a force. The Second law states that the vector sum of the forces  $F$  on an object is equal to the mass  $m$  of that object multiplied by the acceleration  $a$  of the object:  $F = ma$ . The third law, brief in latin "actio est reactio", states that when one body exerts a force on a second body, the second body simultaneously exerts a force equal in magnitude and opposite in direction on the first body. In an orthopaedic biomechanics application, this means for instance that for any movement of a limb, tissue or cell, a force must act upon it (1<sup>st</sup> law). The size of this force depends on the acceleration and inertia (mass, shape) of the object put in motion (2<sup>nd</sup> law). If for instance a person is pushing off the ground by toe off during gait, the floor experiences an equally sized but reversely orientated ground reaction force (3<sup>rd</sup> law), a principle used in laboratory force-plate measurements to calculate e.g. joint reaction forces (also called **inverse dynamics**). Newton's second and third law lead directly to the "Law of **conservation of momentum**", where momentum describes the product of mass and velocity, which in a closed system stays constant as a total; a law for instance applied in impact biomechanics. In combination with the "Law of **conservation of energy**" many dynamic situations in biomechanics can be calculated.

When the human body is modelled with many bones, multiple joints, muscles, muscle insertion points and for various movements or boundary conditions reflecting normal or pathological movement dynamics, many equations based on the principles above must be resolved simultaneously and numerically instead of analytically. The biomaterials' properties of bones (see next chapter), muscles and tendons may be added. This complex task is now often performed using **computer-based modelling** programs such as Anybody ([www.anybodytech.com](http://www.anybodytech.com)).

### 3. Examples of biomechanics in orthopaedics

#### 3.1 Wolff's law, Davis' law and Mechanostat

In the introduction, there was already a reference to Wolff's law describing the remodeling of the osseous structure and density in an optimization process to the load regimen experienced by the bone. The involved process of **mechanotransduction** refers to mechanical signals such like forces being converted to biochemical signals in cellular signaling involving steps such as mechanocoupling, biochemical coupling, signal transmission, and cell response reflecting the inseparable interaction of biology and mechanics. It has been found that only cyclic loading can induce bone formation [Duncan and Turner, 1995] and the bone remodeling effect depends on duration, magnitude and rate of loading, factors also common in calculating e.g. fatigue of non-biological materials like steel.

In an extension of **Wolff's law** for bone, the **Davis' law** describes that also soft-tissues remodel along imposed mechanical demands including fibrous collagenous connective tissues such as ligaments, tendons and fascia [Frost, 2003]. Like with bone, the mechanical stimulation can fall into 4 categories, a) a level of insufficient mechanical challenge and subsequent loss of soft-tissue properties, such as the ones studied during space-flight, b) a low level sufficient for maintaining the status quo, c) a level of optimal training stimulus, succeeded by d), a level leading to overload or damage leading to edema and fibrosis.

This concept of mechanical load thresholds for maintaining, losing or gaining tissue was already introduced before for bone [Frost, 2003] referring to it as the **Mechanostat** or **Utah Paradigm of Skeletal Physiology**. For bone, thresholds values for stress and strain levels leading to bone loss, adaptation, gain or fracture as a result of (over-) load (modelling), normal use or disuse (remodeling) has been established for different bones such as the tibia or skull (see Fig 2). For instance, the modeling threshold referring to the mechanical stimulus leading to a gain in bone density is 1500  $\mu$ strain for the tibia and 250  $\mu$ strain for the skull, with  $\mu$ strain being a dimensionless unit for the normalized deformation (elongation/compression) with 1000  $\mu$ strain referring to a 0.1% change in elongation. Feeding such thresholds into finite element computer simulations of loaded bones and implants has allowed the in-silico study of bone remodeling effects of various implant designs.

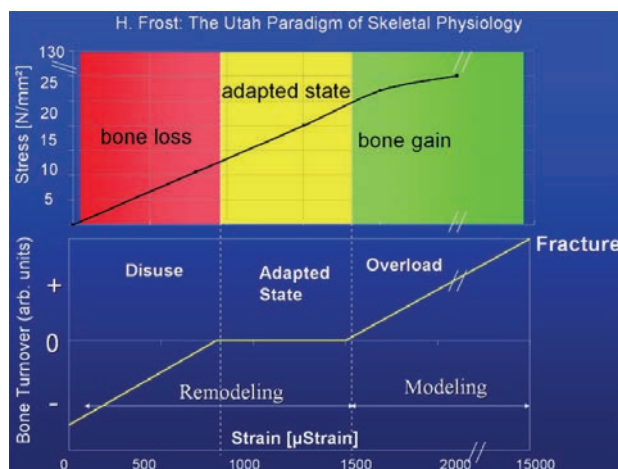


Figure 2: The Mechanostat model defining four regions and thresholds of elastic bone deformation and corresponding (re-)modeling response or fracture.

## 3.2 Stress shielding

**Stress shielding** describes the reduction in bone density (osteopenia) due to mechanical stress removed or reduced below physiological levels or in other words, below the strain thresholds leading to bone loss as established by the Mechanostat. In orthopaedic surgery, stress shielding can be introduced by the resection of bone and the implant. The implant may be too stiff [Mellon and Tanner, 2012], a biomaterial's property described below and referring to a relatively too low elastic deformation compared to the periprosthetic bone, a condition caused either by the material, the shape or size of the implant. Stress shielding may also be caused by the implant being incorrectly positioned or wrongly designed. Stress shielding associated bone loss may lead to mid- or long-term loosening of an initially stable implant and may require revision surgery.

## 3.3 Micromotion and implant fixation

**Micromotion** describes the relative cyclic motion between bone and implant during dynamic loading and is thus a phenomenon of kinetics and biomechanics. At the interface between bone and implant, there is always some level of relative motion depending on the loading scenario (activity, patient characteristics) and e.g. on the implant shape, bone/implant friction prior to osseointegration or the level of osseointegration combined with the stiffness of the surrounding bone and implant.

This level of **micromotion** is particularly important for the peri-implant bone healing during the direct post-operative phase when a mechanical stimulus is required for bone remodeling and formation at the bone/implant interface to foster osseointegration and secondary mechanical implant stability. When micromotion is too high, and such thresholds have been estimated at relative motion exceeding 150  $\mu\text{m}$  [Pilliar et al., 1986], instead of bone fibrous tissue will form at interface, preventing osseointegration and leading to mechanically unstable implant and aseptic loosening.

One biomechanical way to prevent excessive micromotion beyond implant design is achieving high initial stability by seating the implant well like e.g. the uncemented hip stem with sufficient impact force during surgery (without causing periprosthetic fractures).

## 3.4 Gait analysis or knee kinematics

Another example for clinical biomechanics is the kinematic analysis of knee motion which has contributed much to the understanding of natural knee function, designing total knee arthroplasty implants and performing knee replacement surgery, e.g. by optimal ligament balancing. Much of today's knee kinematic knowledge is derived from in-vivo 3D video fluoroscopy where computer-based matching of 3D anatomy and implant models (called registration) with bi-planar sequential video fluoroscopy images create the 3D kinematic path of femur and tibia during motion. One way to visualize this is to observe where the femur on tibia contact points are located during knee flexion (Fig. 3).

**Natural knee kinematics** is characterized by a combination of rolling (rotation) and sliding (translation) motion creating a so-called **virtual pivot point** which is moving and thus instantaneous (as opposed to a fixed pivot hinge). Observing the tibiofemoral contact points, the so-called screw home mechanism, the medial femoral pivot shift and posterior femoral rollback can be characterized as distinct features of natural knee kinematics.

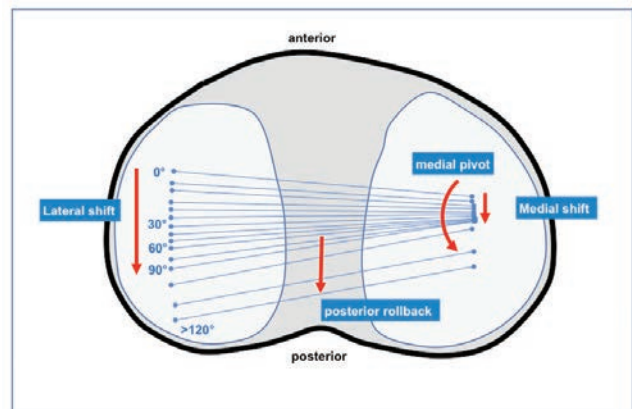


Figure 3: Degrees of knee flexion in axial view of tibial joint surface: as the knee flexes the center of the femoral condyles translates posterior.

The **screw-home** mechanism describes that the tibia rotates externally ca. 10-15deg during the final 30deg of knee extension, a mechanism which locks knee in full extension to create stable knee during e.g. the stance phase of gait. The **medial femoral pivot shift** refers to the knee kinematic phenomenon where the amount of sliding and rolling on the lateral and medial tibiofemoral contacts is asymmetric with the lateral contact point moving posterior during flexion 3 to 4 times further than on the medial pivot point, creating in effect a pivotal movement. The fact that during flexion both medial and lateral contact points move posterior as a result of rolling is the characteristic **posterior femoral rollback**.

This complex kinematics is governed by the bony anatomy of the natural joint with the lateral and medial condyles having different radii and the soft-tissues involved such as the shape of the medial and lateral menisci, the cruciate ligaments, co-lateral ligaments, the capsule and myotendinous units, all affected or even removed during total knee arthroplasty. Thus, after knee replacement, the kinematic characteristics of the natural knee are less pronounced or lost like the screw-home mechanism or can even be reversed when instead of a medial pivot shift a lateral pivot is overserved, or instead of roll-back so called **paradoxical forward motion** takes place during high flexion [Clary, 2013]. Such non-physiological kinematics can be a reason for patients being unsatisfied with their knee replacement.

## 4. Biomaterials

The definitions of what constitutes a biomaterial have expanded over the time with the advances in tissue engineering. A very broad definition of a biomaterial refers to any substance that has been engineered to interact with biological systems for a medical purpose including a therapeutic or a diagnostic one. Some definitions specify the biomaterial substance as a synthetic or non-viable natural material which may include processed grafts. The general definition includes materials with a short-term biological contact with skin or mucosa, but in research the definition is often limited to materials intended to remain inside the body for a longer time period.

Biomaterials are in physical, chemical and biological interaction with the biological system and host tissue, and based on these interactions and reactions, biomaterials can be categorized for instance as **toxic**, **bioinert**, **bioactive** or **biodegradable** [Williams, 1999] with the last three also being summarized as **biocompatible**. A toxic biomaterial is contradictory as the material kills cells in

contact with the implant. A bioinert biomaterial in the pure sense of its definition produces no response by the body but as there is always some interaction and a bodily response, bioinert refers to materials with **minimal** effect on the body. A bioactive biomaterial encourages a desired and advantageous response from the body which may depend on the location of the implant in the body. A biodegradable biomaterial breaks down in the body to non-toxic components or compounds which can be excreted by the body.

Common forms of interaction between biomaterials and the body include corrosion, especially of metals changing their properties and releasing metal ions, or protein absorption of e.g. polymers degrading their properties.

In the context of biomaterials, the body's living, natural materials are also studied to understand the basis of their chemical, physical and biological interactions. In an orthopaedic context, the properties, in particular the biomechanical characteristics of bone, cartilage, tendon, ligaments and meniscus are studied at macro- and microscopic level.

4.1 Mechanical properties of biomaterials

Materials and biomaterials can be categorized into four basic groups based on their structure at molecular and atomic level: metals, ceramics, polymers and composites. These can be distinguished also by their characteristic mechanical properties so that understanding the related metrics is fundamental for understanding biomaterials.

Many essential biomaterial's properties are derived from how the material deforms and eventually fails (breaks) under load. These properties are studied in standardized laboratory tests to derive comparable metrics via e.g. the so-called stress-strain curve during quasi-constant loading. As previously defined stress  $\sigma$  is the force per unit area [N/mm<sup>2</sup>, MPa] and strain  $\epsilon$  the relative deformation [%]. Thus, the normalized parameters derived from this test characterize the material for comparison and feed into biomechanical calculations for implant specific dimensions and loads.

The ratio between stress and strain is called the "**Young's modulus**" or modulus of elasticity E and describes the stiffness of a material. For example a metal-alloy commonly used for hip or knee implants like Cobalt-chrome (CoCr), E= 230 GPa which compares to cortical bone with E= 7-25GPa and cancellous bone at E= 0.1-1.0 GPa. The much higher stiffness of CoCr and most metals in general shows the potential for stress shielding peri-prosthetic bone as the metal components tend to carry the load and not deflect sufficiently to transfer loads onto the surrounding bone unless well designed. Various titanium alloys with moduli ranging between E= 55-100 GPa are thus also popular materials for implant designs

to reduce potential stress-shielding effects.

Another distinct parameter derived from the stress-strain curve is the **ultimate strength**, the maximum stress at failure (breakage). Although implants are always designed with a large safety margin below the ultimate strength, the value is relevant to calculate suitable dimensions or accept or rule out certain materials' choices for a given dimensions, e.g. a screw. With the ultimate strength of e.g. a typical medical grade stainless steel (316/316L) at 520-680 GPa and for CoCr alloys reaching between 600-1140 GPa components such as screws or fracture plates can safely be designed smaller or thinner with CoCr.

Another crucial biomaterial property derived from the stress-strain curve is its **ductility** (or opposite characteristic, **brittleness**) which refers to the extent to which a material deforms before it breaks. Material deformation under load can be **elastic** (recoverable after load removal) or **plastic** (permanent). The **yield strength** is an important parameter defining the stress at which a material begins to deform, not only elastically but plastically, and thus permanently and which may sacrifice the functionality of an implant. The dependency of elastic and plastic behaviour on time, temperature and the rate of loading under cyclic conditions is called **viscoelasticity** (also includes **creep** under constant load), a typical and important property of tendons and ligaments. In bone cement, creep occurs at body temperature and can be advantageous as it leads to the so-called stress relaxation.

Fatigue is the weakening of a material caused by any repeatedly applied loads (e.g. gait cycles). **Fatigue strength** is the maximum stress a material can resist failure under a given dynamic load regimen and is (much) lower than the ultimate strength established for a single, quasi-static load. Designers choosing a suitable biomaterial and calculating the required dimensions find the biomaterial's fatigue strength from standardized tests producing the so-called stress-cycle (S-N) curves where the magnitude of a cyclic stress (S) is plotted against the log-scale of cycles to failure (N).

Another biomaterials' property relevant in various orthopaedic applications, e.g. considerations for the acrylic bone cement compositions, is **fracture toughness** which refers to the ability of a material to resist fracture through crack formation or propagation. One metric to quantify this characteristic for comparison is the **work of fracture** or derivable from it the **stress intensity factor K<sub>Ic</sub>** [MPa·m<sup>1/2</sup>].

Which of these, or other properties such as **hardness**, **wettability** or **wear resistance** matter most in choosing, composing or dimensioning the right biomaterial depends on the application. Implants for total hip or knee arthroplasty must be thin and light while carrying high cyclic loads without deformation or failure so

Table 1: Typical Young's modulus and ultimate strength values for selected biomaterials and bones.		
Bone	Young's modulus [GPa]	Ultimate strength [MPa]
Bone (cortical)	7-25	50-150
Bone (cancellous)	0.1-1.0	1-10
Biomaterial	Young's modulus [GPa]	Ultimate strength [MPa]
Stainless Steel (316/316L)	210	520-680
Cobalt chrome	230	600-1140
Titanium alloy (Ti-24Nb-4Zr-7.9Sn)	55	570-755
Bone cement	2.4	40-60
UHMWPE (solid polyethylene)	0.6-1.2	20-40

that fatigue and ultimate strength are most crucial. For a suture material, fatigue and ultimate strength seem less important, as failure would likely occur via pull-out through the soft-tissue rather than rupture of the suture. Here a high Young's modulus defines the handling properties.

Besides a material's **bulk properties** described above, biomaterials derive and influence specific relevant properties via their **structure** such as **porosity** (at macro- and micro-level, inter-connectivity), e.g. in porous metals, **surface topography** (at macro-, micro- or even nano-level such as scales or surface roughness to reduce biofilm formation and infection) or combine properties by **coating** a biomaterial onto a substrate.

## 4.2 Common Biomaterials

Following the four basic material categories – metals, ceramics, polymers and composites – some common biomaterials are discussed.

### Metals

**Metal** biomaterials are all special alloys, a term which refers to a mixture of different metals or a mixture of a metal with another element such as carbon, all forming metallic bonds with the atoms in a crystalline lattice. Metal alloys are highly complex systems and may exhibit different phases similar to a composite material. They can be thus tuned regarding their desired properties (metallurgy). In general, metals have a high Young's modulus (stiff), exhibit a high fatigue strength and mostly behave ductile which means they plastically deform (an advantageous property for molding implants such as e.g. fracture plates into shape or in service to prevent catastrophic breakage).

The major metals used in orthopaedics are alloys of stainless steels, cobalt chrome and titanium (see Table 1). In stainless steel alloys, the presence of chromium causes a chromium oxide surface layer preventing further corrosion. CoCr alloys are low or free of Nickel, important for patients with nickel sensitivity. Titanium alloys, especially those of TiNb and TiMo have low Young's moduli to get closer to the stiffness of bone and prevent stress shielding. Porous metals such as titanium alloys or tantalum can even match the stiffness of cancellous bone. In recent years the adverse local tissue reactions (ALTR) around metal-on-metal (MoM) hip arthroplasties and the spread of modular implants such as hip stems with modular head-neck junctions have put new emphasis on the tribo-corrosive properties of metals.

### Ceramics

A ceramic is an inorganic compound, non-metallic, solid material comprising metal or non-metal atoms, primarily held in ionic and covalent bonds. The crystallinity of ceramic materials ranges from highly oriented to semi-crystalline or even completely amorphous, e.g., (bio-)glasses.

Bioceramics can be divided into 2 major groups. Bioinert ceramics are mainly zirconia ( $ZrO_2$ ) and alumina ( $Al_2O_3$ ) or combinations thereof, such as zirconia toughened alumina as used for articulating bearing surfaces in hip, shoulder and knee replacements. Bioactive ceramics are mainly hydroxyapatite (HA), such as the mineral phase of natural bone and tricalcium phosphates (TCP) and their composites to tune their strength and resorption properties to the

application.

Ceramics, as a bearing surface against each other and against polyethylene, have been in long-term successful clinical use. They benefit from the smoother surface roughness, superior hardness creating a scratch and third-body wear resistant articulation surface and their higher wettability, all causing very low wear rates of the ceramic and also lower wear of polyethylene if paired against it. Furthermore, ceramic bearings release no metal ions, have no allergenic risk, lower fretting corrosion at the modular neck and a pathogenic reaction to ceramic wear particles is unlikely. Reducing ceramic grain size and toughening with adding  $SrO$ ,  $Y_2O_3$  and  $Cr_2O_3$  to the compositions has reduced early incidents of brittle ceramic component fracture.

Bioactive ceramics are used in six major applications: 1) bulk implants, that is space filling implants, 2) porous implants when used as implants for ingrowth or 3) scaffolds for tissue engineering, 4) granules used to supplement or to replace autologous bone graft such as in impaction grafting, 5) coatings which can be plain hydroxyapatite ( $HA - Ca_{10}(PO_4)_6(OH)_2$ ), tricalcium phosphate (TCP –  $Ca_3(PO_4)_2$ ) or HA+TCP (also called biphasic calcium phosphate – BCP) and 6) as injectables where the calcium phosphate, with or without some calcium sulphate (plaster of Paris –  $CaSO_4$ ) and other additives, is mixed in the operating theatre, injected into the body and sets in situ. The degradation rate depends on the crystallinity of the ceramic phases and their relative amounts. Degradation rates increase from HA, to TCP, to calcium sulphate. The required degradation rate depends on the clinical application.

### Polymers

**Polymers** are a class of materials defined by comprising large molecules, named macromolecules, composed of many repeated subunits. Their consequently large molecular mass and way of molecular order produce a broad range of physical properties, including toughness, viscoelasticity, and a tendency to form glasses and semicrystalline structures rather than crystals.

Polymers typically used in orthopaedics are primarily ultrahigh molecular weight polyethylene (UHMWPE), polymethylmethacrylate (PMMA), other methacrylates, polyesters, poly(glycolic acid) and poly(lactic acid) and hydrogels.

For the use of UHMWPE as a bearing surface, the wear resistance, oxidation resistance, fatigue strength and fracture toughness have been improved during the last 25 years by a variety of manufacturing steps with the most effective having been molecular cross-linking, to increase wear resistance and adding anti-oxidants such as Vitamin E to increase the oxidation resistance (Gu, Li et al. 2014).

PMMA is a thermoset polymer which in clinical application is created through exothermic polymerization of a powder phase, pre-polymerised polymethylmethacrylate beads plus liquid benzoyl peroxide which initiates the polymerization. PMMA is combined with a radiopacifier in the form of barium sulphate or zirconia. PMMA bone cement is used to fix (grout, not glue) joint replacements in place or is used to space fill and thus stabilize osteoporotic bone against fracture such as in spinal vertebroplasty and kyphoplasty.

Desired properties of PMMA bone cement are fatigue strength, resistance to crack initiation or propagation, and, the long, predictable window of workable viscosity in the operating theatre



before setting. Vacuum mixing to reduce weakening voids, retrograde cementing and cement pressurization during the hardening phase for high cement-bone interdigitation, have been identified as crucial surgical steps for an optimal PMMA mantle.

The main degradable polymers in clinical use are the thermoplastic Poly(lactic acid) PLA and Poly(glycolic acid) PGA. Chemically these break down into lactic and glycolic acid, which the body breaks down to  $\text{CO}_2$  and  $\text{H}_2\text{O}$  and is excreted. In orthopaedic surgery PGA is used in resorbable sutures due to the fast degradation of PGA within the body. Due to its lower degradation rate, PLA is used for fracture fixation in low load bearing applications under the form of internal fixation plates. The current challenge with degradable polymers are their low strength and too fast degradation rate for e.g. fracture healing. In attempts to improve the strength, fibre reinforcement and ceramic reinforcement have been used [Bleach, Nazhat et al. 2002; Huttunen, Törmälä et al. 2008]. PLA/PGA composites are also available as resorbable meshes and screws for bone augmentation. Recently PLA has become popular as a biopolymer suitable for 3D printing. In orthopaedics the application as a template for pre-operative contouring of fracture plates has been shown.

### Composites

A composite is a material made from two or more constituent materials with significantly different physical or chemical properties that, when combined, produce a material with characteristics different from the individual components. The individual components remain separate and distinct within the finished composite. Living bone is a composite material by nature combining collagen and HA to create an extremely tough, yet lightweight, adaptive and multi-functional material.

A major type of composite biomaterials used are polymers reinforced with ceramics such as glasses, HA or TCP for e.g. arthroscopic interference screws. Also in use are polymers reinforced, with another polymer or the same polymer but in another form such as drawn fibres in an amorphous matrix of the same polymer. One example of this is the PLLA in PLDLA used in some degradable fracture fixation plates.

Carbon-reinforced PEEK (Polyether ether ketone) is a polymer which has demonstrated good wear characteristics in experimental wear simulation in simple geometry pin-on-plate studies and in total hip joint replacement, but which may be less suited for low-conformity designs such as knee replacement.

With composite material compositions allowing in theory the creation of application-optimized biomaterials, including functionality such as controlled drug release, sensing, or self-repair, many novel composite biomaterials have been explored [Tanner, 2010]. One example of these manifold efforts are e.g. carbon nanotube, graphene and boron nitride nanotube reinforced bioactive ceramics for bone repair which have made great advances but are not yet available in orthopaedic clinic.

## 5. Conclusions

Orthopaedic surgery placing an implant into the body can only be performed successfully when the two interacting factors are considered and understood. One factor is how the implant is loaded, thus the biomechanics, and the other factor is the material the implant is made of and its properties, thus the biomaterials. While much of this is considered during design, development and testing, the orthopaedic surgeon is faced with many implant choices and the decisions for the optimal design, size, placement and fixation are all affected by the biomechanics and biomaterials interactions described here.

### Questions

1. In biomechanics, what is the difference between kinematics and kinetics?
2. What is stress shielding and how can it be reduced?
3. Which kinematic behaviour of the natural knee contributes to joint stability during the stance phase of gait?
4. What is the difference between a ductile and a brittle biomaterial?
5. How can advantageous properties of different biomaterials be combined to best serve clinical demands? Give one example.

### Answers

1. Kinematics describes the motion of objects independent of the forces that originated it. Kinetics (or dynamics) describes the interactions between forces and moments, and the motions caused taking into account the translational and rotational inertia of the moving objects.
2. Stress shielding describes a loss of bone (osteopenia) due to mechanical stress removed or reduced below physiological levels by an implant. Stress shielding can, for instance, be reduced by matching the stiffness of the implant and material to the surrounding bone or designing the implant to transfer load to the bone instead of shielding from it.
3. During stance, the knee is at or near full extension and, as defined by the tibiofemoral bony morphology and soft-tissue (ligaments, meniscus) properties, the tibia rotates externally ca. 10–15deg during the final 30deg of knee extension "locking" the knee in full extension. This kinematic characteristic is called "screw-home mechanism".
4. Ductility and brittleness refer to the extent of deformation, elastic and plastic, a biomaterial undergoes before breaking under load. A ductile material deforms much before failure while a brittle material shows small deformation before failure. Most metals are usually ductile so that they can be molded into shape. Most ceramics behave usually brittle and instead of deforming near failure loads, may break by e.g. bursting.

5. Advantageous properties of different biomaterials can be combined by coatings or creating a composite biomaterial. One example would be the use of a mechanically strong and elastic titanium hip stem coated with porous HA to enhance osseointegration. Another example is an arthroscopic interference screw, made composite of PLDLA polymer and calcium-phosphate, to make the screw strong and resorbable.

---

### References

1. Bleach, N. C., S. N. Nazhat, et al. (2002). "Effect of Filler Content on Mechanical and Dynamic Mechanical Properties of Particulate Biphasic Calcium Phosphate Polylactide Composites." *Biomaterials* 23(7): 1579-1585.
2. Clary CW, Fitzpatrick CK, Maletsky LP, Rullkoetter PJ. The influence of total knee arthroplasty geometry on mid-flexion stability: an experimental and finite element study. *J Biomech.* 2013 Apr 26;46(7):1351-7.
3. Claire L. Brockett, Silvia Carbone, John Fisher, and Louise M. Jennings PEEK and CFR-PEEK as alternative bearing materials to UHMWPE in a fixed bearing total knee replacement: An experimental wear study *Wear.* 2017 Mar 15; 374-375: 86-91.
4. Currey, J. D. (2006). *Bones: Structure and Mechanics*, Princeton University Press.
5. Duncan, RL; CH Turner (November 1995). "Mechanotransduction and the functional response of bone to mechanical strain". *Calcified Tissue International.* 57 (5): 344-358.
6. Ellenbecker, Todd, "Effective Functional Progressions in Sport Rehabilitation", *Human Kinetics* 2009, ISBN 0-7360-6381-1
7. Frost, Harold "New targets for fascial, ligament and tendon research: A perspective from the Utah paradigm of skeletal physiology" *J Musculoskel Neuron Interact* 2003; 3(3):201-209
8. Gao C, Feng P, Peng S, Shuai C. Carbon nanotube, graphene and boron nitride nanotube reinforced bioactive ceramics for bone repair. *Acta Biomater.* 2017 Oct 1;61:1-20
9. Huttunen, M., P. Törmälä, et al. (2008). "Fiber-reinforced bioactive and bioabsorbable hybrid composites." *Biomedical Materials* 3(3).
10. Mellon, S. and K. E. Tanner (2012) "Mechanical Adaptability of Bone in Vivo and in Vitro – A Review", *International Materials Reviews* 25(5), 235-255
11. Nordin, M, Frankel, VH. *Basic Biomechanics Of The Musculoskeletal System*. Philadelphia: Lippincott Williams and Wilkins, 2012. 4th ed.
12. Pilliar RM, Lee JM, Maniopoulos C. Observations on the effect of movement on bone ingrowth into porous-surfaced implants. *Clin Orthop Relat Res.* 1986;208:108-113
13. Tanner, K. E. (2010). *Hard tissue applications of biocomposites*. *Biomedical Composites*. Ed L. Ambrosio. Cambridge, UK, Woodhead Publishers.
14. Williams, D. F. (1999). *The Williams Dictionary of Biomaterials*. Liverpool, Liverpool University Press



*Prof. Andrew Judge*

Musculoskeletal Research Unit, Translational Health Sciences  
Bristol Medical School – Bristol, United Kingdom  
andrew.judge@bristol.ac.uk

## Study Design & Statistics

The aim of this lecture is to take you through epidemiological study designs. We start with a research question, which is the most important aspect of study design. Then move on to the concept of confounding, before going through the different types of epidemiological study designs (e.g. Randomised Controlled Trials, Cohort, Case-Control, Cross-sectional studies). We will go through different ways of describing and displaying data using graphs and tables. Finally, we will finish by going through sample size calculation. We will take you through the key elements of powerful calculations and how to estimate sample sizes of a study.

### 1. Research question

This is the most important aspect of any study – if you get this wrong, then everything else you do from then onwards will also be wrong. So how do you choose a good research question? We have this acronym called FINER (Feasible, Interesting, Novel, Ethical, Relevant). Feasible relates to the sample size you might need for your study. If you need 30,000 people to do a study it will be very expensive, so you may need to re-think your question and have a smaller sample size. Do you have the right technical skills, which means having the right laboratory equipment, imaging equipment, the team with the necessary expertise (e.g. qualitative researchers, health economists, statisticians, clinicians etc), and so on? If not, you need to collaborate with other teams. How much time will it take to do your study? If it will take 5, 10 or even 20 years to follow up patients, it will take too long to do. Then, think about the scope of the study. Everyone always has a too big scope, a too big questionnaire, asking too many questions and collecting data on too many outcomes. It's all about narrowing the scope down to a more refined specific question.

The question has to be interesting to both you and the funder, otherwise they won't support you. It has to be novel, but then very rarely it is a study truly novel. If you are confirming an existing finding in the literature, or refuting existing evidence where you think a previous study has been designed badly, you need to do it properly. It may be worth to take research forward where there is an existing body of evidence and new questions have arisen. If you do a proper literature review and spend time seeing what has been done before, then usually someone else will have addressed or answered that question at some point. You also need to have ethical approval for the study. Finally, relevance is crucial, as funders want to be able to translate research findings quickly into clinical practice.

So how do you write down your own research question? We use the PICO acronym (Population, Intervention, Comparator, Outcome). Population is about *who* do you want to study. Are all patients getting

hip replacement surgery? Just men or women only? Do those aged over 50 show signs of Osteoarthritis? What hospital or area are you going to recruit them from? You need to be specific and narrow down the population you are selecting for your study. Intervention / Comparator, could be old versus young, men versus women, drug A versus drug B, surgery compared to placebo. We also call this exposed or not exposed in observational studies. If it is a drug, then you need to describe what dose, how long will it be taken for, and so on. The most important part is the outcome. It might be mortality, a patient reported outcome (e.g. EQ5D, WOMAC, OKS etc), or a time to observe outcome. In any case, you must define it carefully. For example, in the case of mortality, is it at 90-days or 1-year, is it an all-cause mortality or cause-specific like cardiovascular disease.

### 2. Confounding

Having defined your research question, you have an exposure of interest, and a primary outcome of interest, and you want to see if there is an association between them using some study design. If you use an observational study design, then you need to consider confounding.

Confounding is a third variable, which if controlled in a regression analysis, may explain the association between exposure and outcome. Below are some examples:

Example 1: Exposure (E) is coffee drinking (heavy versus light coffee drinking). The outcome (O) is Parkinson's disease mortality (variable or not). When you do the crude unadjusted analysis, you find that heavy coffee drinkers are significantly less likely to die from Parkinson's disease. But is there a third confounding variable (C) that could explain this association? A confounder might be smoking. To be a true confounder, there are three criteria that must be satisfied: (i) This variable (confounder) must be causally associated with the disease outcome. We know from previous studies in the literature that smoking is protective of Parkinson's disease mortality. (ii) The confounder must be associated with the exposure, but not causally. We know from previous studies that there is a strong association of smoking and coffee drinking, where heavy coffee drinkers are more likely to smoke. But this is not causal as drinking much coffee does not cause people to smoke. (iii) The confounding variable must not lie on the causal pathway. If the exposure causes the confounder, which then causes the outcome, the analysis should not be adjusted for it. In this example, smoking is not on the causal pathway. When we re-do the analysis adjusting for this confounder, we find that there is no longer an association between coffee, drinking and Parkinson's mortality, and that it's not statistically significant.

Example 2: E = drinking alcohol (heavy versus mild drinking), O =

lung cancer mortality. In an unadjusted crude analysis, we see heavy drinkers have an increased risk of lung cancer. The confounder in this case is smoking. In the adjusted analysis the association between drinking and lung cancer is no longer significant.

Example 3: E = Smoking (yes or no), O = Cardiovascular disease (yes or no), C = Atherosclerosis (yes or no). Is Atherosclerosis a confounder? No – it is on the causal pathway. Smoking causes Atherosclerosis, which causes Cardiovascular disease. Thus, the analysis should not be adjusted for this as a confounder.

It is important to read the literature to identify all potential confounders for your research question. If you have not collected the data on potential confounders, then you cannot later adjust for them in the analysis, and this may explain your study's findings.

## 3. Study Design

There are two main types of study – interventional and observational. In an interventional study, we intervene to alter the course of disease, (e.g. by introducing a new treatment). Whereas in an observational study we just observe what happens.

### 3.1 Randomised Controlled Trials (RCT)

This is the interventional study design. To start with you need to define the population of interest (as in the PICO for the research question). From this group, you will then identify which patients are eligible to take part on the trial, based on your inclusion and exclusion criteria. Patients contacted need to have informed consent to take part in the study. These patients are then randomised to be in either the intervention group, or the control group. The randomisation means that each person has an equal chance (probability) of being selected to be in either the intervention or the control groups. Baseline measurements are taken, and patients are then followed up to collect data on outcomes. An RCT is the gold standard study design, and the main reason for that is that there should be no confounding. This is due to the randomisation: the only way the two groups will differ is if they get treatment or control. They will be balanced in respect of all other confounding factors. e.g. mean age, proportion of women, ethnicity groups, body mass index, etc should all be same in both intervention and control groups. This includes not just confounders that are known, measured and collected, but also unknown and unmeasured confounders.

Other important parameter to ensure in an RCT is 'concealment of allocation'. What this means is that the person who is doing the randomisation, cannot influence who is allocated to treatment or control. For example, if ordered opaque envelopes are used, a clinician may be tempted to hold the envelope up to a light to see what treatment allocation is and be able to influence this by allocating a sicker patient to intervention. If this happens it will cause a selection bias. Therefore we use computer-generated randomisation at a distant site, not involved in the study. Importantly, we need to use an Intention-To-Treat (ITT) analysis, which analyses people in the groups as they were at the point of randomisation. If a patient switches groups (e.g. from control to intervention), doesn't complete the follow-up, drops out or doesn't comply with the treatment, the study is still accurate. If there is missing data on outcomes, you will need to impute the outcomes, so groups are the same sample size as they were at

the point of randomisation. If instead we did a completers or on-treatment analysis of only those who comply or complete the follow-up, this will introduce a bias to the study. This is in the form of selection bias, known as loss-to-follow-up bias. If loss-to-follow-up is similar in both sections of the trial (smaller than 5%) then this is unlikely to have much effect. But, if it is differential, and loss-to-follow-up is higher in one group, and this is related to the outcome (e.g. drug side effects), then selection bias may be introduced. ITT analyses help to avoid this. The final biases relate to measurement error in either treatment or outcome. To avoid this, we use patient and assessor blinding. If the patient works out, gets the active drug or the placebo, takes other medications or treatments, there is a bias. Likewise, if the person assessing outcomes is aware of treatment allocation, it may influence the way outcomes are recorded. Therefore, proper patient and assessor blinding are important to avoid measurement errors.

If all the above is taken into consideration, then a large well conducted RCT is the gold standard, as we minimise the possibility of confounding, selection bias, and measurement error. Then we can begin to consider that the RCT study findings may be causal. The main limitation of the RCT is the lack of generalisability. The type of people that are selected to take part in trials are not necessarily representative of those in the general population who would be offered treatment. Take for example bisphosphonates for treatment of osteoporosis. Adherence to therapy in trials is much higher than in the general population. Patients in trials are also less likely to have co-morbidities and contra-indications, due to strict inclusion and exclusion criteria. So even if a drug or treatment is shown to be clinically effective in a trial setting, it may not be when introduced to the wider general population.

### 3.2 Prospective Cohort study

This is an observational study design. We start by defining the population of interest. The population is normally defined by some common characteristic (e.g. all went to the same school, were born in the same year, etc). At the start of the study patients must be disease free, meaning that they cannot have the outcome of interest. At baseline, we measure a wide range of exposure and confounding variables. Patients are then followed up until they get the outcome of interest.

It is the strongest type of observational study design because the temporal sequence of events is clear – cause precedes effect. It is also the best observational study if you have rare exposures. Further strengths are that the cohort study can be used to answer many different research questions. The limitations are that the sample sizes are usually very large, with long follow-up, making them expensive and time-consuming. An alternative to the prospective cohort study, is to consider a retrospective (historical cohort) study design. Here we use existing data (e.g. joint registries, hospital admissions, primary care datasets), whereby we start in the past when patients are disease free, measure and collect exposures, and follow patients to the present day to see associations with outcome. Limitations of this are that such datasets were not typically designed for research purposes, and so may lack data on important confounders, but they will be quicker and cheaper to do. Further limitations are in respect of confounding, and the potential for measurement error in either exposure or outcome. There will also be loss to follow up over the duration of the study, so again we need to consider a possibility of selection bias. In an observational



study we are only assessing associations, not causality, as there will always be potential limitations in respect of bias and confounding.

3.3 Case Control study

This observational study design is best used for rare outcomes. People are selected for inclusion in the study based on their outcome and data on past exposures is considered. The main limitation and difficulty is how to select controls who don't have the outcome. Selecting the wrong controls can introduce selection bias. For example, in a study about the association between alcohol consumption and liver disease, if we choose our cases as patients with liver disease admitted to hospital, and hospital controls who don't have liver disease, this could introduce a bias. The reason being that drinking is one of the most common reasons for hospital admissions, and the population of patients in a hospital setting are more likely to be drinkers than in the general population. Hence, with these controls, we may underestimate the association with outcome. The other problem with this study design is measurement error as we are asking people to recall past exposures. If for example we are looking at the association between having leukaemia and living near power lines, the parents of leukaemia patients may say they live close to power lines, whereas measure of the actual distance would not show closeness. Likewise, if a researcher is interviewing patients for a study on sun cream use and skin cancer, if the researcher knows who the cases and controls are, it may bias the way he collects data on past exposure, being more detailed for those cases with outcome. Analyses will also need to attempt to adjust for confounding. In this design, it is also unclear whether cause proceeds effect, and the temporal sequence of events is less clear than in a cohort study.

3.4 Cross-sectional study

In this observational design, there is a single point in time (a snap shot). Data on exposures and outcome are all collected at the same point in time, and hence the temporal sequence of events is unclear. For example, is cannabis consumption associated with schizophrenia, or are schizophrenics more likely to smoke cannabis? In this study design we can't define if cause proceeds effect. Aside from this, it is very similar to a cohort study at baseline, because you identify your population of interest, take a sample of these to include in the study, and collect baseline data on exposure and outcome. This study design is very useful for estimating disease prevalence, but if doing so, you must be very careful in how you define your study population. Say for example you want to estimate the prevalence of Chlamydia. If you recruited patients attending a Genito-urinary medicine clinic, then you would only measure the prevalence of symptomatic disease, in those who have sought treatment. There will be people whose disease is asymptomatic, so you need to sample from the wider general population.

You may want to estimate the prevalence of hip pain that requires surgery. If you sampled those in a hospital setting, you would underestimate the true prevalence, as these are only the people who have sought help for their symptoms and managed to get access to surgery. There will be people with severe pain that do not seek help from a GP or surgeon, and have not accessed services, even though they are in clinical need. There will be people in need that have sought help, but there are barriers to them

accessing surgery.

4. Describing and displaying data

4.1 Types of data

It is important to understand the type of data obtained, as it defines how to apply statistical analysis and tells you the type of statistical test that you need to use. Table 1 describes different types of data. For example, age could be recorded as a continuous variable with age in decimal points, or discrete (ordinal) if age is rounded to years, or categorical if simplified into age groups and categorised. Age would be an ordered categorical variable as it has a natural ordering of values from high to low, unlike eye colour that is unordered.

Table 1: Types of variables

Discrete	Number of visits to the GP
Continuous	Height, weight, blood pressure
Categorical (ordered)	Social class, cigarette smoking
Categorical (unordered)	Ethnicity, blood group
Binary / dichotomous	Gender

4.2 Summarising data

We will begin with summarising a single variable on its own. If your variable is continuous (or discrete if there are a wide range of values), then you can create a table of summary statistics (e.g. mean, standard deviation, minimum and maximum values, number of observations). The mean is a measure of the average value, as a summary of the data. This is the sum of all values of that variable (e.g. age (patient 1) + age (patient 2) + ... + age (patient n) / number of observations in the sample). The median is the middle 50% of the data. If you order the variable from the lowest to highest value, the median is in the middle, whilst the mode is the most commonly occurring value. The standard deviation (SD) is a measure of variability and tells you the spread of a variable in that sample of data. For example, for age of schoolchildren, the SD would be small as there is little variation in age, whereas the age of people in a city would have a larger SD. Minimum and maximum values are useful to assess the range of values in your sample, and percentiles are helpful (the median is the 50% centile, whilst values from the 25% to 75% centiles represent the middle 50% of the data and is called the inter-quartile range). Simple descriptive statistics help you see how much missing data there is for a variable and if there are any erroneous values or outliers. For continuous data, histograms are useful to visualise the data and assess distribution (Figure 1). The range of values, the peak of the distribution and measure of central tendency are easily observed.

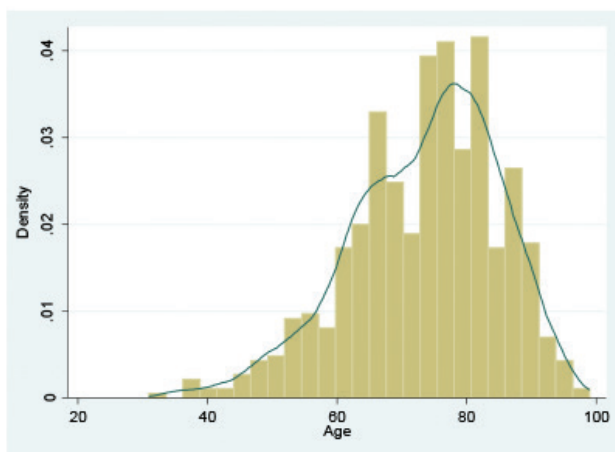


Figure 1: Histogram of age

For a categorical variable, this can be presented as a table, with the number and percentage in each category. Visually, you can present this as a bar chart (Fig. 2), with a bar for each category representing the frequency or percentage. The most common, and least common categories are easy to identify. It is best to avoid pie charts as they can be difficult to interpret.

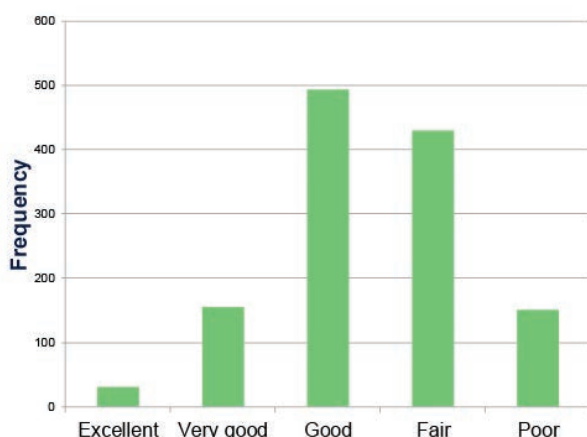

Figure 2: Bar chart of general health prior to surgery

For association between two categorical variables we should use a cross-tabulation (Table 2). By convention, the outcome is usually shown in the columns (obesity) and the exposure inserted in the rows (gender). The percentage of males and females that are obese is outlined in this table, and based on the data used as example, obesity is higher in men. Note that this does not have any statistical significance. It is just describing and understanding the data, and potential associations that may exist.

Gender	Not Obese	Obese	Total
Male	39 (32%)	84 (68%)	123
Female	99 (44%)	127 (56%)	226
Total	138 (40%)	211 (60%)	349

For comparing a categorical and continuous variable, you can use a Box-Whisker plot (Fig. 3). The function score (100 good, 0 bad) is summarised for males and females separately. The box represents the inter-quartile range (the middle 50% of the data) with the line in the middle of the box being the median. The whiskers represent

the range of values, with any points beyond this representing extreme values. Here we see that median function score prior to surgery is higher in women than men.

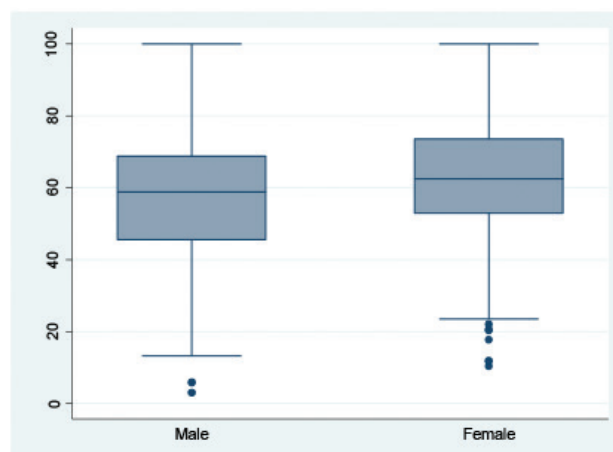


Figure 3: Box-Whisker plot of association between pre-operative function score and gender

The most accurate approach is to have two continuous variables to describe the association. We can use a scatterplot (Fig. 4). Here we look at pre-operative function score (0 good, 100 bad) against body mass index, and can see an association of higher function scores with increasing obesity, but clearly there is a wide spread to the data.

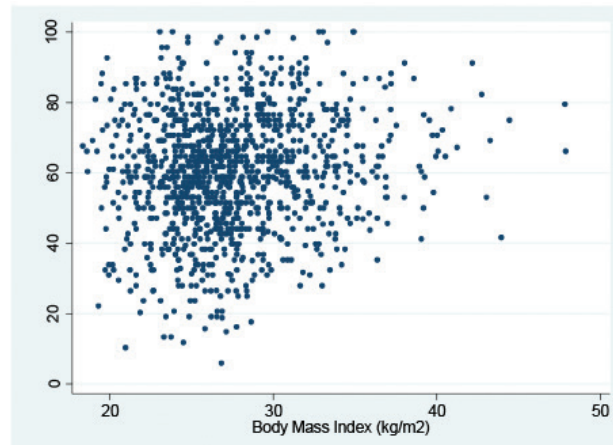


Figure 4: Scatterplot of association between body mass index and pre-operative function

### 4.3 Distributions

Figure 5 describes a perfect normal distribution. This is a really powerful tool that underpins many of the statistical tests used in medical statistics that rely upon the assumption of normality. Particularly, the outcome variable, where if this is skewed, the model assumptions underlying the test are likely to be violated. The normal distribution is described by two parameters, the mean and standard deviation. It is bell shaped, and perfectly symmetrical with 50% of the data on either side. In this case, the mean, median and mode are exactly the same value. You may have come across the value of 1.96 which is used to say that 95% of data in the distribution lies within that range (it represents the middle 95% of the area of the distribution) with 2.5% lying in the tails at either

side of the distribution) and covers ~2 SD from the mean.

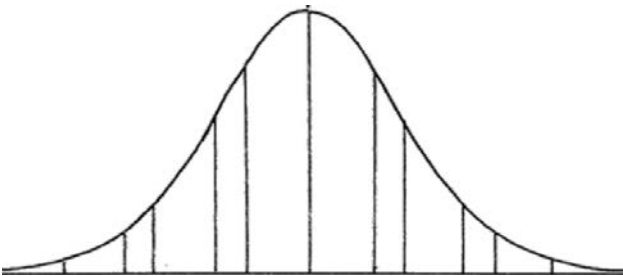


Figure 5: Normal distribution

To check the distribution of continuous variables in your own data, you can use a histogram, a kernel density, or a Quantile-Quantile (Q-Q) plot (Fig. 6). The problem with a histogram, is that it is very much dependant on 'bin' size (the width of the bars), which can alter the look of the plot depending on the sample size to be estimated for each bar. A better option is the kernel density plot. This is the red line giving a smoothed fit to the distribution by estimating the probability density function. Alternatively we can use Q-Q plot. This overlays the perfect normal distribution, with the distribution of your variable. It also chops the data into percentiles from lowest to highest across the distribution. Each point represents a percentile, and the difference of your distribution from the perfect normal distribution is shown. If all points lie on the line, it is normal. If data are skewed, points will deviate from the line.

As most of the statistical tests that we use in medical statistics are quite robust against even quite moderate departures from normality, we would not recommend using formal statistical tests for normality. Instead, just eyeball the data and look for moderate to large departures from normality. Another easy way is to compare the mean and median values. E.g. If your data are negatively skewed to the left then (mean < median < mode).

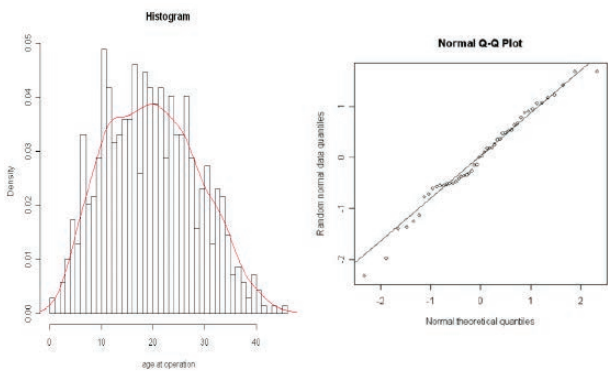


Figure 6: Histogram, kernel density and Quantile-Quantile plot of age.

5. Sample size

Sample size is a really important topic. It is relatively easy to define by using online sample size calculators. The difficulty is obtaining the information you need to give to the calculation. Before you can do a sample size calculation, you need to understand 'sampling'. This is a very important concept that underpins why we need to do medical statistics. Importantly, in each study you just have a sample of patients but you are trying to estimate the true association between exposure and outcome in the wider population. However,

you can't sample the whole population. Medical statistics are used to make inference, about what we believe is the true association in a wider population. As an example, let's look at the association between gender (exposure) and blood pressure (outcome). First, we set our null hypothesis, which is that there is no association between gender and mean blood pressure (or strictly that mean blood pressure is neither higher or lower in men and women – we don't know direction of effect). Then we use a statistical test to look for a difference in mean blood pressure between men and women. In your sample you can estimate the difference in mean blood pressure and it may be statistically significant (see table 3) and the true answer in the wider population is that you were correct – there was an association. That is what we call the 'power' of a study. By convention this is set at 80%. So theoretically, if we took 100 different samples of patients, and thereby repeated the study 100 times to estimate the mean difference in blood pressure, we would get the right answer 80% of the time. You could increase power to say 90% for a primary outcome of your study, but then the sample size required is larger. The converse of this is that 20% of the time we will get the wrong answer, whereby in our sample, we find there is no significant association, but the true answer is that there is one. So, we missed it. This is the opposite to power and set at 20%. This is known as Type II error. So that means that 1 in 5 times we will miss a significant association. In the top right corner of table 3 we have Type I error. This is sometimes called significance and is the p-value. This is generally set to be 5% (so a p-value of 0.05). This means that if we repeated the study 100 times, then 5% of the time (1 in 20) we will make a type I error by saying in our sample that there is an association, but the true answer is that there is no association. These errors should be minimised. Generally a 5% Type I error and 80% power are the minimum that would be considered acceptable. To make either of those errors smaller, sample size will need to increase.

Table 3: Possible outcomes of a study		
	Truth in the Population	
Results in the study sample	Association Between Exposure and Outcome	No Association Between Exposure and Outcome
Association Between Exposure and Outcome	Correct	Type I error
No Association Between Exposure and Outcome	Type II error	Correct

Let's also take an example of a sample size calculation:  
"We have 80% power to detect a difference in mean blood pressure between men and women of 4 mm Hg, with a 5% level of significance, using a two-sided test, where the SD is 8 mm Hg, and the required sample size in each group is 64."

As stated earlier, our outcome is *difference in mean blood pressure* and the exposure is a binary variable of gender. First of all, we need to know what the minimum clinically important difference in outcome should be. This is very hard to do. For your research questions and your sample size, you need to work with collaborators and clinicians in your team to find out what this difference should be. It has to be worked out a-priori and cannot later be changed if the sample size turns out to be too high. The next important information you need is the standard deviation of the difference in means in your population (so information on

the variability in outcome). This may come from previous research published in the literature or if not available then a pilot study (around 30 people). Once you have chosen the difference in means, and estimated the SD, this can be expressed as an effect size (ES), where  $ES = (\text{difference in means} / SD)$ . In our example above the effect size is  $4 / 8 = 0.5$ . As a general rule 0.5 is a 'moderate' effect size, 0.3 'small', and 0.8 'large'. Generally, an effect size of 0.5 represents a half SD change, and this tends to represent a clinically meaningful difference most of the time (Revicki D, et al. Recommended methods for determining responsiveness and minimally important differences for patient-reported outcomes. *J Clin Epidemiol.* 2008 Feb;61(2):102-9). An effect size between 0.3 and 0.5 would usually be considered acceptable to power a study. Power and significance we have already covered, and the minimum values as stated earlier would be 80% power and 5% significance. Following this, a 2-sided test means that we do not know the direction of effect. It could be an increase in risk or a decrease in risk. If we knew the answer we wouldn't be doing the study. This means we spread our p-value of 0.05 to both tails of the normal distribution of the difference in means (0.025 in either direction). If you had a one-sided test, you would be putting 0.05 (your type I error) all in just one direction (one side of the distribution), which requires a smaller sample size. But you should do a two-sided test in most circumstances.

Now we have all the information we need to estimate the sample size required in each group. But note that this sample size does not allow for loss-to-follow-up. We need to power the study for the sample size of each group at the end of follow-up. So, the actual sample size  $N' = (N / (1 - \text{proportion lost to follow-up}))$ . The sample size must be inflated to allow for loss-to-follow-up.

## 6. Further reading

- Hulley SB. Cummings SR. Browner WS. Grady DG. Newman TB. *Designing Clinical Research*. Third Edition. 2007. Lippincott, Williams & Wilkins.
- Kirkwood BR. Sterne JAC. *Essential Medical Statistics*. Second Edition. 2003. Blackwell Science.
- Ben-Shlomo Y. Brookes ST. Hickman M. *Lecture Notes: Epidemiology, Evidence-Based Medicine and Public Health*. 6th Edition. Jan 2013. Wiley-Blackwell.

## Questions

Study Design Options:

- a. Randomised Controlled Trial
- b. Prospective cohort
- c. Case-control
- d. Retrospective cohort
- e. Case series
- f. Cross-sectional
- g. Ecological

For each study select the type of epidemiological study design that has been used

1. Eighty-six patients consented and were randomly assigned intraoperatively to receive rotator cuff repair with or without acromioplasty. The primary outcome was the Western Ontario Rotator Cuff (WORC) index twenty-four months after surgery.
2. 2186 patients who underwent primary total hip arthroplasty between 1996 and 2005 at the University Orthopaedic Department in Geneva, Switzerland, were included. Patients were followed for up to 5-years after surgery to evaluate the effect of obesity on complications, functional outcome and satisfaction following surgery.
3. A study was conducted to examine risk factors for acute rheumatic fever (ARF) in New Zealand between 1996 and 2005. Rates of ARF were examined in relation to area factors based on the census area that included household crowding, New Zealand deprivation index, household income, and proportion of children aged 5-14 years.
4. 209 consecutive total hip arthroplasty procedures (199 patients) were performed with a metal-surface chromium-cobalt total hip implant with an articulating surface consisting of a ceramic head and an ultra-high-molecular-weight polyethylene liner. The clinical and radiological outcomes and whether or not patients had revision surgery were reviewed at an average of 21 years follow up.
5. The prevalence of rheumatoid arthritis was estimated in a national US population comprising both hospitalized and ambulatory patients. Trends in prevalence were examined over a 10-year period between 1997 and 2006.

## Answers

1a, 2b, 3g, 4e, 5f





*Prof. Ignacio Sanpera*

Hospital Universitari Son Espases,  
HUSE · Department of Pediatric, Orthopedics and Traumatology  
Palma de Mallorca, Spain  
isanpera@gmail.com

## Classification & Principles Of Childhood Fracture Treatment

Fractures in children are prevalent, with a reported incidence of 20 over 1000 children per year, and probably increasing. The estimated individual risk of sustaining a fracture before the age of 18yr it is around 34%.

Fractures in children are regarded as more benign and forgiving, given the vast periosteal capacity and their remodelling ability. Although bones in children are different from those of adults, these differences vary with age. While the bone in new-borns is highly active, the biomechanics and biological properties of an "old" adolescent resemble more to those of an adult bone.

Additionally, during the last times, we have seen an increase in guidelines promoting the surgical treatment of children's fractures; however, in most instances, no scientific evidence supports its use.

This lecture focuses on understanding the physiology of bone in children and adolescents and how we can apply these principles to manage children's fractures successfully.

### 1. Classification of childhood fractures

#### Physiology of bone and its repair in children.

From an anatomic point of view, children's bone has certain anatomical differences from adult one. First, the larger presence of cartilage, especially around the epiphysis, as ossification of these areas is incomplete. Second, the presence of the physis, formed by specialized cartilage cells responsible for the bone's growth. Lastly, the presence of a thick and very active periosteum.

The biomechanics of children's bones demonstrate a more porous bone with less resistance to stresses but a considerable ability to deform before failure. While adult bone fails in tension, the children's bone, due to its porosity, may fail in compression (buckle fracture).

Bone repair in children is characterized by its healing velocity due to the bone increased vascularity and the presence of a biological, very active periosteum with high osteogenic capacity. These facts, coupled with the limited soft tissue lesion, result in faster healing of the fractures.

Another characteristic of the young bone is its ability to remodel after malunion. Remodelling takes place by two different mechanisms: bone drifting (resorption of bone on the convexity and apposition of bone on concavity) following the laws of Delpech (approx. 25% of remodelling). However, most of it happens by asymmetrical growth of the physis and reorientation (75%). Concerning the remodelling it is important to remember that:

- It is always larger near the physis
- It is bigger when the direction of the deformity follows the plane of motion of the adjacent joint.

- Remodelling when less than 2yr of growth remain is negligible.

#### Classification of children's fractures.

The AO, following the guidelines used in their adult classification, presented an AO paediatric fracture classification (PCCF) for long bone fractures <sup>[1]</sup>. It is a universal classification that encompasses all the possible types of fractures. A recent publication showed its ability to classify fractures in children, but its clinical utility remains to be probed <sup>[2]</sup>.

The most comprehensive classification method used is descriptive, including the pattern of fracture and its location. We can distinguish two types of patterns:

1. Incomplete fractures: One of both cortices remains intact.
2. Complete fractures: Both cortices are broken. The pattern is like to those found in adults.

The location of the fracture will determine the healing potential and remodelling ability. According to location, fractures can be classified as:

1. Diaphyseal
2. Metaphyseal
3. Epiphyseal
4. Fractures through the physis

#### 1.1. Diaphyseal fractures

Incomplete fractures includes:

- Plastic deformity, where the bone deforms permanently. However, cortices do not break
- Greenstick fracture where one cortex fails in tension while the opposite suffers a plastic deformity.

Complete fractures, following the classical patterns seen in adults

The cortical bone is dense and relatively avascular. Therefore, most remodelling will depend on resorption and apposition following the law of Delpech <sup>[3]</sup>.

The expected remodelling will be limited in these cases, except in very young cases. Healing will need from 6 weeks to 3 months, depending on age and anatomic location:

- Obstetrical fractures usually heal within 3 to 4 weeks.
- Except for the clavicle (3 weeks), the hand and the humerus (6 weeks), other diaphyseal fractures (of the forearm, femur or tibia) can take up to 6 weeks to heal in infants and up to 3 months in teenagers.
- Bending of the ulna is almost always associated with a

dislocation of the radial head (Monteggia lesion).

- In toddlers, non-displaced or incomplete fractures of the tibia may not be visible on X-rays.
- The fracture of a young child's right clavicle, which will not heal, is probably an unrecognized congenital pseudarthrosis.
- Some isolated tibia fractures frequently displace in a varus due to the "splint effect" of the intact fibula.

The fracture can be transverse, oblique (short or long), spiroid, with a third fragment, comminuted, and sometimes bifocal. A description of the displacement should always refer to the distal fragment versus the proximal fragment.

## 1.2. Metaphyseal fractures

Metaphysis is located between the cortical bone and the physis. In this area, the incomplete fracture type is the torus fracture, with failure in compression and plicature of the cortex.

Metaphysis are rich vascularized areas with thin cortices formed mainly by cancellous bone. They are located near the physis, meaning they are very active in bone-forming as ossification of calcification occurs there. As a result, we will find quick healing and a high capacity for remodelling<sup>[3]</sup>. Their capacity will again depend on location, with areas close to the knee in the lower limb and away from the elbow in the upper limb with the higher capacity. The remodelling capacity is higher in the upper than in the lower limb

- A severe displacement of the proximal humerus has an excellent capacity for correction, whereas correction of a distal humerus deformity is usually very poor
- An antecurvatum malunion of the distal radius may correct at more than 10° a year, but an ulnar varus will remain almost unchanged with growth.

Healing will range from 3 to 6 weeks.

- An undisplaced medial proximal tibial fracture frequently heals with a progressive valgus deformity (Cozen's effect)<sup>[4]</sup>.

## 1.3. Physeal injuries

The literature describes more than six different classifications: the Salter–Harris classification, with five types of physeal injury, is the most often used<sup>[5]</sup>; Ogden's classification, with eight types, is the most complete<sup>[6]</sup>. It should be emphasised that the weak area of the physis corresponds to the hypertrophic cartilage, close to the metaphyseal bone and far from the germinal cells. As long as the latter zone remains intact, the chance of a post-traumatic epiphysiodesis is rare. Nevertheless, diagnosing an injury to the germinal centre using X-ray remains impossible. This is the case with Smith–Petersen distal radius type I injuries<sup>[7]</sup>, some Salter–Harris type II injuries with a compression of the physis itself during trauma, and of undetectable Salter–Harris type V injuries.

All transphyseal injuries (Salter–Harris type III and IV) are also joint fractures. It appears evident that these fractures must be perfectly reduced in order to: 1) regain the correct anatomical shape of the joint; and 2) avoid an epiphysiodesis due to a bony bar developing across the physis.

Each location presents specificities:

- Proximal humerus and distal forearm Salter–Harris type I and II injuries have great potential for remodelling.
- Many distal femoral and proximal tibial fractures Salter–Harris I and II lead to delayed deformities due to growth asymmetry.
- Salter–Harris type II injuries to the distal tibia, with a valgus displacement, are often associated with an entrapment of the periosteum into the fracture.

- ✓ *If not properly reduced, one frequent complication of a humeral lateral condyle fracture is non-union.*
- ✓ *A triplane fracture of the distal tibia is a Salter–Harris type IV injury.*
- ✓ *The medial malleolus fracture (MacFarland), Salter–Harris III or IV, is most often associated with a fracture of the distal fibula physis, Salter–Harris I.*

## 1.4. Apophyseal injuries

Traumatic avulsions of the apophysis are lesions specific to teenagers. During the time separating the ossification of any apophysis and the closure of its physis, a sudden contraction of the attached tendon may lead to an apophyseal avulsion fracture. The main apophyses affected are the antero-inferior-iliac spine (rectus femoris), ischium (hamstrings), lesser trochanter (psoas iliac), tibial tuberosity (quadriceps, patellar ligament) and humeral medial epicondyle.

- ✓ *A dislocated elbow is frequently associated with a humeral medial epicondyle fracture. This fragment may become entrapped in the joint after reduction of the dislocation.*

## 1.5. Small bones

### 1.5.1. Wrist

A fracture of the scaphoid bone may be difficult to diagnose. An MRI should be carried out if there are any positive clinical signs of a wrist fracture.

### 1.5.2. Foot

A non-displaced fracture of the talus, calcaneus, or another tarsal bone is not easy to diagnose from an X-ray. For a displaced fracture, accurate information about the lesion is mandatory for preparing for surgery. A CT scan may be helpful if any of these bones are fractured.

## 1.6. Intraarticular fractures and ligament injuries

Osteochondral fractures may appear during a traumatic patella dislocation at the patella or at the femoral condyle. The intraarticular fragment must be removed or fixed.

Ligament injuries may lead to the avulsion of their bony attachment and require surgical repair. Examples are the pre- and retro-spinal bony avulsions of the knee's cruciate ligaments, the

insertion of the medial patella-femoral ligament on the medial patella, and the tip of the lateral malleolus.

## 2. Principles of childhood fracture treatment

In general, treatment is determined by several factors that may be divided as:

- 2.1. Factors related to the fracture and its location
- 2.2. Factors related to the child
- 2.3. Factors related to the environment

### 2.1. Pattern of fracture and its location

The fundamental principle of treatment is the reduction of the fracture and its stabilization. The pattern of fracture and location will determine in a significant manner our treatment. However, the treatment choice should also consider the early return to school and sports activities.

#### 1. Diaphyseal fractures

In young children, "still" acceptable to treat these fractures conservatively (with plaster <sup>[8]</sup>):

- In very young patients healing with a deformity is acceptable and needs no correction as remodelling is very active
- In Toddlers and small children, plaster is recommended but do not accept much deformity as it will not remodel

In older children: Surgical treatment is recommended: flexible intramedullary nailing (FIN) is the first choice because it is an internal fixation that is less rigid and can be applied without hurting the physis <sup>[9]</sup>.

A lateral entry nail may be used in adolescent and in length unstable fractures.

Limitations for Flexible intramedullary nailing (FIN)w

- Inner canal diameter >10 cm
- Comminute fractures
- Segmental fractures
- Length unstable fractures (long oblique)

✓ A strait intramedullary locking nail through the trochanteric digital fossa of the femur may lead to avascular necrosis in 5% of teenagers and is not indicated for adolescents.

✓ Intramedullary locking through the tibial tuberosity physis before its fusion may lead to genu recurvatum.

#### 2. Metaphyseal fractures:

Most metaphyseal fractures may be managed conservatively in the:

- In young children
- In areas of high remodelling potential (close to the knee, far from the elbow)
- In stable fractures

Metaphyseal fractures around the elbow will need surgical treatment due to the poor remodelling capacity

- Supracondylar elbow fractures

- Radial neck fractures

Unstable metaphyseal fractures may need surgical treatment, especially in:

- Proximal and distal femur
- Some proximal humeral fractures in older children
- Some distal radius fractures

For those fractures requiring fixation FIN or "K" wires is the preferred system in the upper limb, while in the lower limb, the preferred system would be with plates and screw.

### 3. Physeal injuries

In physeal injuries SH-I and SH-II where the injury is not crossing the germinal layer, conservative treatment is indicated with a good prognosis for growth

The rule breakers are the SH-I and SH-II around the knee, with a poor prognosis and a high propensity to epiphysiodesis.

In physeal injuries III and IV, we need to reestablish the articular congruity and ensure that we reconstitute the alignment of the physis. Therefore, surgical treatment is always indicated and should provide a stable fixation. Most of the time, the fixation with screws will be the preferred method; resorbable screws may be an even better option.

Supra and intercondylar fractures of either the distal humerus or femur will need stable fixation using specific plates.

✓ In physeal injuries type I and II involving distal radius that is redisplaced or is diagnosed at a late stage, do not attempt late reduction as it may increase the damage to the physis. They may correct spontaneously as the remodelling ability is very high..

✓ SH I and II of distal tibia late detected may not remodel, but it is better to deal with the residual deformity than getting a closure of the physis.

#### 4. Apophyseal injuries

Fixation is indicated in those highly displaced fractures, although the limits of acceptable displacement are not clearly established.

As a general principle, treatment of fractures in children:

**Conservative treatment is indicated in the:**

- Undisplaced fractures
- Young children
- Areas of high remodelling capacity

**Surgical treatment would be indicated in the:**

- Older children and Adolescents
- Areas of poor remodelling
- Unstable fractures
- When multiple associated fractures exist.

### 2.2. Factors related to the child

Other factors besides the characteristics of the fracture may influence the choice of management:

**2.2.a.** Size of the child: Different sizes imply different treatments.

**2.2.b.** Weight of the child: weight has an influence in:  
 o Chances casting failure: re-displacement is more frequent in obese patients

- Choice of implant: the implant election may be determined by the weight of the patient
- The type of fracture and its healing ability may differ in obese people.

**2.2.c.** Associated pathologies: the existence of underlying pathologies or the presence of multiple injuries may determine treatment.

**2.2.d.** Age: It is crucial not only because it determines the remodelling ability and, therefore, the choice or not for surgical fixation, also, because we are dealing with a growing bone, and changes may appear later due to disturbances in growth.

✓ Remember that for some fractures the final follow-up should be a skeletal maturity.

## 2.3. Factors related to environment

- Family: Treating children implies understanding that the family should be involved in the treatment decision. It is not only the child but also the family who should consent to the final treatment.
- Social conditioning: there is a growing social pressure for treatments with faster recovery and return to everyday life. This conditioning may not only come from the child and their necessities but also by the family's needs. In the present social reality with both parents working, it may be difficult for the families to comply with lengthy conservative treatment. In occasions, surgical treatment may be a better option.
- Child Abuse: Always remember that some children may present with fractures due to child abuse, and we may be the last safeguard for the child.

In child Abuse be suspicious in fractures:

- ✓ in non-walking children,
- ✓ when the injury is non-coincidental with the explanation of the mechanism of the injury
- ✓ when the healing process does not match with the date of the reported injury.

## 3. Conclusion

Treatment of fractures in children is difficult due to the heterogeneous group of patients, ranging from babies to heavy adolescents with very little in common. Sound knowledge of physiology may help elect adequate treatment for the child's fracture. Orthopaedic surgeons dealing with children should be flexible enough to understand that a single treatment does not fit all, even when the conditions of the children are similar. Remember that families are a fundamental part of the child's treatment. Keep them informed and explain the possible complications in advance; this may help keep the confidence and make the management much more straightforward.

## 4. Further Reading

My preferred textbooks: Mercer Rang, 1974 <sup>[10]</sup> a masterpiece, Pierre Lascombes <sup>[9]</sup> and the Rockwood & Wilkins, 2020 <sup>[11]</sup>.

## References:

1. Slongo T, Audigé L, Schlickewei W, Clavert JM, Hunter J; International Association for Pediatric Traumatology. Development and validation of the AO pediatric comprehensive classification of long bone fractures by the Pediatric Expert Group of the AO Foundation in collaboration with AO Clinical Investigation and Documentation and the International Association for Pediatric Traumatology. *J Pediatr Orthop*. 2006; 26: 43-9.
2. Joeris A, Lutz N, Blumenthal A, Slongo T, Audigé L. The AO pediatric Comprehensive Classification of Long Bone Fractures (PCCF): Part I: Location and morphology of 2,292 upper extremity fractures in children and adolescents. *Acta Orthop*. 2017;88(2):123-8.
3. Wilkins KE. Principles of fracture remodeling in children. *Injury* 2005;36:3-11.
4. Cozen L. Fracture of the proximal portion of the tibia in children followed by valgus deformity. *Surg Gynecol Obstet*. 1953;97: 183-8.
5. Salter RB, Harris R. Injuries involving the epiphyseal plate. *J Bone Joint Surg Am*. 1963;48: 587-622.
6. Ogden JA. Injury to the growth mechanisms of the immature skeleton. *Skeletal Radiol*. 1981; 6: 237-53.
7. Peterson HA: Physeal fractures. III. Classification. *J Pediatr Orthop*. 1994; 14: 439-48.
8. Wenger D. Cast in Children. In *The Art and Practice of Children Orthopaedics* ed: Wenger Dr, Rand M. Raven Press 1993. New York.
9. Lascombes P. Flexible Intramedullary Nailing. *The Nancy University Manual*. Springer-Verlag, Berlin, Heidelberg. 2010.
10. Rang M. *Children's fractures*. Lippincott, 1974, 238p.
11. Rockwood and Wilkins' *Fractures in children* 9th Ed. Waters PM, Skaggs DL, Flynn JM. 2020 Wolters Kluwer.



## Questions

1. Closed diaphyseal femoral fracture in a child 6 years old. The best treatment option would be::
  - a. Skin traction followed by hip spica
  - b. Immediate hip spica
  - c. Flexible intramedullary nailing
  - d. Submuscular plating
2. A boy age 13yr suffers a long oblique midshaft femur. His weight is 60 kg and is a regular football player. What would be the best option:
  - a. Straight IM rigid nail
  - b. Flexible Intramedullary nailing (FIN)
  - c. Plating
  - d. Lateral entry IM nailing
3. Which malunion fracture would have a better chance of remodelling?
  - a. Diaphyseal fracture of the femur in child 6yr old
  - b. Metaphyseal fracture of the distal humerus in a child age 3yr
  - c. Metaphyseal fracture proximal humerus in a child age 6yr
  - d. Diaphyseal fracture radius in a child age 5yr
4. A girl 10yr old with a Salter-Harris type II fracture of the distal radius, appears in casualty after 1 week of evolution with a 30° angulation in flexion. Your best option would be?
  - a. Do not touch, wait for remodeling
  - b. Open reduce of the fracture
  - c. Close re-manipulation
  - d. Close reduction and fixation with "K" wires
5. A girl aged 5 is brought to casualty by her mother, unable to walk. On examination has an obvious deformity of the right tibia. Mum explains that her daughter sustain a fall at school, and she has been told that the fracture in a fall while running.
  - a. We have to rule out Osteogenesis imperfecta
  - b. The history is unlikely to be true
  - c. A fracture after a fall at ground level could be normal in a child
  - d. The most common pattern will be a butterfly fragment

## Answers

1c, 2d, 3c, 4a, 5c



Assoc. Prof. Christof Radler

Orthopaedic Hospital Speising GmbH

Vienna, Austria

christof.radler@oss.at

## Foot Disorders of Newborns

Foot disorders are the most common congenital deformities seen at birth. In addition to true congenital deformities, there is a variety of molding deformities, which are usually mild and resolve spontaneously. The incidence of foot deformities in a consecutive series of 2401 patients was reported with 4.2% with 87% of those feet being normal at reexamination <sup>[41]</sup>.

Differentiating mild deformities which can be corrected with massage and benign neglect, and those needing treatment or showing recurrence, is not always easy but nonetheless crucial.

In the newborn all foot disorders can be diagnosed clinically by inspection and palpation. The ankle, hindfoot, midfoot and forefoot and the position, range of motion and flexibility of these segments should be evaluated. Documentation should include digital images and clinical scoring systems, whenever available. Radiographs are never necessary at presentation in the neonatal period but might be helpful in the course of treatment to add information to the decision-making process or as documentation in cases that received prior treatment <sup>[32]</sup>.

In all cases, a thorough examination including a basic neuro-orthopaedic evaluation has to be performed. The pregnancy and birth history can give valuable hints at the possible etiology of the abnormality. A hip-ultrasound should be performed if an association between foot deformities (like metatarsus adductus or clubfoot) and hip dysplasia is controversially reported <sup>[28,29]</sup>.

## 1. Molding deformities

Molding deformities are deformities, which are connected to the position of the child in utero. As the crowding of the infant increases especially in the last weeks of pregnancy those deformities are usually less frequent in preterm infants <sup>[20]</sup>. However, the etiologies are overlapping and special considerations must be given to feet presenting muscle imbalance on the basis of a still undeveloped or unbalanced neuro-motoric system.

### 1.1 Metatarsus adductus (MTA)

Metatarsus adducts (MTA) also known as "bean-shaped foot" is the most common molding deformity. The forefoot is adducted in relation to the hindfoot often presenting a prominent fifth metatarsal base. However, the Achilles tendon is not shortened and full passive dorsiflexion is possible. (Figure 1) Clinical examination can differentiate between a flexible MTA and a rigid MTA. In flexible MTA the forefoot can passively be abducted to more than neutral, while rigid MTAs can not be abducted to a neutral position. Flexible MTAs usually resolve spontaneously. However, the mother can perform a stretching of the medial foot and especially stimulation

of the lateral foot and thigh which usually stimulate the peroneal muscle group and results in abduction, dorsiflexion and eversion of the whole foot, and extension and abduction of the toes. In more resistant cases an abduction orthotic – which is available in different forms of shoes like the IPOS shoe or reverse-last shoes – might be used up to the age of 6-9 months.

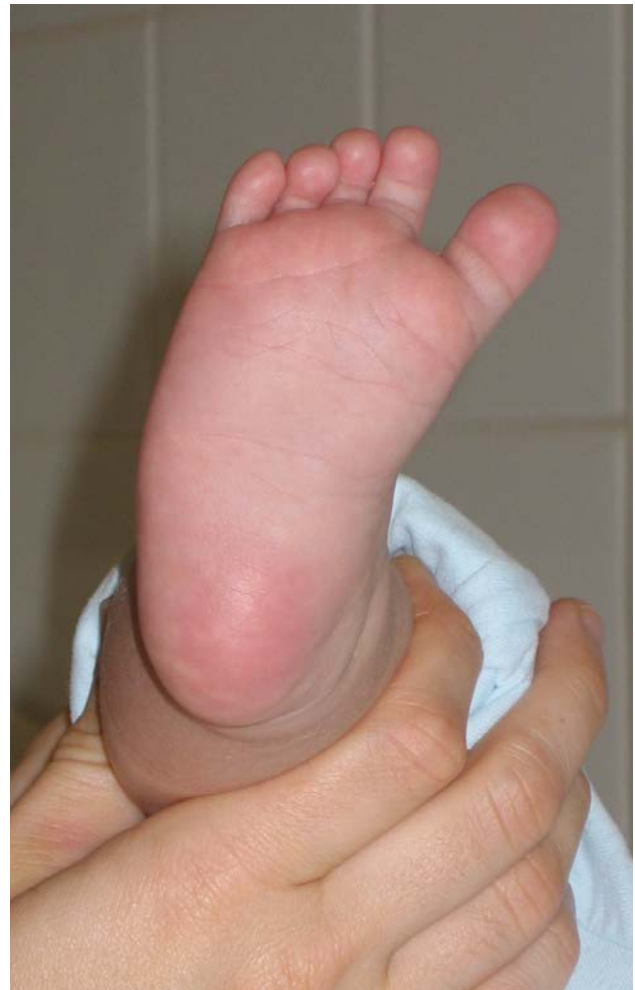

Fig 1: Mild but persistent metatarsus adducts

Rigid cases should be casted. For casting, the foot is abducted with counter pressure on the calcaneo-cuboid area. This is similar to Kites technique of casting for clubfoot which is obsolete for clubfoot correction but works very well for MTA <sup>[21]</sup>. A well molded above the knee cast should be applied, as this minimizes the risk of cast slipping. With experience in infant casting, a below-the-knee cast can be applied <sup>[19]</sup>. In rigid cases a follow-up treatment with IPOS shoes or reverse-last shoes should be performed.

A recent study showed that use of a novel brace was equally effective to serial casting with no significant difference in the total duration of treatment, complication rates or recurrence rates [12].

Most cases will correct well with the described treatment regimes. However, there is a small minority of cases that will tend to recur and might need prolonged orthotic treatment. These are usually cases with distinct muscle imbalance and overpowering of the tibialis anterior tendon.

MTA should not require surgery as even residual forefoot adduction does usually not lead to functional limitations or foot wear problems. In a long-term study of patients with MTA, no functional problems were found and no foot was graded as a poor [11].

For the very rare case with severe persistent deformity and significant foot wear problem, a minimal invasive procedure has recently been described [22]. However, cosmetic concerns of the parents should not be accepted as indication for surgery; a cosmetic procedure can still be performed after the end of growth.

## 1.2 Skewfoot

Skew foot is a combination of MTA with increased heel valgus (as seen in talus obliquus or congenital flatfoot) which is very rarely seen after birth but usually is diagnosed later in life from 4 to 6 years onwards. If present at birth, it can be very rigid with casting being very difficult. For casting, abduction of the forefoot – in relation to the hindfoot – must be achieved using the prominent fifth metatarsal base and cuboid as a fulcrum, while supporting the plantar and medially displaced talus head. In older children the correction can be achieved surgically. Usually a combination of surgical procedures used for correction of flat foot – like calcaneal lengthening – and for correction of forefoot adduction – like medial cuneiform opening wedge osteotomy and tibialis anterior split tendon transfer – is successful [12].

## 1.3 Talipes calcaneovalgus

Talipes calcaneovalgus is a quite frequent molding deformity and is characterized by an extremely dorsiflexed foot with the dorsum of the foot often touching the shin bone (Figure 2). The forefoot might even be mildly abducted as the calcaneus is in a marked valgus position. It can easily be differentiated from congenital vertical talus (CVT) as the calcaneus is not in equinus and the Achilles tendon is not shortened. Posteromedial bowing of the tibia – which is a deformity of the most distal tibia – sometimes presents with the foot in a quite similar position (Figure 3). However, in this deformity the tibia is bowed distally into recurvatum and valgus which results in a foot which is parallel to the tibia but itself totally normal and in normal relationship to the distal part of the tibia [27].

If the foot can be plantarflexed beyond neutral massage and stretching should be performed by the parents and will help the deformity to resolve. In more rigid cases one or two casts might be preferable to achieve correction, and might help to prevent subsequent hypermobile pes planovalgus in the older child [10].

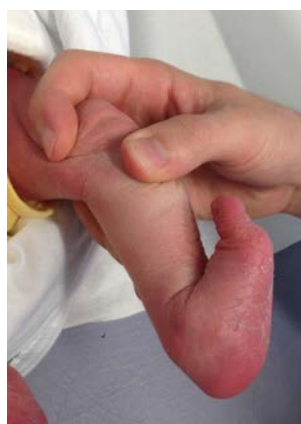

Figure 2: Talipes calcaneovalgus in a newborn

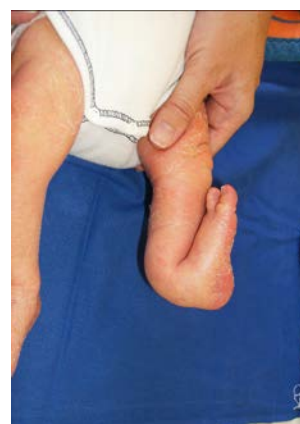

Figure 3: Posteromedial bowing. Note that the deformity is in the tibia only

## 1.4 Positional clubfoot (postural talipes equinovarus)

Positional clubfoot is a molding deformity which resembles clubfoot. The foot is in mild equinus, in adduction and is rotated inwards. However, the foot is passively fully flexible with dorsiflexion well above neutral and no sign of the rigid deformities seen in true clubfoot (Figure 4 a,b). Positional clubfoot usually responds to stretching and massage. However, some cases are somewhere between severe positional clubfoot and mild idiopathic clubfoot and should be followed to at least two years of age. Whenever a cast is needed for correction, abduction bracing as for clubfoot should be performed for a limited amount of time.

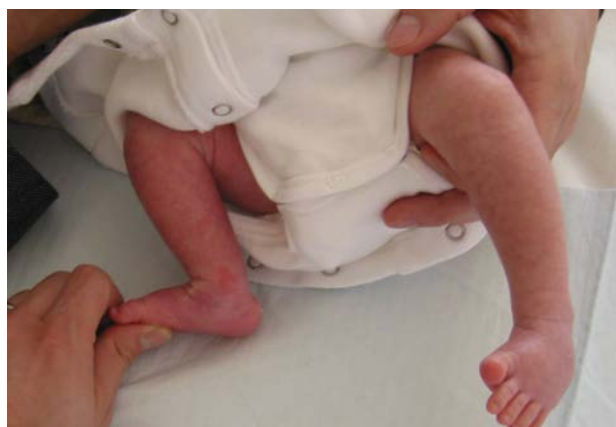
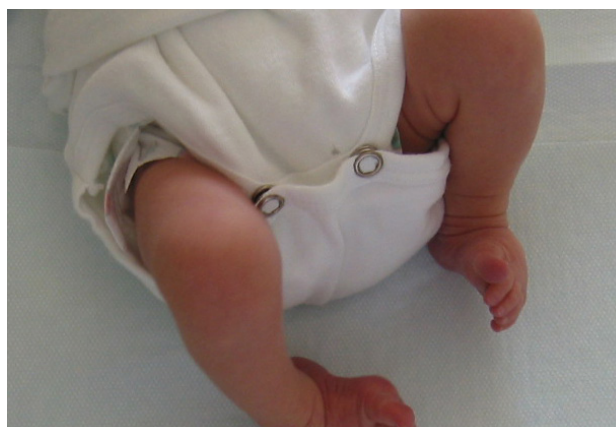
Figure 4: Positional clubfoot looks like a clubfoot at birth (a) but is passively correctable with free dorsiflexion (b).

## 2. Structural deformities

All congenital deformities of the foot show a structural deformity compared to the molding deformities which present a positional deformity. Especially in clubfoot, the muscles, ligaments and bones are not normal.

### 2.1 Clubfoot

Clubfoot is the most common true congenital deformity with an incidence of 1.25 in 1000 live birth. It can be found bilateral in 40–50% and male patients are affected more often with a sex ratio male to female of 2.5:1.

The etiology is still unknown; however there is a multitude of factors associated with an increased incidence of clubfoot. Genetic studies have favored the hypothesis of a heterogeneous disorder with a polygenetic threshold model explaining the inheritance patterns [6].

Clubfoot is a very complex deformity that shows different components which are often described separately but are all related nonetheless: There is equinus of the hindfoot due to shortening and retraction of the Achilles tendon, varus (inversion) of the hindfoot (calcaneus) and adduction of the calcaneus with the calcaneus being near the lateral malleolus. As a result the calcaneus stands parallel under the talus. The forefoot is adducted and in cavus with the navicular, being displaced to medial and near the medial malleolus. Although the forefoot is in supination related to the axes of the tibia, the forefoot is pronated in relation to the hindfoot adding to the cavus and adductus and the medial deep skin crease (Figure 5 a,b).

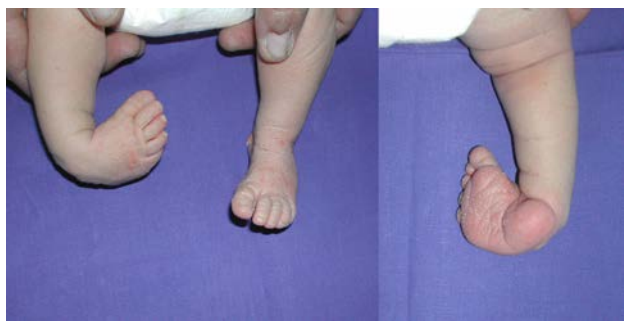

Fig 5a: Unilateral clubfoot in a 5 days old girl with Pirani 5.5.

Additionally to the displacements of the bones, there are marked structural deformities like the talus dome which is mildly flattened [15] and might be increased during treatment by over-vigorous casting: the ligaments are less flexible and contracted, the muscles are more fibrotic and cells of the medial ligamentous tissue have myofibroblastic characteristics [17,36].

Secondary clubfoot must be differentiated from idiopathic clubfoot. Secondary clubfoot might be seen in patients with arthrogryposis, myelomeningocele (MMC) spina bifida and other neurogenic disorders, as part of a syndrome or in association with a fibular hemimelia.

Prenatal diagnosis has increased in the last years and most mothers prefer to know about their baby's clubfoot before birth. However, prenatal counseling is necessary and should include a treatment outline and discussing the possibility of non-idiopathic clubfoot and additionally the possibility of a false positive diagnosis [35].

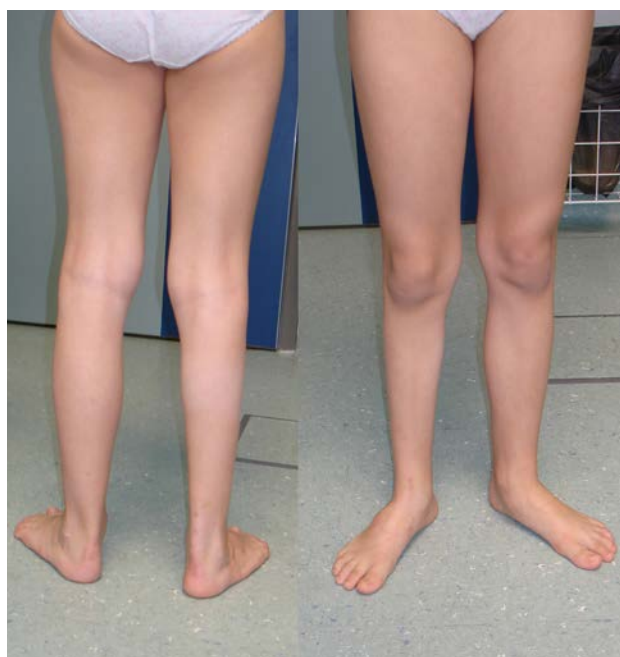

Fig 5b: Same patient at age 9 years after Ponseti treatment with additional tibialis anterior tendon transfer

Treatment should be started within the first weeks of life. However, there is no need to rush treatment as it was traditionally done in many countries. I recommend starting treatment after the infant and mother have been released from the hospital and feel well and strong enough for travelling. At presentation, a thorough pediatric orthopaedic examination of the newborn must be performed which should include a hip ultrasound. Documentation should include digital pictures and a clinical scoring. The Pirani score is a very well reproducible and validated score that can even guide the treatment process [38].

In the last 10 years, the Ponseti method has become the gold standard for the treatment of clubfoot worldwide [18,37]. The Ponseti method is a mostly non-operative treatment regime with serial casting with above-the-knee casts and weekly cast changes. The superior results are achieved by following the very well defined treatment regime in great detail [30,31]. Short manipulation is recommended before casting. For the first casting, the first metatarsal must be raised to align the forefoot with the hindfoot and to decrease cavus. The foot should never be pronated. In the following casts a pure abduction with counter pressure on neck of talus, not calcaneus, is performed. Long leg casts weekly for about 4–7 weeks are necessary to achieve full correction with abduction, eversion and dorsiflexion of the calcaneus from underneath the talus. An Achilles tenotomy is necessary in about 90% of cases, when after clinical examination dorsiflexion of at least 15 degrees cannot be obtained. In cases with dorsiflexion over 15 degrees and no need for a tenotomy from clinical evaluation, a lateral stress dorsiflexion view radiograph should be performed to evaluate the true correction of the hindfoot and especially the tibio calcaneal angle [33]. The tenotomy is a full percutaneous tenotomy, performed from medial to lateral to avoid bleeding complications. The last cast after the tenotomy stays for three weeks and is molded in full abduction and dorsiflexion. After cast removal a foot abduction orthosis (Denis Browne bar), with the clubfoot in 70 degrees abduction and the normal foot in 45 degrees abduction must be used for 22 hours for 3 months and for 3–4 years for nights and



naps. A tibialis anterior tendon transfer is necessary in about 20 % of patients usually between age 3-6, in case of weak peroneal muscles and an overpowering tibialis anterior muscle.

Mid- and long-term results are very good and superior to other treatments or surgical approaches in literature [3-5,24,34,39].

## 2.2 Congenital vertical talus (CVT)

Congenital vertical talus presents as a rocker-bottom deformity with fixed equinus of the calcaneus and dorsal dislocation of the navicular on the talus. It can be found bilateral in about 50% of patients and can even be associated with a contralateral clubfoot (Figure 6). Mostly cases are associated with syndromes like arthrogryposis, trisomy 18, sacral agenesis or Larson's syndrome. The incidence is with approximately 1:10.000 about ten times lower than clubfoot.

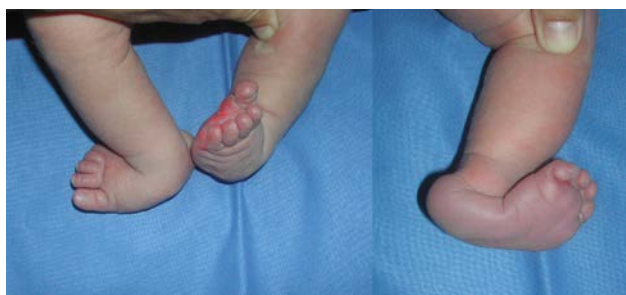

Figure 6: Patient with congenital vertical talus on the right and clubfoot on the left side.

The exact etiology is still unknown but muscle imbalance, intrauterine compression particularly when coupled with arthrogryposis, or arrest in fetal development of the foot have been discussed. More recent studies suggest that skeletal muscle biopsy abnormalities are common in patients with vertical talus and are more frequently seen in patients with congenital myopathy and distal arthrogryposis [23]. However, isolated CVT can be transmitted as an autosomal dominant trait with variable expression and incomplete penetrance [8].

Classifications usually are based on the underlying etiology. Ogata differentiated in his series between a primary isolated form (44%) and an associated form with and one without a neurological deficit (50%) [25].

As differential diagnoses flexible flatfoot, oblique talus and talipes calcaneovalgus must be ruled out. Flexible flatfoot presents without fixed equinus and with a navicular which is less prominent and can easily be repositioned in front of the talus by dorsiflexion. Oblique talus is a less severe manifestation of CVT with a rocker-bottom deformity of the foot and equinus contracture but with a reducible navicular.

Congenital vertical talus is a very complex deformity. The navicular articulates with the dorsal aspect of the neck of the talus, the calcaneus is displaced posterolaterally in relation to the talus and, is in equinus. Additionally, there is a variable degree of subluxation of the calcaneocuboid joint. On clinical examination the plantar prominent talus can be palpated. The forefoot is abducted and dorsiflexed and the hindfoot in equinus. Radiographs in ap.-and lateral view and, lateral with maximum plantarflexion and dorsiflexion view, can help to differentiate CVT from Talus obliquus.

Traditionally, the treatment was surgical, with the most recent approach being an open release through a Cincinnati approach, tendo Achilles lengthening, capsulotomy and medial release with reposition of navicular, reconstruction of capsule and transfixation with k-wires. A treatment based on serial manipulation and casting combined with a minimal surgical intervention was introduced by Dobbs [7]. After correction of the talonavicular luxation by casting which could be summed up as a reversed Ponseti casting, a minimal medial approach is used to reposition the navicular and transfix the navicular to talus with a k-wire. Afterwards, a percutaneous Achilles tendon tenotomy is performed and the result fixed in a cast. An orthotic treatment is necessary to prevent recurrence. Encouraging results of the Dobbs technique have been reported in literature [7,9].

## 2.3 Toe deformities and duplications

### 2.3.1 Curly toes

Abnormalities of the toes are almost always visible at birth. Many infants and toddlers are presented with mild deformities of the toes usually referred to as curly toes. Curly toes are typically bilateral and mostly affect the second to fourth toes. The deformity corrects spontaneously in many cases. In resistant cases taping or splinting can only temporarily improve the position but is very bothersome for the small patient and the parents. Surgical correction should only be considered when significant clinical problems arise due to overlapping of the toes and resulting pressure sores. For surgical correction flexor tenotomy has been shown to be effective. [14]

### 2.3.2 Syndactyly

Syndactyly is a congenital webbing of toes most commonly affecting the second and third toe. The webbing can reach until the tip of the toe or can be incomplete. Syndactyly does not lead to any kind of functional impairment or limitation and does therefore not require surgical correction. Cosmetic concerns should not be considered as an indication for the operation. Separation of the toes usually requires Z-plasties or skin crafts which lead to cosmetically unsatisfying results.

### 2.3.3 Polydactyly

Polydactyly can affect the lateral fifth ray (fibular or postaxial polydactyly), the middle rays (central polydactyly) or the medial first ray (preaxial polydactyly). Polydactyly can be part of a syndrome but is most often isolated and is bilateral in about half of the cases.

Depending on the extent of involvement, a distal phalangeal type, a middle phalangeal type, a proximal phalangeal type and a metatarsal type can be differentiated [2,40]. A tarsal type with duplication or partial duplication of the hindfoot is very rare.

In fibular polydactyly resection of the supernumerary ray is usually performed between age 9 to 12 months. Radiographs should be performed to confirm the most lateral ray as the hypoplastic one.

Tibial polydactyly comes in many different shapes and forms and is more complex regarding surgical correction (Figure 7). Acute lengthening with interposition of a small fibular segment or gradual lengthening with external fixation is often necessary for shortening of the first ray. The very rare central duplications can be excised through a racquet incision and need reconstruction of the plantar intermetatarsal ligament.

Although good alignment of the toe can usually be achieved, widening of the forefoot sometimes persists.

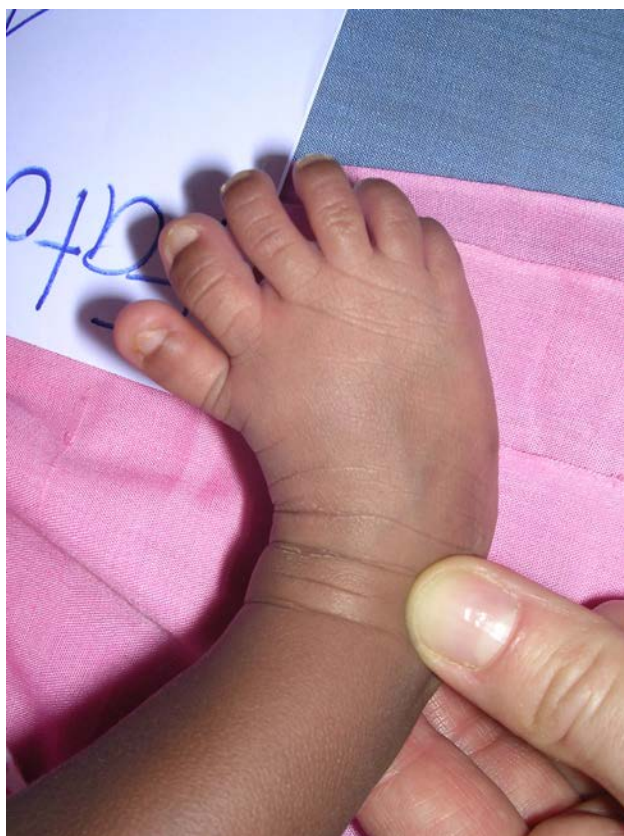

Fig 7: Tibial preaxial polydactyly with duplication of the first ray.

## 2.3.4 Ray deficiencies

Ray deficiencies are usually found in association with other deformities like fibula hemimelia or tibial hemimelia. As the lateral developmental field is affected in fibular hemimelia, usually the lateral rays are missing<sup>[26]</sup>. In a similar way tibial hemimelia is often associated with tibial polydactyly.

Central ray deficiencies can be found in the form of a cleft foot (formerly and unfortunately known as lobster claw). This deformity is very rare with an incidence of about 1 on 90000 births and mostly bilateral. Classification is mainly based on the number of existing metatarsals<sup>[1]</sup>. Surgical correction is difficult and aims at narrowing the wide foot<sup>[42]</sup>.

## References:

1. Blauth W, Borisch NC 1990 Cleft feet. Proposals for a new classification based on roentgenographic morphology. *Clin Orthop Relat Res* (258):41-8.
2. Blauth W, Olason AT 1988 Classification of polydactyly of the hands and feet. *Arch. Orthop. Trauma. Surg* 107, 334-344.
3. Bor N, Coplan JA, Herzenberg JE (2009) Ponseti treatment for idiopathic clubfoot: minimum 5-year followup. *Clin Orthop* 467: 1263-1270
4. Church C, Coplan JA, Poljak D, Thabet AM, Kowtharapu D, Lennon N, Marchesi S, Henley J, Starr R, Mason D, Belthur MV, Herzenberg JE, Miller F (2012) A comprehensive outcome comparison of surgical and Ponseti clubfoot treatments with reference to pediatric norms. *J Child Orthop.*6(1):51-9.
5. Cooper DM, Dietz FR (1995) Treatment of idiopathic clubfoot: a thirty-year follow-up note. *J Bone Joint Surg Am* 77-A: 1477-1489.
6. Dobbs MB, Gurnett CA (2012) Genetics of clubfoot. *J Pediatr Orthop B* 21(1):7-9.
7. Dobbs MB, Purcell DB, Nunley R, Morcuende JA (2006) Early results of a new method of treatment for idiopathic congenital vertical talus. *J Bone Joint Surg Am* 88(6):1192-200.
8. Dobbs MB, Schoenecker PL, Gordon JE (2002) Autosomal dominant transmission of isolated congenital vertical talus. *Iowa Orthop J* 22:25-7
9. Eberhardt O, Fernandez FF, Wirth T. [Treatment of Vertical Talus with the Dobbs Method.] *Z Orthop Unfall.* 2011;149(2):219-224.
10. Edwards ER, Menelaus MB 1987 Reverse club foot. Rigid and recalcitrant talipes calcaneovalgus. *J Bone Joint Surg Br* 69:330.
11. Farsetti P, Weinstein SL, Ponseti IV (1994) The long-term functional and radiographic outcomes of untreated and non-operatively treated metatarsus adductus. *J Bone Joint Surg Am* 76(2):257-65.
12. reedman D, Kotlarsky P, Eidelman M. Novel device for nonsurgical correction of rigid forefoot adduction in children. *J Pediatr Orthop B.* 2022 1;31(2):e202-e207.
13. Hagmann S, Dreher T, Wenz W (2009) Skewfoot. *Foot Ankle Clin.* 14(3):409-34.
14. Hamer AJ, Stanley D, Smith TW (1993) Surgery for curly toe deformity: a double-blind, randomised, prospective trial. *J Bone Joint Surg Br* 75(4):662-3.
15. Herzenberg JE, Carroll NC, Christofersen MR, Lee EH, White S, Munroe R (1988) Clubfoot analysis with three-dimensional computer modeling. *J Pediatr Orthop* 8(3):257-62.
16. Holt JB, Oji DE, Yack HJ, Morcuende JA (2015) Long-Term Results of Tibialis Anterior Tendon Transfer for Relapsed Idiopathic Clubfoot Treated with the Ponseti Method: A Follow-up of Thirty-seven to Fifty-five Years. *J Bone Joint Surg Am* 97(1):47-55.
17. Ippolito E, Ponseti IV (1980) Congenital clubfoot in the human fetus: A histological study. *J Bone Joint Surg Am* 62: 8-22.
18. Jowett CR, Morcuende JA, Ramachandran M (2011) Management of congenital talipes equinovarus using the Ponseti method: a systematic review. *J Bone Joint Surg Br* 93(9):1160-4.
19. Katz K, David R, Soudry M (1999) Below-knee plaster cast for the treatment of metatarsus adductus. *J Pediatr Orthop* 19(1):49-50.
20. Katz K, Naor N, Merlob P, Wielunsky E (1990) Rotational deformities of the tibia and foot in preterm infants. *J Pediatr Orthop* 10(4):483-5.
21. Kite JH (1967) Congenital metatarsus varus. *J Bone Joint Surg Am* 49(2):388-97.
22. Knörr J, Soldado F, Pham TT, Torres A, Cahuzac JP, Gauzy JS (2013) Percutaneous correction of persistent severe metatarsus adductus in children. *J Pediatr Orthop.* Nov 21. [Epub ahead of print]

23. Merrill LJ, Gurnett CA, Connolly AM, Pestronk A, Dobbs MB (2011) Skeletal muscle abnormalities and genetic factors related to vertical talus. *Clin Orthop Relat Res* 469(4):1167-74.
  24. Mindler GT, Kranzl A, Lipkowski CA, Ganger R, Radler C (2014) Results of gait analysis including the Oxford foot model in children with clubfoot treated with the Ponseti method. *J Bone Joint Surg Am* 96(19):1593-9.
  25. Ogata K, Schoenecker PL, Sheridan J (1979) Congenital vertical talus and its familial occurrence: an analysis of 36 patients. *Clin Orthop Relat Res* (139):128-32.
  26. Opitz JM (1985) The developmental field concept. *Am J Med Genet* 21(1):1-11.
  27. Pappas AM (1984) Congenital posteromedial bowing of the tibia and fibula. *J Pediatr Orthop* 4:525.
  28. Paton RW, Choudry Q (2009) Neonatal foot deformities and their relationship to developmental dysplasia of the hip: an 11-year prospective, longitudinal observational study. *J Bone Joint Surg Br* 91(5):655-8.
  29. Perry DC, Tawfiq SM, Roche A, Shariff R, Garg NK, James LA, Sampath J, Bruce CE (2010) The association between clubfoot and developmental dysplasia of the hip. *J Bone Joint Surg Br* 92(11):1586-8.
  30. Ponseti IV (1996) *Congenital clubfoot. Fundamentals of treatment*. New York: Oxford University Press Inc.
  31. Radler C. *The Ponseti method for the treatment of congenital club foot: review of the current literature and treatment recommendations*. *Int Orthop*. 2013;37(9):1747-53.
  32. Radler C, Egermann M, Riedl K, Ganger R, Grill F (2010) Interobserver reliability of radiographic measurements of contralateral feet of pediatric patients with unilateral clubfoot. *J Bone Joint Surg Am* 20;92(14):2427-35.
  33. Radler C, Manner HM, Suda R, Burghardt R, Herzenberg JE, Ganger R, Grill F (2007) Radiographic Evaluation of Idiopathic Clubfeet Undergoing Ponseti Treatment. *J Bone Joint Surg Am* 89: 1177-1183.
  34. Radler C, Mindler GT, Riedl K, Lipkowski C, Kranzl A (2013) Midterm results of the Ponseti method in the treatment of congenital clubfoot. *Int Orthop* 37(9):1827-31.
  35. Radler C, Myers AK, Burghardt RD, Arrabal PP, Herzenberg JE, Grill F (2011) Maternal attitudes towards prenatal diagnosis of idiopathic clubfoot. *Ultrasound Obstet Gynecol* 37(6):658-62.
  36. Sano H, Uhthoff HK, Jarvis JG, Mansingh A, Wenckebach GF (1998) Pathogenesis of soft-tissue contracture in club foot. *J Bone Joint Surg Br* 80(4):641-4.
  37. Shabtai L, Specht SC, Herzenberg JE (2014) Worldwide spread of the Ponseti method for clubfoot. *World J Orthop* 5(5):585-90.
  38. Shaheen S, Jaiballa H, Pirani S (2012) Interobserver reliability in Pirani clubfoot severity scoring between a paediatric orthopaedic surgeon and a physiotherapy assistant. *J Pediatr Orthop B* 21(4):366-8.
  39. Smith PA, Kuo KN, Graf AN, Krzak J, Flanagan A, Hassani S, Caudill AK, Dietz FR, Morcuende J, Harris GF (2013) Long-term Results of Comprehensive Clubfoot Release Versus the Ponseti Method: Which Is Better? *Clin Orthop Relat Res*. Nov 19. [Epub ahead of print]
  40. Watanabe H, Fujita S, Oka H (1992) Polydactyly of the foot: an analysis of 265 cases and a morphological classification. *Plast Reconstr Surg* 89:856-877.
  41. Widhe T, Aaro S, Elmstedt E (1988) Foot deformities in the newborn--incidence and prognosis. *Acta Orthop Scand* 59(2):176-9.
  42. Wood VE, Peppers TA, Shook J (1997) Cleft-foot closure: a simplified technique and review of the literature. *J Pediatr Orthop* 17(4):501-4.
- 
- ### Questions
1. Molding deformities are deformities,
    - a. needing surgical treatment and follow-up.
    - b. connected to the position of the child in utero.
    - c. which are the result of structural changes.
    - d. connected to autosomal dominant diseases.
  2. Which of the following deformities is a molding deformity?
    - a. clubfoot
    - b. talipes calcaneovalgus
    - c. congenital vertical talus
    - d. preaxial polydactyly
  3. In clubfoot treatment using the Ponseti method, the foot abduction brace should be used
    - a. for 3 months
    - b. for 2 years
    - c. until approximately 4 years of age
    - d. until the foot looks good
  4. What is usually not part of clubfoot treatment using the Ponseti method?
    - a. serial casting
    - b. abduction with counter pressure on neck of talus
    - c. a percutaneous Achilles tenotomy
    - d. an ankle foot orthosis (AFO)
  5. The incidence of congenital vertical talus is approximately
    - a. 1:100
    - b. 1:1.000
    - c. 1:10.000
    - d. 1:100.000
- 
- ### Answers
- 1b, 2b, 3c, 4d, 5c





Matthias Pallamar, MD.

Department of Pediatric Orthopaedics and Foot Surgery  
Orthopaedic Hospital Vienna Speising  
Vienna, Austria

matthias.pallamar@oss.at

## Hip Diseases In The Childhood

Precise knowledge about of hip diseases in newborns, children and adolescents is important to avoid possible hip damage and functional limitations in adulthood. This chapter provides an overview of rapid diagnosis and efficient therapy in principal orthopedic hip disorders from birth to adolescence.

### 1. Developmental Dysplasia Of The Hip (DDH)

Developmental dysplasia of the hip (DDH) occurs in different forms at different ages and includes all grades of instability and morphological abnormalities detected by ultrasound or radiography. The true incidence of DDH is difficult to determine because of disparities in the definition, the type of examinations used to detect DDH and the population being studied. Estimates range from 0.5 to 4 %<sup>[37, 44]</sup>. Understanding the natural history of DDH requires knowledge of the growth and development of the hip joint from birth to skeletal maturity. Due to differences in the diagnosis and the management of the disease, this entity is divided in different groups:

#### 1.1 DDH in newborns (0 to 1 year)

Since the introduction of hip sonography and its standardization, results of treatment have improved due to early diagnosis of deformities at birth<sup>[15]</sup>. Every newborn should be screened for signs of DDH or instability. Clinical examinations include the Barlow and Ortolani techniques and require experienced examiners to detect cases of complete hip dislocation in newborns<sup>[3]</sup>. The ultrasound technique according to Graf is a screening method, independent to the examiner's experience and skills, and provides a tool for early detection and early adequate therapy of all cases of DDH, including cases of lacking coverage of the femoral head, that may turn to a residual hip dysplasia in the future. The  $\alpha$ -angle according to Graf should be at least 50° at birth in cases of physiologic delayed hip development and should increase to 60° and higher in a 3-month old newborn without any treatment. Hips with pathologic decreased  $\alpha$ -angles and increased  $\beta$ -angles can be classified by Graf. Each sonographic type can be assigned to a specific phase of treatment correlated with a specific procedure effective in the given pathoanatomical situation (Table 1). Splinting therapy should be started within the first sixth weeks of life in order not to miss the best time of treatment<sup>[30, 31]</sup>. In cases, which are detected early, conservative treatment can be completed before walking age. Uncritical splinting which is not adapted to the given sonographic pathoanatomical situation of the hip or noncompliance of the parents during the splinting phase often leads to surgery with the need for open reduction even when early diagnosed<sup>[16, 25]</sup>.

#### 1.2 DDH after walking age

In cases of DDH after walking age, surgery to correct acetabular anatomy is always required. Operative interventions should be performed before the age of five years in order to provide complete anatomical recovery<sup>[13, 27, 39]</sup>.

Table 1: Sonographic-based treatment system according to the given hip types

Stage	Findings	Therapy	Alternative
Reduction	IV, III, D	Manual reduction	Reduction orthosis (i.e. Pavlik harness,...)
Retention	Reduced IV, III, D IIc unstable	Fettweis plaster cast in human position	Retention orthosis (i.e. Pavlik harness,...)
Maturity	II a -, IIb, IIc stable	Abduction device according to Mittelmeier-Graf	Maturity orthosis (i.e. Pavlik harness, Tübinger orthosis,...)

##### 1.2.1 Neglected cases of dislocation after walking age

In countries with general ultrasound screening programs neglected dislocated hips have become rare cases<sup>[16, 25]</sup>. Clinical findings in children with neglected hip dislocation after walking age are limping because of the shortened leg combined with restricted range of motion (restricted abduction and flexion contracture) and abductor muscle insufficiency (Trendelenburg gait). In bilateral cases, compensatory hyperlordosis of the lumbar spine may be evident.

The therapeutic management depends on the age of the child and the pathomorphology of the acetabulum and the femur. In unilateral and bilateral cases of hip dislocation, the upper age limit for an open reduction is 8 years<sup>[27]</sup>. Due to the morphological changes of the hip joint in this age group, open reduction should be performed with pelvic and femoral varisation-, derotation- and shortening-osteotomies in a single stage procedure (Fig. 1a, b). Femoral shortening is necessary to reduce the risk of osteonecrosis following open reduction in older children<sup>[13, 41]</sup>.



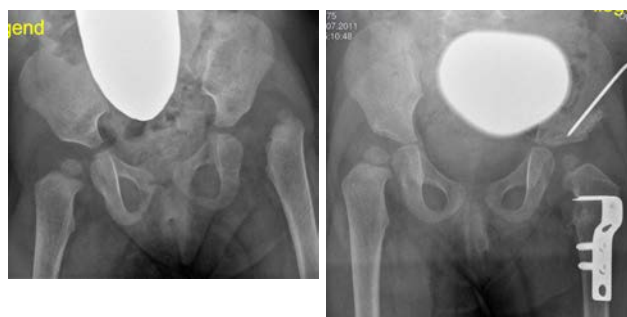


Figure 1a: Two years old girl with unilateral untreated dislocation of the left hip. Figure 1b: The reduced left hip of the same girl. Six weeks after open reduction, Pemberton acetabuloplasty and femoral osteotomy (varus, shortening and derotation).

The type of pelvic osteotomy depends on the age of the patient and the degree of acetabular dysplasia. Pemberton acetabuloplasty is preferred in children less than 6 to 7 years with a shallow and steep acetabulum. This intervention keeps the pelvic ring intact and can be performed in bilateral cases in one step. Pin fixation is often not necessary. Salter innominate osteotomy represents a redirection osteotomy with the symphysis as the center of rotation. The upper age limit is about 8 years.

### 1.2.2 Residual dysplasia of the hip after walking age

During periods of growth spurts the anatomy of the hip can change rapidly and unexpected deterioration can occur especially in cases which have been treated before. Children with treated DDH in the first year of life should be followed radiographically to detect residual or recurrent acetabular dysplasia or subluxation [1, 22].

In childhood residual dysplasia and subluxation of the hip may not have clinical signs or symptoms. Diagnosis is made according to the radiographs. Radiographic assessment should be performed by measuring the acetabular index or the center edge angle on AP radiographs. Residual dysplasia is evident if the acetabular index is over 25 degrees and the center edge angle under 20 degrees in the age of three [45]. The subluxated hip shows a lateralization of the femoral head. The Shenton line may be disrupted (Fig. 2).

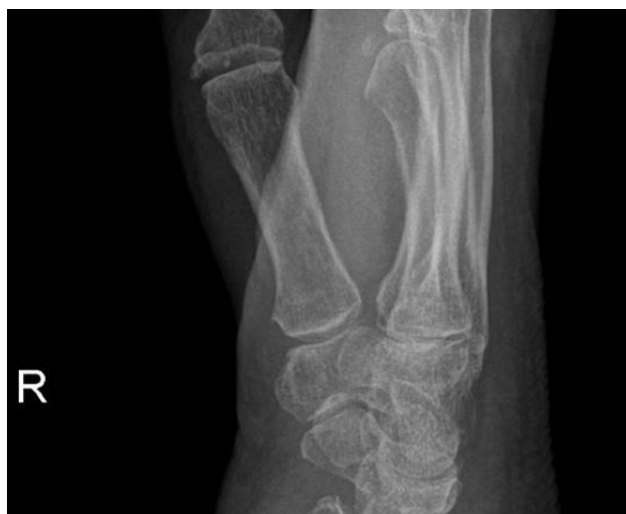

Figure 2: Three-years-old girl with bilateral treated dislocation of the hip at the age of five months (closed reduction of the right hip, open reduction of the left hip). At follow up both hips show residual acetabular dysplasia with subluxation of the right hip and disrupted Shenton lines on both sides.

Surgical treatment includes different types of pelvic and femoral osteotomies to improve the coverage of the femoral head and to achieve nearly normal anatomy. Pemberton acetabuloplasty and Salter innominate osteotomy are preferred in the younger age group. In children, older than 8 years, with residual acetabular dysplasia the triple pelvic osteotomy is often the method of choice to correct hip dysplasia when spherical congruity is present. During this procedure, the acetabulum becomes a free, rotating fragment, and overcorrection, impingement and retroversion of the acetabulum can occur. The triple pelvic osteotomy is a challenging procedure and requires an experienced surgeon. After closure of the triradiate cartilage, the periacetabular osteotomy (PAO) according to Ganz, another challenging procedure, can be performed in cases with mild osteoarthritis (Toennis < 2) and femoral head sphericity.

### 1.2.3 Osteonecrosis (ON) of the hip after treatment of DDH

ON of the proximal femoral epiphysis is one of the main complications associated with the treatment of developmental dislocated hips. The overall rates of ON reported in studies have been inconsistent, ranging from 6% to 88% after treatment of the dislocated hip [12, 36]. The complication can lead to acetabular dysplasia, femoral head asphericity and joint incongruity which may result in early hip osteoarthritis.

Clinical symptoms vary according to severity from limping, to restricted range of motion and hip pain if osteoarthritis is progressive. Radiographs are characterized by acetabular dysplasia, deformed femoral epiphysis and femoral neck shortening. The Bucholz-Odgen system is most widely used to classify ON into four types (grade I to IV) [6].

The treatment goal is to achieve remodeling of the deformed femoral head by concentric reduction and pelvic osteotomy. Additionally, femoral valgisation osteotomy, intertrochanteric double osteotomy with trochanteric advancement or greater trochanter transfer are often necessary (Fig. 3a, b).

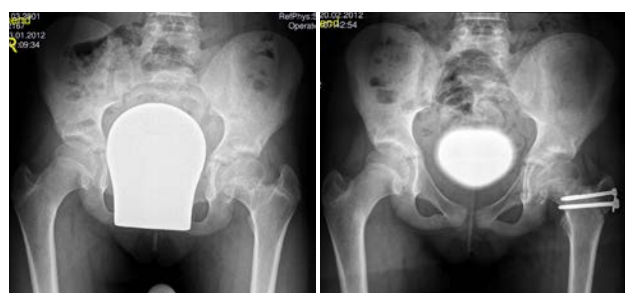

Figure 3a: 11-years-old girl with a closed reduction of the dislocated left hip at the age of five months. At follow up signs of osteonecrosis with a trochanteric overgrowth were evident.

Figure 3b: Three months after the trochanteric advancement surgery. The greater trochanter is now below the level of the top of the femoral head.

## 2. Transient (toxic) Synovitis

Transient synovitis of the hip joint is probably one of the most common cause of hip pain and responsible for the majority of cases of limping. The hip joint is irritated because of an effusion underlying inflammatory synovitis. There is often a history of antecedent viral illness [43].

Transient synovitis is seen in children between 3 and 8 years and manifests with the rapid onset of hip pain, limited range of motion and limping. Clinical presentation may mimic that of septic arthritis. Patients rarely have a body temperature above 38° or indication of systemic illness. The blood parameters are usually within normal limits and hip radiographs are normally unremarkable. Ultrasound of the affected hip may show effusion with an increased distance between the femoral neck and the joint capsule <sup>[4]</sup>.

Treatment include a brief period of bed rest and the use of nonsteroidal anti-inflammatory drugs to expedite spontaneous resolution of the inflammatory synovitis. Clinical symptoms usually resolve completely over several days.

3. Septic Arthritis

Septic arthritis of the hip requires urgent medical management because of the potential for significant joint destruction. Patients present with the acute onset of hip pain like children with transient synovitis. They may walk with a limp and have a history of antecedent infection, trauma or illness. Unlike transient synovitis, septic arthritis progresses to a febrile systemic illness with fever, chills and malaise. Local clinical symptoms are obvious: swelling of the joint, erythema, warmth, tenderness and the child holds the affected extremity immobile in an abducted, flexed and external rotated position.

Laboratory values (WBC count, C-reactive protein, and ESR) are usually elevated and are helping to distinguishing septic arthritis from transient synovitis of the hip <sup>[8, 23]</sup>. Radiographs remain normal following several days after initial symptoms. Lateralization and subluxation of the femoral head because of the massive effusion can occur. Ultrasound demonstrates joint effusion. A sonographic differentiation between septic or transient synovitis is usually not possible. If clinical suspicion for osteomyelitis remains high, consideration should be given to a supplemental MRI <sup>[32]</sup>.

Treatment should be urgent and requires immediate surgical drainage of the joint and the metaphysis in cases of additional underlying osteomyelitis of the proximal femur. The metaphysis is located intra-articular and may produce septic arthritis. Intravenous antibiotic therapy starts immediately with empirical antibiotics coverage and should be changed according to the antibiotic sensitivity of obtained cultures <sup>[33]</sup>.

According to the recommendation to start urgent treatment in cases of septic arthritis, the hip joint can be saved without morphological changes. In late treated cases, deformities vary from subluxation to complete destruction of the proximal femur (Fig. 4).

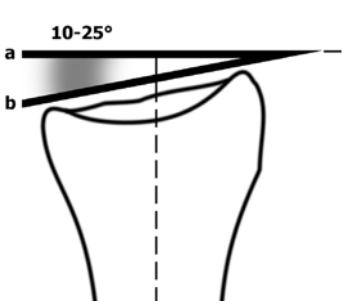


Figure 4: Radiograph of a three-years-old girl after neonatal septic arthritis of the right hip. Complete destruction of the femoral head and neck are visible.

4. Legg-Calve-Perthes Disease (LCPD)

Legg-Calve-Perthes Diseases (LCPD) is a femoral head disorder of unknown etiology. It involves temporary interruption of the blood supply to the bony nucleus of the proximal femoral epiphysis, impairing the epiphyseal growth and increasing bone density. The necrotic bone is subsequently replaced by new bone. Once the new bone of the femoral head is contained within the acetabulum, the femoral head slowly remodels until skeletal maturity. This process may flattening and enlarging the femoral head <sup>[5]</sup>.

LCPD is four times more common in boys than in girls, and the disease has been reported in patients from 2 to 12 years <sup>[47]</sup>. At clinical examination, the most common presenting symptom is a painless limping. Pain, if present, may be localized in the groin, thigh or knee region. Hip motion, primarily internal rotation and abduction, is limited. Atrophy of the muscles of the thigh or calf secondary to pain may be evident. Diagnosis is made according to the clinical symptoms and the typical radiographic findings <sup>[46]</sup>.

LCPD has been divided into four radiographic stages (Table 2):

- In the initial stage, a decreased size of the ossific nucleus, lateralization of the femoral head, a subchondral fracture, and physeal irregularity may be evident.
- In the fragmentation stage, the epiphysis appears fragmented with areas of radiolucency and radiodensity.
- During the reossification stage, the bone density returns to normal by new bone formation.
- In the residual stage, the radiographic findings include a gradual remodeling of the head shape and the acetabulum until skeletal maturity.

Table 2: Radiographic stages in Legg-Calve-Perthes Disease	
Stage	Findings
Initial stage	Lateralization of the femoral head and smaller ossific nucleus Subchondral fracture
Fragmentation stage	Segments of femoral head are demarcated Lucent areas appear Increased density resolves
Reossification stage	New bone formation occurs in the femoral head
Residual stage	Acetabulum and head shape remodels gradually until skeletal maturity

Several radiographic classification systems are currently used:

1. Catterall proposed a four-group classification, based on the amount of the involvement of the femoral epiphysis (Catterall group I-IV) <sup>[9]</sup>.
2. Salter and Thompson reported a two-group classification based on the extent of subchondral fracture, which corresponded to the amount of subsequent resorption (Salter-Thomson group A and B) <sup>[38]</sup>.
3. The Herring lateral pillar classification is the most widely used radiographic classification system helping to determine treatment and prognosis during the fragmentation stage of the disease. The degree of involvement of the lateral pillar can subdivided into three groups (Herring group A, B and C) <sup>[18]</sup>.

Catterall identified prognostic factors, known as radiographic "head-at-risk" signs, associated with poor results [10]. These "head-at-risk" signs include the following:

1. Lateral subluxation of the femoral head;
2. Gage sign: radiolucency in the lateral epiphysis and metaphysis;
3. Calcification lateral to the femoral epiphysis;
4. Horizontal physeal line.

The main goal of the treatment is to contain the femoral head in the acetabulum during the active period of the disease. This "containment" provides remodeling of the femoral head to the same shape of the acetabular cup, creating a spherical, well-covered femoral head with a normal hip range of motion. Various nonoperative and operative treatment methods for containment were developed over time (bracing, casting, physiotherapy, muscle release, trochanter epiphseodesis and combined femoral and pelvic osteotomy ("super-containment")). The choice of treatment is based on the severity of involvement and age of onset and based on the surgeon's experience and institutional treatment protocol. There is still a lack of consensus among the pediatric orthopedic surgeons.

Our institutional treatment philosophy includes the following:

- 1) Nonoperative containment is used in patients younger than 6 years at onset and Herring A and B. Symptomatic treatment includes nonsteroidal anti-inflammatory medication, reduction of activities and physiotherapy to increase range of motion.
- 2) Operative treatment is indicated in patients after the age of 6 years at onset and Herring B, B/C and in all patients regardless of age with Herring C or "head-at-risk" signs.

Till age of 6 years, Salter innominate osteotomy may increase the femoral head containment. Salter osteotomy and femoral varus osteotomy ("super-containment") in combination is indicated in patients younger than 8 years (Fig. 5a, b). In older children triple pelvic osteotomy is indicated. In all groups, hip range of motion should be achieved before operative containment. In cases of aspherical incongruency and hinge abduction secondary containment or salvage procedures are used: valgus femoral osteotomy, femoral neck lengthening, shelf acetabuloplasty, cheilectomy and Chiari osteotomy [7, 11, 34, 40].

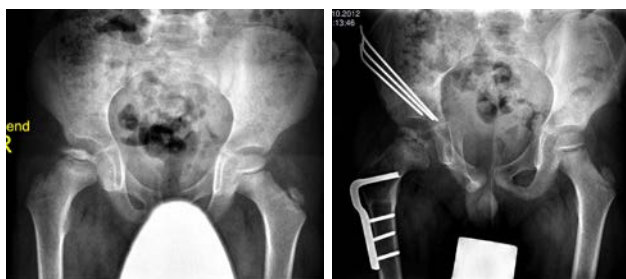

Figure 5a: Seven-year-old boy suffering from Perthes disease on the right hip. Radiological signs of "head-at-risk" with lateralization of the femoral epiphysis, horizontal physeal line and the Gage sign are evident.

Figure 5b: Radiographs of the same boy, five months after Salter innominate and femoral varus osteotomy. The femoral head is well covered.

involves the displacement of the femoral epiphysis from the metaphysis. In early adolescence, the growth plate is weaker and vulnerable, as it carries about four times its body weight. If obesity or trauma is added to the physeal weakness, the growth plate may fail gradually or acutely. SCFE occurs in about 2 in 100 000, most commonly in obese boys. It is bilateral in about one-fourth of cases, with possibly slight silent slippage in even more [21, 29].

SCFE may be classified according to onset of symptoms (acute, chronic or acute on chronic) or according to ability of weight bearing (unstable or stable). Clinical symptoms include: 1. Pain in the affected hip or groin or referred to the anteromedial thigh, 2. Limited hip range of motion (decreased internal rotation and abduction) 3. Gait abnormality. The symptoms and clinical findings vary according to whether the symptoms are acute, acute-on-chronic or chronic, whether the slip is stable or unstable, and with the coexistence of osteonecrosis or chondrolysis [2, 28]. Plain radiographs in anteroposterior and lateral views are the primary imaging studies needed to evaluate SCFE. Southwick recommended measuring the femoral-head-shaft angle on frog-leg lateral views. The head-shaft angle is less than 30 degrees in mild slips, between 30 and 50 degrees in moderate slips, and more than 50 degrees in severe slips [42].

Treatment can be divided into two categories: treatment to prevent further slippage in mild and moderate cases, and treatment to reduce the degree of slippage in severe slips. Prevention of further slippage in mild and moderate slips can be accomplished by in situ pinning or screw fixation. In situ fixation allows a minimal invasive, percutaneously performed treatment with the goal to stabilize the femoral epiphysis to the femoral neck. The fixation device must be placed perpendicular to the plane of the proximal femoral epiphysis and must be of appropriate strength to avoid failure before physeal plate closure. Almost all SCFEs should be able to be stabilized with percutaneous placement of a single 6.5- to 7.5-mm cannulated screw [14, 17, 24]. Because of the high prevalence of contralateral slip, prophylactic pinning is recommended with several risk factors including young age, obesity, endocrine disorders [20] and increased posterior sloping angle [35].

Surgical treatment methods reducing the degree of slip off are the acute open reduction and subcapital osteotomy through a Ganz surgical hip dislocation approach, and intertrochanteric osteotomy according to Imhaeuser/Southwick for deformity correction [19, 26, 42]. The choice of treatment to reduce the degree of slip is based on the surgeon's experience. Ganz surgical hip dislocation and open reduction is a technically challenging procedure (Fig. 6a, b). Intertrochanteric osteotomies remain the most frequently used procedures for realignment in SCFE. Two major complications, osteonecrosis and chondrolysis, are specifically associated with SCFE. After the diagnosis has been made, treatment must be directed at maintaining motion and preventing collapse including anti-inflammatory medication and relieved weight-bearing until healing occurs.

## 5. Slipped Capital Femoral Epiphysis (SCFE)

Slipped capital femoral epiphysis (SCFE) is a well-known hip disorder that affects adolescents between 11 and 15 years, and

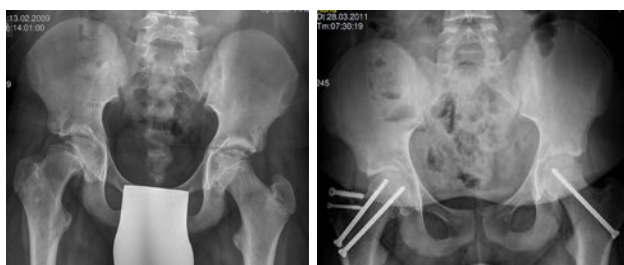

Figure 6a: 14-year-old boy with a severe, chronic slipped capital femoral epiphysis of 60 degrees.

Figure 6b: Radiographs of the same boy two years after surgery. The right hip was treated with open reduction and subcapital osteotomy through a surgical dislocation approach. The left hip was fixed prophylactically with a cannulated single screw.

## References

1. Albinana J, Dolan LA, Spratt KF, Morcuende J, Meyer MD, Weinstein SL. Acetabular dysplasia after treatment for developmental dysplasia of the hip. Implications for secondary procedures. *J Bone Joint Surg Br.* 2004;86:876–886.
2. Aronson J, Tursky EA. The torsional basis for slipped capital femoral epiphysis. *Clin Orthop Relat Res.* 1996;37–42.
3. BARLOW TG. EARLY DIAGNOSIS AND TREATMENT OF CONGENITAL DISLOCATION OF THE HIP. *Proc R Soc Med.* 1963;56:804–806.
4. Bickerstaff DR, Neal LM, Booth AJ, Brennan PO, Bell MJ. Ultrasound examination of the irritable hip. *J Bone Joint Surg Br.* 1990;72:549–553.
5. Bowen JR, Foster BK, Hartzell CR. Legg-Calvé-Perthes disease. *Clin Orthop Relat Res.* 1984;97–108.
6. Bucholz R OJ. Patterns of ischemic necrosis of the proximal femur in nonoperative treated congenital hip disease. 1978. St. Louis, MO: C. V. Mosby.
7. Bursal A, Erkula G. Lateral shelf acetabuloplasty in the treatment of Legg-Calvé-Perthes disease. *J Pediatr Orthop B.* 2004;13:150–152.
8. Caird MS, Flynn JM, Leung YL, Millman JE, D'Italia JG, Dormans JP. Factors distinguishing septic arthritis from transient synovitis of the hip in children. A prospective study. *The Journal of Bone and Joint Surgery-American Volume.* 2006;88:1251–1257.
9. Catterall A, Pringle J, Byers PD, Fulford GE, Kemp HB, Dolman CL, Bell HM, McKibbin B, Rális Z, Jensen OM, Lauritzen J, Ponseti IV, Ogden J. A review of the morphology of Perthes' disease. *J Bone Joint Surg Br.* 1982;64:269–275.
10. Catterall A. The natural history of Perthes' disease. *J Bone Joint Surg Br.* 1971;53:37–53.
11. Chairi K, Endler M, Hackel H. [Treatment of coxa magna in Perthes disease by pelvic osteotomy (author's transl)]. *Arch Orthop Trauma Surg* (1978). 1978;91:183–190.
12. Firth GB, Robertson AJF, Schepers A, Fatti L. Developmental dysplasia of the hip: open reduction as a risk factor for substantial osteonecrosis. *Clin Orthop Relat Res.* 2010;468:2485–2494.
13. Galpin RD, Roach JW, Wenger DR, Herring JA, Birch JG. One-stage treatment of congenital dislocation of the hip in older children, including femoral shortening. *The Journal of Bone and Joint Surgery-American Volume.* 1989;71:734–741.
14. Goodman WW, Johnson JT, Robertson WW. Single screw fixation for acute and acute-on-chronic slipped capital femoral epiphysis. *Clin Orthop Relat Res.* 1996;86–90.
15. Graf R. *Hip Sonography.* Springer
16. Grill F, Müller D. [Results of hip ultrasonographic screening in Austria]. *Orthopade.* 1997;26:25–32.
17. Herman MJ, Dormans JP, Davidson RS, Drummond DS, Gregg JR. Screw fixation of Grade III slipped capital femoral epiphysis. *Clin Orthop Relat Res.* 1996;77–85.
18. Herring JA, Neustadt JB, Williams JJ, Early JS, Browne RH. The lateral pillar classification of Legg-Calvé-Perthes disease. *Journal of Pediatric Orthopaedics.* 1992;12:143–150.
19. IMHAUSER G. [Surgical treatment of pathological anteversion of the proximal femur]. *Z Orthop Ihre Grenzgeb.* 1954;85:395–405.
20. Jerre R, Billing L, Hansson G, Wallin J. The contralateral hip in patients primarily treated for unilateral slipped upper femoral epiphysis. Long-term follow-up of 61 hips. *J Bone Joint Surg Br.* 1994;76:563–567.
21. Kelsey JL, Keggi KJ, Southwick WO. The incidence and distribution of slipped capital femoral epiphysis in Connecticut and Southwestern United States. *The Journal of Bone and Joint Surgery-American Volume.* 1970;52:1203–1216.
22. Kim HT, Kim JI, Yoo CI. Acetabular development after closed reduction of developmental dislocation of the hip. *Journal of Pediatric Orthopaedics.* 2000;20:701–708.
23. Kocher MS, Zurakowski D, Kasser JR. Differentiating between septic arthritis and transient synovitis of the hip in children: an evidence-based clinical prediction algorithm. *The Journal of Bone and Joint Surgery-American Volume.* 1999;81:1662–1670.
24. Koval KJ, Lehman WB, Rose D, Koval RP, Grant A, Strongwater A. Treatment of slipped capital femoral epiphysis with a cannulated-screw technique. *The Journal of Bone and Joint Surgery-American Volume.* 1989;71:1370–1377.
25. Kries von R, Ihme N, Oberle D, Lorani A, Stark R, Altenhofen L, Niethard FU. Effect of ultrasound screening on the rate of first operative procedures for developmental hip dysplasia in Germany. *Lancet.* 2003;362:1883–1887.
26. Leunig M, Slongo T, Kleinschmidt M, Ganz R. Subcapital correction osteotomy in slipped capital femoral epiphysis by means of surgical hip dislocation. *Oper Orthop Traumatol.* 2007;19:389–410.
27. Lindstrom JR, Ponseti IV, Wenger DR. Acetabular development after reduction in congenital dislocation of the hip. *The Journal of Bone and Joint Surgery-American Volume.* 1979;61:112–118.
28. Loder RT, Richards BS, Shapiro PS, Reznick LR, Aronson DD. Acute slipped capital femoral epiphysis: the importance of physeal stability. *The Journal of Bone and Joint Surgery-American Volume.* 1993;75:1134–1140.
29. Loder RT. The demographics of slipped capital femoral epiphysis. An international multicenter study. *Clin Orthop Relat Res.* 1996;8–27.
30. Matthiessen HD. [Forensic problems in the treatment of hip dysplasias and dislocations]. *Z Orthop Ihre Grenzgeb.* 1996;134:0a10–2.
31. Matthiessen HD. [Dysplasia and therapy factors in hip developmental disorders]. *Z Orthop Ihre Grenzgeb.* 1997;135:0a12–3.



32. Mazur JM, Ross G, Cummings J, Hahn GA, McCluskey WP. Usefulness of magnetic resonance imaging for the diagnosis of acute musculoskeletal infections in children. *Journal of Pediatric Orthopaedics*. 1995;15:144–147.
33. Morrey BF, Bianco AJ, Rhodes KH. Septic arthritis in children. *Orthop. Clin. North Am.* 1975;6:923–934.
34. O'Connor PA, Mulhall KJ, Kearns SR, Sheehan E, McCormack D. Triple pelvic osteotomy in Legg-Calvé-Perthes disease using a single anterolateral incision. *J Pediatr Orthop B*. 2003;12:387–389.
35. Phillips PM, Phadnis J, Willoughby R, Hunt L. Posterior sloping angle as a predictor of contralateral slip in slipped capital femoral epiphysis. *The Journal of Bone and Joint Surgery-American Volume*. 2013;95:146–150.
36. Pospischill R, Weninger J, Ganger R, Altenhuber J, Grill F. Does open reduction of the developmental dislocated hip increase the risk of osteonecrosis? *Clin Orthop Relat Res*. 2012;470:250–260.
37. Rosendahl K, Markestad T, Lie RT. Ultrasound screening for developmental dysplasia of the hip in the neonate: the effect on treatment rate and prevalence of late cases. *Pediatrics*. 1994;94:47–52.
38. Salter RB, Thompson GH. Legg-Calvé-Perthes disease. The prognostic significance of the subchondral fracture and a two-group classification of the femoral head involvement. *The Journal of Bone and Joint Surgery-American Volume*. 1984;66:479–489.
39. Salter RB. Role of innominate osteotomy in the treatment of congenital dislocation and subluxation of the hip in the older child. *The Journal of Bone and Joint Surgery-American Volume*. 1966;48:1413–1439.
40. Salter RB. The present status of surgical treatment for Legg-Perthes disease. *The Journal of Bone and Joint Surgery-American Volume*. 1984;66:961–966.
41. Schoenecker PL, Strecker WB. Congenital dislocation of the hip in children. Comparison of the effects of femoral shortening and of skeletal traction in treatment. *The Journal of Bone and Joint Surgery-American Volume*. 1984;66:21–27.
42. Southwick WO. Osteotomy through the lesser trochanter for slipped capital femoral epiphysis. *The Journal of Bone and Joint Surgery-American Volume*. 1967;49:807–835.
43. Tolat V, Carty H, Klenerman L, Hart CA. Evidence for a viral aetiology of transient synovitis of the hip. *J Bone Joint Surg Br*. 1993;75:973–974.
44. Tönnis D. *Die angeborene Hüft dysplasie und Hüftluxation*. Berlin, Heidelberg, New York: Springer
45. Tönnis D. *Congenital dysplasia and dislocation of the hip in children and adults*. Springer Verlag
46. Weinstein SL. Legg-Calvé-Perthes disease. *Instr Course Lect*. 1983;32:272–291.
47. Wynne-Davies R, Gormley J. The aetiology of Perthes' disease. Genetic, epidemiological and growth factors in 310 Edinburgh and Glasgow patients. *J Bone Joint Surg Br*. 1978;60:6–14.

## Questions

1. The appearance of an acute osteomyelitis in childhood
  - a. is mainly induced by a focus of the gastrointestinal area
  - b. is most often caused by Streptococcus
  - c. is typically located in the diaphyseal area of long bones
  - d. is most often located in the metaphyseal area of long bones
  - e. is never penetrating to adjacent joints
2. Which criterion may be cause of an unfavorable result of Perthes disease?
  - a. Appearance before age 4
  - b. Initial joint effusion
  - c. Type Herring C
  - d. Reduced abduction during fragmental period
  - e. Conservative treatment for type Catterall II
3. The Bernese periacetabular osteotomy for correction of hip dysplasia is recommended after maturity because of
  - a. Tendency to overcorrection
  - b. Involvement of the triradiate cartilage
  - c. Tendency to undercorrection
  - d. Danger of impingement
  - e. To complicated during growth
4. Which condition CANNOT be found in cause of Femoroacetabular Impingement (FAI)?
  - a. Lack of acetabular coverage
  - b. Acetabular retroversion
  - c. Protrusion of the femoral head
  - d. Cross-over sign
  - e. Acetabular over-coverage
5. What is the most common age group for *Kingella kingae* infection?
  - a. Infants less than 6 months of age
  - b. Children above 4 years
  - c. Children between 6 months and 4 years
  - d. Teenagers
  - e. Adults

## Answers

1d, 2c, 3b, 4a, 5c.



Dr. Daniel Petek

HFR - Fribourg Hospitals - Fribourg, Switzerland

daniel.petek@h-fr.ch

## Knee: Surgical Treatment For Degenerative Changes

### Introduction

Symptomatic knee osteoarthritis (OA) is highly prevalent among people aged 50 years and over. The typical symptoms include effusion, joint pain and stiffness leading to loss of knee function. Patient history, physical examination, radiological and laboratory findings are the diagnostic criteria for knee OA. If, after a well-managed initial conservative treatment<sup>[1,2]</sup>, the symptoms are not relieved; surgery should be considered and consists of many options such as: arthroscopic debridement, cartilage repair, osteotomies around the knee and unicompartmental knee arthroplasty (UKA) or total knee arthroplasty (TKA). From those surgical procedures, arthroscopy alone in the management of an arthritic knee has become controversial as a randomised publication in 2002 has shown only minimal benefit in patient outcome<sup>[3,4]</sup>.

### 1. Osteotomies around the knee

Osteotomies around the knee are standard well-documented methods for the treatment of unicompartmental knee osteoarthritis associated with malalignment of the lower limb. These procedures belong to conservative surgery<sup>[5]</sup>. The aim is to unload an altered compartment of the knee and transfer the peak load by slightly overcorrecting into a valgus or varus axis in order to slow the degenerative process, reduce pain and delay joint replacement. Osteotomies may be done on either the distal femur or the proximal tibia, depending on the location of the deformity<sup>[6]</sup>. They have gained in popularity in the 1960 and consisted classically of a tibial valgisation closing wedge type including an osteotomy of the fibula as described by Coventry<sup>[7,8]</sup>. Later on, these procedures lost importance due to the success of knee arthroplasty. In addition, they were considered as demanding procedures associated with significant complications such as compartment syndrome, peroneal nerve palsy or infection<sup>[9]</sup>. Still, the development during the last 10 years of new fixation devices<sup>[10,11]</sup> (plates with angular stability) has brought osteotomies again into light, especially for younger and active patients.

#### 1.1 Patient selection

The outcome of such procedure is among others depending on proper patient selection<sup>[12]</sup>. The stage of OA shall be precisely addressed on radiological studies and if there already is a 4th grade wear (Kellgren- Laurence grading system<sup>[13]</sup>), only limited pain relief shall be expected. The range of motion is evaluated and at least 120° of flexion and no more than 10° of extension deficit are mandatory. Instability of the knee joint is not an absolute contraindication because tibial slope correction is used to address ACL or PCL deficient knees. The patellofemoral joint may show signs of degenerative changes but shall be asymptomatic. Considering the age, >65 years is a relative contraindication but the activity and biologic age must also be considered. The patient shall be non-smoker. A BMI under 30 gives the best results. Also, the patient shall not suffer from inflammatory diseases such as rheumatoid arthritis<sup>[14]</sup>.

#### 1.2 Preoperative planning

The key for a successful osteotomy is a correct pre-operative planning; therefore, it is important to understand the normal lower limb anatomy and its physiological angles and axes. The physiological mechanical axis of the total leg, also called "Mikulicz line", runs from the center of the femoral head to the center of the ankle joint and crosses the knee joint about 4 (± 2) mm medial to its center<sup>[15-18]</sup>. This point is used to quantify the mechanical axis deviation (MAD)<sup>[6]</sup> of the lower limb mechanical axis. It may be measured in millimetres from the center of the knee or like Fujisawa<sup>[19]</sup> described, as a percentage of a medial or lateral compartment (Fig. 1d). The anatomical axes of the femur and tibia correspond to the diaphyseal midline of these bones. The mechanical axis of the femur, running from its head to the center of the knee therefore forms an angle of  $6 \pm 1^\circ$  with the anatomical axis. The tibia has a mechanical axis nearly identical to the anatomical axis. Under physiological conditions, the tangent line to the femoral condyles is almost parallel to the tangent to the tibial plateau ( $0^\circ - 1^\circ$ ). The standard value of the mechanical medial proximal tibial angle (mMPTA) is of  $87^\circ \pm 3^\circ$ . On the other hand, the value of the mechanical lateral distal femoral angle (mLDFA) is also of  $87^\circ \pm 3^\circ$ . These latter values will be used to locate and address the deformity<sup>[15,16]</sup> (Fig. 1 a-c).

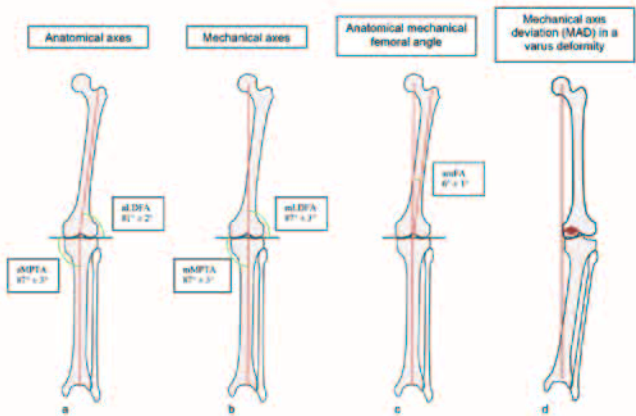


Fig. 1: (a-c) Anatomical and mechanical angle values of the femur and the tibia. (d) Measurement of the MAD (mm) from the knee centre in a varus deviation. aMPTA: anatomical mechanical proximal tibial angle. aLDFA: anatomical lateral distal femoral angle. mMPTA: mechanical medial proximal tibial angle. mLDFA: mechanical lateral distal femoral angle. amFA: anatomical – mechanical femoral angle.

1.3 Measurement and localisation of the axial deformity

The lower limb deformities occur most often in the frontal plane and are described as varus or valgus deviations. This malalignment is defined as a varus when the weight bearing axis of the lower limb runs medial to the center of the knee and valgus when it runs lateral to the center. The measures of the anatomical and mechanical angles of the distal femur and the proximal tibia are then necessary to point out the location of the deviation because axial deviations may exist due to isolated femur or tibia deformation, or due to a combination of both (Fig. 2 a–b) [6,15–17]. These more complex situations often need double osteotomies around the knee.

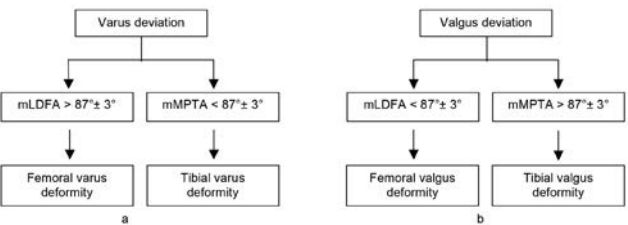


Fig. 2: (a–b) Femoral and tibial analysis of varus and valgus deformity

1.4 Level of the osteotomy

On optimal correction is obtained when the osteotomy is performed at the apex of the deformity and depends of the preoperative planning. It may be done either on the distal femur or proximal tibia, or both. The osteotomy line shall stay in the metaphyseal bone because of better healing properties. The open-wedge osteotomies are generally easier and more precise to achieve than closing-wedge and in most of cases there is no need for bone grafting if an implant with angular stability is used [10,11].

1.5 Correction

The first goal of an osteotomy is to achieve a correction in the frontal plane to unload an altered knee compartment as described above. However, it may also influence the sagittal and transverse planes [20–22]. A correction of the sagittal plane is used in cases of anterior or posterior knee instability by varying the tibial slope. In case of a chronic ACL insufficiency, the tibial slope shall be decreased up to  $5^\circ$  (extension osteotomy) in order to improve the sagittal instability and gain some extension. In posterior or posterolateral knee instabilities, the slope shall be increased up to  $12^\circ$  (flexion osteotomy) to reduce the posterior subluxation of the tibia and to eliminate the hyperextension of the knee [23]. Corrections in the transverse plane are rare and are used to correct rotational deformities. As the patellar tracking may be significantly altered, the patellofemoral alignment shall be analysed and understood preoperatively. These specific torsional deformities mostly belong to congenital torsion deformities of the lower extremity and are a consequence of growth disorders of the acetabulum, femur, tibia and foot. [24] These particular conditions are not addressed in this review.

1.6 Preoperative drawing

Several methods for osteotomy planning have been described in the literature. Loebenhoffer and al. have developed an accurate technique to define the correction angle based on the study by Fujisawa and the planning method described by Miniaci [15–19]. In facts, a varus malalignment is brought to a slight overcorrection, in the lateral compartment depending on the severity of the medial cartilage loss [19,21]. On the other hand, a valgus deformity is corrected up to neutral [25]. As an example, for a high tibial valgus osteotomy, first trace the Mikulicz line and then draw the new weight-bearing line from the centre of the hip and passing through the lateral compartment of the knee at the chosen level. Define the hinge of osteotomy, one centimetre from the lateral cortex of the tibia and connect it distally to the old and new centre of the ankle. These two lines form the correction angle that is then reported in the proximal metaphyseal portion of the proximal tibia (Fig. 3 a–c).

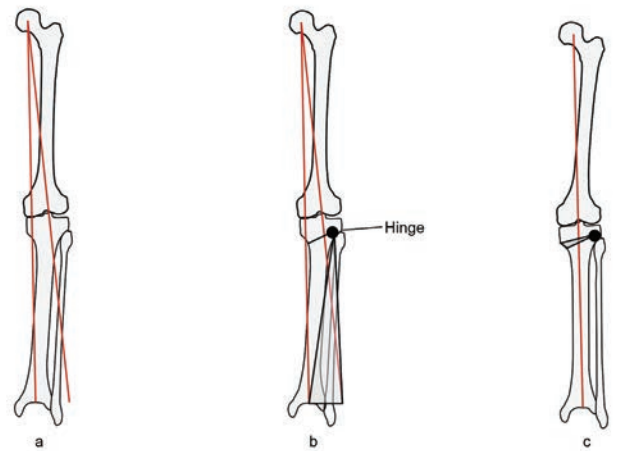


Fig.3: (a–c) Determination of the correction angle in high tibial osteotomy opening wedge (Miniaci)

## 1.7 Surgery and fixation

As an example for a high-tibial open-wedge valgisation osteotomy, the surgical procedure will start with a knee arthroscopy to evaluate and document the amount of cartilage in the lateral compartment (Fig. 4 a-b). An adjuvant treatment such as microfractures, osteochondral autograft transfers, matrix-associated chondrocyte implantations or others may be done during the same procedure.

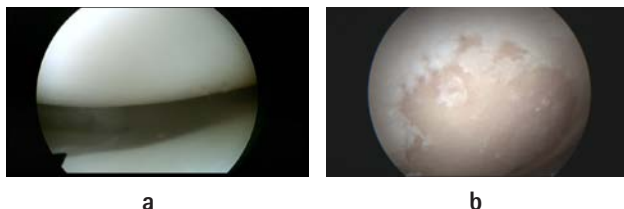


Figure 4: Arthroscopic views of a right knee.  
a Lateral compartment.  
b Medial compartment with cartilage wear

A longitudinal skin incision to expose the medial part of the tibial metaphysis may be selected as it may be used again for future surgeries (total knee arthroplasty). However, in younger patients, a MIPO approach, using an oblique incision is also possible and preferable due to better healing properties. This will allow a better skin coverage of the osteotomy site and diminish the stress on soft-tissue due to retractors.

The pes anserinus is exposed and two guide wires are placed along the virtual osteotomy line. The proper position of the wires is checked with fluoroscopy in the frontal and sagittal planes. The medial and posterior tibial cortices are cut with a saw blade along the wires. The anterior ascending cut is then performed to free the anterior tibial tubercle.

The osteotomy is progressively and carefully completed with chisels. Take care to stop the osteotomy about 1 cm from the lateral cortex to preserve a lateral bony hinge. Once the gap is completed, a spreader can be introduced to progressively open the osteotomy line. This opening takes several minutes to prevent intra-articular fractures of the lateral tibial plateau.

As the superficial portion of the medial collateral ligament inserts on the postero-medial portion of the proximal tibia, the osteotomy tends to open more in its anterior portion. Therefore it is important to release enough the superficial fibres of the postero-medial corner of the proximal tibia to keep the tibial slope unchanged during the procedure. If necessary, at this stage, anterior or posterior knee instabilities can be treated by varying the tibial slope [20-22,26,27].

Once the planned correction is obtained, a definitive fixation is made by the insertion of a plate that is fixed with angular stability screws [11,12] (Fig. 5).

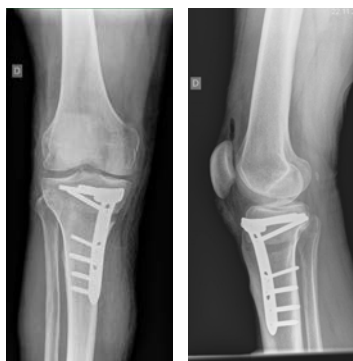

Fig. 5: Post-operative views of right knee after high-tibial opening-wedge valgisation osteotomy

## 2. Unicompartmental knee arthroplasty (UKA)

When describing the anatomy of the knee, three separate anatomic compartments are mentioned; medial, lateral and patellofemoral. Each may be individually considered in terms of replacement arthroplasty. The Australian Orthopaedic Association National Joint Replacement Registry has reported that 43,543 unicompartmental knee procedures have been implanted in 2014 (increase by 4,6% compared to 2013). Osteoarthritis remains the principal diagnosis, accounting for 99% of primary unicompartmental knee replacements. These procedures are most frequently undertaken in patients aged between 55 and 74 years.

### 2.1 Unicompartmental knee arthroplasty

Unicompartmental knee arthroplasties (UKA) may be used to treat unicompartmental arthritis of either the medial or lateral knee compartment. In about 80% to 90% of patients, the medial compartment is involved and replaced [30] (Fig. 6). For a successful UKA, the patient selection plays an important role [28,29]. The cruciate ligaments as well as the remaining two compartments must be well preserved in order to allow proper knee kinematics. A preoperatively correctable varus or valgus deformity to neutral alignment, a flexion contracture less than 10° and a minimum of 90° of flexion are mandatory. A fixed deformity will not be adequately balanced during surgery so that the implant will be overstressed and will likely fail. Also, there shall not be a collapse of the opposite compartment on stress radiographs and the patient should not suffer from an inflammatory disease. UKA is contraindicated in patient with high demand or labourer as well as those in overweight (>90kg).

The main advantage of the UKA is that it is a less aggressive surgery where the extensor mechanism is not damaged, thus allowing a quicker recovery. Also, it preserves the bone stock and normal knee kinematics for a more physiological function and fewer short term complications [31].

Recent reports have described 10 years survival rates of 80.2% to 98% [32]. Although, these are respectable results, it is still generally accepted that total knee arthroplasties have a better long-term survival. The Australian registry has recorded 4,874 revisions of primary unicompartmental knee replacements. The main reasons for revision are loosening/lysis (44.0%), progression of disease (28.4%) and persistent pain (9.9%). The main type of revision is to a total knee arthroplasty (86.4%)

The outcome for UKA is variable and ranges from 80.2 to 98% in terms of 10-years survival. Still, UKA has a significantly poorer long-term survival than total knee arthroplasty.

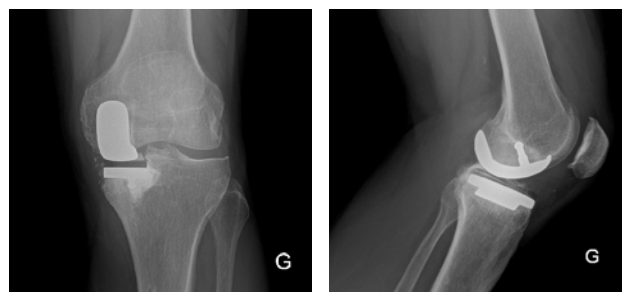


Figure 6: Medial UKA.



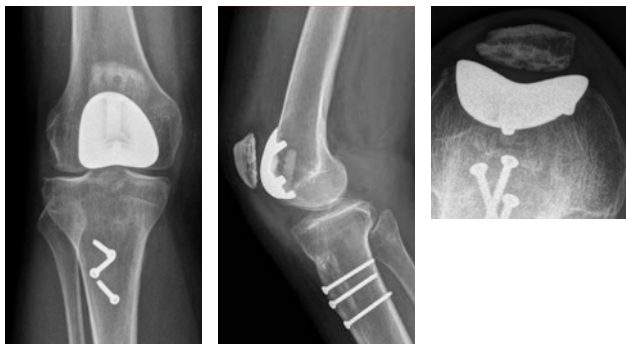


Fig: 7 Patello – femoral arthroplasty

2.2 Patellofemoral arthroplasty

Isolated patellofemoral OA occurs in about 9% of patients over 40 years old in is predominant in females. Underlying causes include prior patellar fractures, patellar instability (patellar maltracking, trochlear dysplasia) and ancient surgery. The number of patellofemoral arthroplasties is rising but remains low because such arthroplasty often leads to failure and the results are frustrating [34]. Therefore, TKA should be considered as standard also for patellofemoral OA, especially for elderly patients.

3. Total knee arthroplasty

Total knee arthroplasty is a safe, cost-effective procedure for the management of advanced stage knee OA and results in a significant improvement of life quality. According to the Australian register the rate of implantation is rising (5.2% more in 2014 than in 2013) and the most common diagnosis for primary total knee replacement is osteoarthritis (97.5%), followed by rheumatoid arthritis (1.5%). Prosthetic survival reaches now 90% to 99% at 10 years. It seems to sink at 80% at 15 years and at about 75% after 20 years [35,39].

Besides these very satisfactory results, some studies document that more than 50% revisions after TKA occur within the first five years [39,40].

The main indications for early revising a TKA are the loosening of components, femoropatellar pain, instability and infection. The Australian register reports loosening/lysis as the main reason for revision (28.7%), followed by infection (22.4%), patellofemoral pain (12.1%), pain (8.8%) and instability (6.3%). Infection, even if it is devastating as a complication, is not related to the implant. Also, femoropatellar pain and instability have to deal with errors in the surgical technique. So, as a matter of fact, only loosening may be related to implant selection but also to the surgical technique.

Late causes of revision, essentially polyethylene (PE) wear and osteolysis, are multifactorial in aetiology [41].

Primary total knee replacement for osteoarthritic patients has the lowest revision rate according to the register. At 14 years, the cumulative percent revision for this indication is 7.2%. Age is considered as a major factor affecting the outcome of primary knee arthroplasties. The rate of revision increases with decreasing age. After three years, the register has noted that patients aged less than 55 years have over four times the rate of revision compared to those aged 75 years or older.

In order to improve the outcome and lower the rate of unsatisfactory results several options have been explored these last years and include the use of computer-assisted surgery (CAS), minimally invasive surgery (MIS), patient specific cutting bone guides, improvement of the design of implants and fixation of implants. Still, for a successful outcome, restoration of the mechanical alignment, preservation of the joint line, soft tissue balancing and femoral rotation remain essential [42,43].

Basically, there are three main designs of total knee prostheses; unconstrained, semi-constrained and constrained hinged. In the unconstrained category, two different types are used, the posterior cruciate retaining (CR) and the posterior cruciate substituting. In that latter group, one can differentiate the postero-stabilized (PS) and the ultra-congruent (UC) implant.

3.1 Preoperative planning

As already mentioned, a good preoperative planning and clinical evaluation are predictors of the clinical outcome of a TKA. Preoperative radiographs are used to identify the correction needed in alignment and points out the bony defects that will need bone grafting or augmentation (Fig. 7 Table 1).

Table 1. Preoperative X-Rays

- Standing full-length AP view form hip to ankle
- Standard AP and side view of the knee
- Standing AP (Rosenberg's) view in 45° of flexion
- Femoropatellar (Merchant's) view
- Varus / valgus stress views (optional)

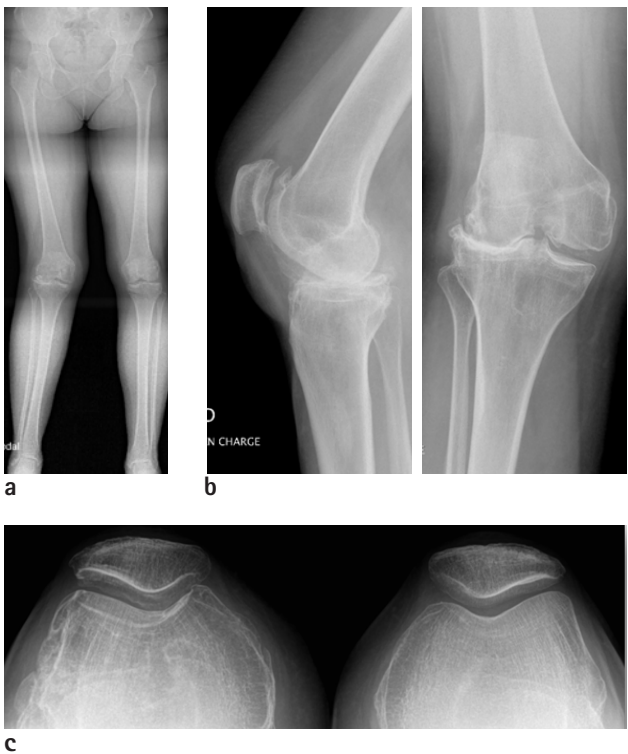

Figure 8: (a-c):

- a. Standing antero posterior view
- b. Frontal and lateral knee views
- c. Patellofemoral view

## 3.2 Mechanical alignment

It is important to clearly identify the mechanical and anatomical axes of the femur. The angle they form, called the valgus cut angle, allows a perpendicular distal femoral cut to the mechanical axis. In that situation, the femoral component will point toward the center of the femoral head and allows an optimal load share through the medial and lateral compartment. In most cases, this angle measures 5°– 7° (Fig. 8a). On the tibial side, the mechanical and anatomical axes are also identified and in most of the cases are the same. However, the axes may be divergent like in congenital deformities, post-traumatic conditions or after prior surgery such as closing wedge osteotomies. The aim is to have a proximal tibial cut perpendicular to the mechanical axis so that the lower limb stresses run through the center of the tibial plateau. The recommended coronal alignment is within 0° to 3° of varus–valgus <sup>[44,45]</sup>. Still, Parratte et al have found similar results between TKAs with more than 3° of coronal alignment compared to TKAs within the 3°. So, the debate is not over.

## 3.3 Preservation of the joint line

The goal is to remove sufficient amount of bone from the femur and the tibia so that the prosthesis when in place will re-create the original thickness of cartilage and bone. Also, the height of the joint line has to be respected in order to keep the patella in a proper position. Figgie et al have found that the patella shall be within 10 to 30 mm above the joint line. Cutting too much from the distal femur may lead to patella baja, what is poorly tolerated. In severe deformities, there is frequently a bone defect that has to be identified and restored. Bony defects of less than 1cm may be filled with screw and cement, whereas larger defects need metallic augmentation.

## 3.4 Soft-tissue releases

It is probably the most fundamental step in TKA. During the degenerative process, ligaments and soft tissues will become contracted on the concave side of the deformity and stretched to lose on the convex side (Fig. 8 b–c). For proper knee function these structures need to be released and balanced in the frontal and sagittal planes. For example, in case of a varus deformity, the medial side will be concave and require a release. The release shall be progressive until the initial deformity is corrected to the neutral axis in the frontal plane and until an adequate balance in extension is reached <sup>[47]</sup>. In the frontal plane, the anatomical structures to be released in a varus (Table 2) or valgus (table 3) condition are listed below.

Figure 9: (a–c):

- a. Measure of the femoral valgus cut angle  
b. Medial contracted structures in varus deformity  
c. Lateral contracted structures in valgus deformity

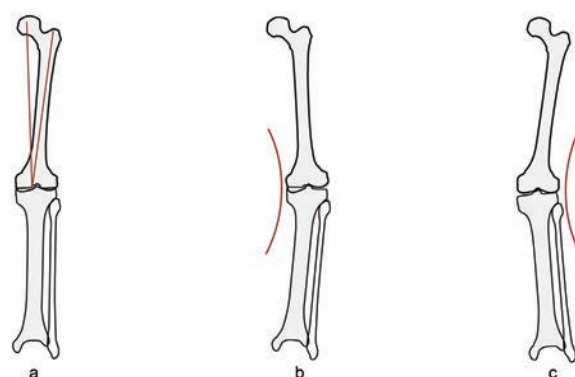
Table 2. Varus Deformity
MEDIAL RELEASE
<ul style="list-style-type: none"> <li>• Osteophytes</li> <li>• PCL (if not PCL retaining)</li> <li>• MCL deep portion</li> <li>• Posteromedial corner</li> <li>• Semi- membranous</li> <li>• Pes anserinus</li> </ul>

Table 3. Valgus Deformity
LATERAL RELEASE

- Osteophytes
- PCL
- Lateral capsule
- Posterolateral corner
- Ilio – tibial band from Gerdi
- Lateral condyle osteotomy

## 3.5 Exention – flexion gaps

When addressing the sagittal plane, the surgeon shall keep in mind that the physiological knee presents two curvatures; one for the patellofemoral articulation and one for the weight bearing portion of the knee. Therefore, to achieve a correct balancing in flexion and extension, it is necessary to perform a correct tissue release and proceed to an adequate amount of bone resection. The knee will be well balanced in the sagittal plane if the tibial insert remains stable



during the full range of motion. As a general rule, if the gap problem is symmetric the tibia needs to be adjusted whereas if the gap problem is asymmetric the femur needs an adjustment (Table 4).

Table 4. Sagittal Plane Balancing		
SITUATION	PROBLEM	SOLUTION
Tight in flexion and extension	Symmetric gap	Cut more tibia
Loose in flexion and extension	Symmetric gap	1. Thicker insert 2. Metallic tibia augmentation
Tight in extension Good in flexion	Asymmetrical gap	1. Release posterior capsule 2. Cut more distal femur
Good in extension Tight in flexion	Asymmetrical gap	1. Resect PCL if not done 2. Decrease size of the femoral component 3. Check tibial slope
Good in extension Loose in flexion	Asymmetrical gap	Increase size of the femoral component (posterior metallic augmentation)
Loose in extension Good in flexion	Asymmetrical gap	Distal femoral augmentation

## 3.6 Patellofemoral alignment

To prevent patellofemoral maltracking <sup>[50,51]</sup> there are some situations to avoid as for instance, leaving an internal rotation of the femoral component. The latter shall be placed in a slight external rotation. This is because the tibia presents anatomically a light varus of about 3° and as the cut is made perpendicular to the tibial axis, the femoral component has to be externally rotated to create a symmetric flexion

gap. Two methods are used to get a correct rotation: the flexion gap balancing <sup>[49]</sup> technique and the measured resection technique <sup>[48]</sup>. The first uses the tensioning of the collateral ligaments in 90° of flexion to rotate the femur in the proper position. The latter uses bony landmarks (3° to 5° of the posterior condyles line) to get the proper femoral position (Fig. 9 a-b).

Figure 10: (a-b): Optimal rotational positioning of femoral implant

----- Proximal tibial cut  
- - - - - Posterior femoral cut

a. Posterior cut using a tensioning device  
b. Posterior cut about 3° to the posterior condyle line

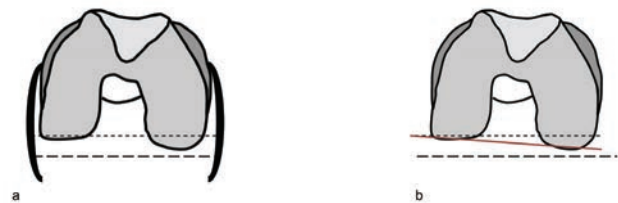
On the tibial side, internal rotation of the component must be avoided and its center has to point to the medial third of the anterior tibial tubercle. If resurfacing the patella, the patellar dome shall be centred or even better, slightly medial. If necessary, a release of the femoropatellar lateral retinaculum is done from the articular side. Also, a sagittal lateral patellectomy (<10mm) may be performed to avoid a lateral patella femoral conflict.

3.7 Implant fixation

Cemented fixation of TKA (Figure 10) is a standard procedure that is reliable and durable with good long term results. It is also less technically challenging because the bone cuts do not need to fit perfectly to the prosthesis and the cement may fill the defects up to 1cm. An enhancement of the surgical techniques as well as more precise instrumentation has brought cementless implants back to light. Excellent results have been reported in different studies describing equal survivorship and outcomes in bilateral TKAs, one cemented, one non-cemented <sup>[52,53]</sup>.

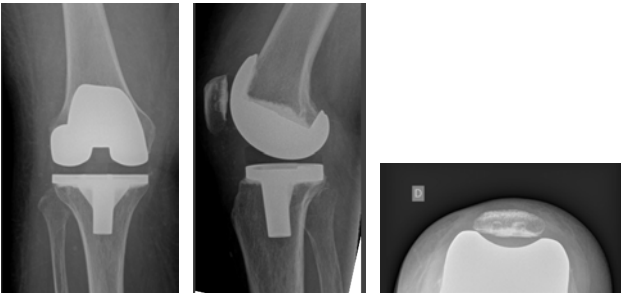
Figure 11: Total knee arthroplasty

4. Conclusion



The choice of a surgical option and the patient selection are the most challenging issues in the treatment of the knee osteoarthritis. It is the surgeon's duty to correctly analyse the stage of osteoarthritis, the ligamentary condition, the type of deformity and reducibility, the age, the range of motion and the expectations of the patient before proposing a surgery. There is a place for osteotomies around the knee, not only for monocompartmental osteoarthritis but also to address specific knee instability or to protect an ACL reconstruction in younger patients. Unicondylar knee arthroplasties give also good results but are to be considered as resurfacing surgery and need an optimal comprehension of the lower limb deformity and clinical status. Total knee arthroplasty remains the gold standard for the definitive treatment of knee osteoarthritis. Table 5 lists the ideal patient for each type of surgery.

Table 5. Indications		
OSTEOTOMIES	UKA	TKA
45 to 70 years (biological age)	Older than 55 years	Older than 70 years
May have extraarticular deformity	Must have correctable deformity	May have fixed axis deviation
Monocompartmental osteoarthritis	Monocompartmental osteoarthritis	Generalised osteoarthritis



May have extension deficit	Complete range of motion	May have flexion or extension deficit
No inflammatory disease	No inflammatory disease	May have inflammatory disease
May have ACL / PCL deficiency	Must have intact ACL/PCL	May have ACL / PCL deficiency

Table 5 Indications:

1. Hochberg MC, Altmann RD, April KT, et al: American College of Rheumatology 2012 recommendations for the use of nonpharmacologic and pharmacologic therapies in the osteoarthritis of the hand, hip, and knee. *Arthritis Care Res (Hoboken)* 2012;64(4):465-74.

2. Wilson B, Rankin HBarnes CL: Long-term results of an unloader brace in patients with unicompartmental knee osteoarthritis. *Orthopedics* 2011;34(8):e334-e337.

3. Moseley JB, O'Malley K, Petersen NJ, et al: A controlled trial of arthroscopic surgery for osteoarthritis of the knee. *N Engl J Med* 2002;347(2):81-88.

4. Katz JN, Brophy RH, Chaisson CE, et al: Surgery versus physical therapy for a meniscal tear and osteoarthritis. *N Engl J Med* 2013;368(18):1675-84.

5. Trousdale RT. Osteotomy. Patient selection, preoperative planning and results. In: Callaghan JJ, Rosenberg AG, Rubash HE, eds. *The Adult Knee*. Philadelphia, A: Lippincott Williams and Wilkins; 2002.

6. Paley D, Pfeil J: Principles of deformity corrections around the knee. *Orthopäde* 2000;29(1):18-38.

7. Coventry MB: Osteotomy of the upper portion of the tibia for degenerative arthritis of the knee. A preliminary report. *J Bone Joint Surg* 1965;47:984-90.

8. Coventry MB: Upper tibial osteotomy. *Clin orthop Relat Res* 1983;182:46-52.

9. Tunggal JA, Higgins GA, Waddell JP. Complications of closing wedge high tibial osteotomy. *Int Orthop*. 2010;34(2):255-61.
10. Lobenhoffer P, Agneskirchner JD. Improvements in surgical technique of valgus high tibial osteotomy. *Knee Surg Sports Traumatol Arthrosc*. 2003;11(3):132-38.
11. Staubli AE, De Simoni C, Babst R et al. TomoFix: a new LCP-concept for open wedge osteotomy of the medial proximal tibia—early results in 92 cases. *Injury* 2003;34( 2):55-62.
12. Bonnin M, Chambat P. Current status of valgus angle, tibial head closing wedge osteotomy in medial gonarthrosis. *Orthopäde* 2004;33(2):135-42.
13. Kellgren JH, Lawrence JS. Radiological assessment of osteoarthritis. *Ann Rheum Dis* 1957;16(4):494-502.
14. Lobenhoffer P. Indications for high tibial osteotomy, unicompartmental knee arthroplasty, and total knee prosthesis. In: Lobenhoffer P, van Heerwaarden J, Staubli A, eds. *Osteotomies Around the Knee. Indications-Planning-Surgical Techniques using Plate Fixators*. US-New York, NY: Thieme New York; 2008.
15. Paley D, Herzenberg JE, Tetsworth K, et al. Deformity planning for frontal and sagittal plane corrective osteotomies. *Orthop Clin North Am* 1994;25(3):425-65.
16. Paley D, Tetsworth K. Mechanical deviation of the lower limbs. Preoperative planning of multiapical frontal plane angular and bowing deformities of the femur and tibia. *Clin Orthop Relat Res* 1992;280:65-71.
17. Pape D, Seil R, Adam F, et al. Imaging and preoperative planning of osteotomy of tibial head osteotomy. *Orthopäde* 2004;33(2):122-34.
18. Miniaci A, Ballmer FT, Ballmer PM, et al. Proximal tibial osteotomy. A new fixation device. *Clin Orthop Relat Res* 1989;246:250-59.
19. Fujisawa Y, Masuhara K, Shiomi S. The effect of high tibial osteotomy on osteoarthritis of the knee. An arthroscopic study of 54 knee joints. *Orthop Clin North Am* 1979;10(3):585-608.
20. Noyes FR, Barber-Westin SD, Hewett TE. High tibial osteotomy and ligament reconstruction for varus angulated anterior cruciate ligament-deficient knees. *Am J Sports Med* 2000;28(3):282-96.
21. Reichwein F, Nebelung W. High tibial flexion osteotomy for revision of posterior cruciate ligament instability. *Unfallchirurg* 2007;110(7):597-602.
22. Marti CB, Gautier E, Wachtel AW, et al. Accuracy of frontal and sagittal plane correction in open-wedge high tibial osteotomy. *Arthroscopy* 2004;20(4):366-72.
23. Giffin JR, Vogrin TM, Zantop T, et al. Effects of increasing tibial slope on the biomechanics of the knee. *Am J Sport Med* 2004;32(2):376-83.
24. van Heerwaarden RJ, van der Haven, Kooijman M, et al. Derotation osteotomy for correction of congenital rotational lower limb deformities in adolescents and adults. *Surg Tech Orthop Traumatol* 2003;55-575-A-10:10.
25. Johnson F, Leitl S, Waugh W. The distribution of load across the knee. A comparison of static and dynamic measurements. *J Bone Joint Surg Br* 1980;62(3):346-49.
26. Jacobi M, Wahl P, Jakob RP. Basic principles of osteotomies around the knee. In: Lobenhoffer P, van Heerwaarden J, Staubli A, eds. *Osteotomies Around the Knee. Indications-Planning-Surgical Techniques using Plate Fixators*. US-New York, NY: Thieme New York;
27. Stuart MJ. Tibial antiviral closing wedge osteotomy. *Oper Tech Sport Med* 2000;8(1):27-31.
28. Pennington DW, wienckowski JJ, Lutes WB, et al. Unicompartmental knee arthroplasty in patients sixty years of age or younger. *J Bone Joint Surg Am* 2003;85:1968-73.
29. Parratte S, Argenson JN, Pearce O, et al. Medial unicompartmental knee replacement in the under-50s. *J Bone Joint Surg Br* 2009;91:351-56.
30. Hernborg JS, Nilsson BE. The natural course of untreated osteoarthritis of the knee. *Clin Orthop Relat Res* 1977;123:130-137.
31. Noticewala MS, Geller JA, Lee JH, et al. Unicompartmental knee arthroplasty relieves pain and improves function more than total knee arthroplasty. *J Arthroplasty* 2012;27(8, suppl):99-105.
32. Heyse TJ, Khefacha A, Peersman G, et al. Survivorship of UKA in the middle-aged. *Knee* 2012;19(5):585-91.
33. Fulkerson JP: Alternatives to patellofemoral arthroplasty. *Clin Orthop Relat Res* 2005;436:76-80.
34. van Jonbergen HP, Werkman DM, Barnaart LF et al. Long-term outcomes of patellofemoral arthroplasty *J Arthroplasty* 2010;25(7):1066-71.
35. Pavone V, Boettner F, Fickert S, Sculo TP: Total condylar knee arthroplasty: Along term follow-up. *Clin Orthop Relat Res* 2001;388:18-25.
36. Rand JA, Ilstrup DM: survivorship analysis of total knee arthroplasty: cumulative rates of survival of 9200 total knee arthroplasties. *J Bone Joint Surg Am* 1991;73(3):397-409.
37. Schai PA, Thornhill TS, Scott RD: Total knee arthroplasty with the PFC system: Results at a minimum of ten years and survivorship analysis. *J Bone Joint Surg Br* 1998;80(5):850-58.
38. Ranawat CS, Flynn WF Jr, Sandler S, et al. Long-term results of the total condylar knee arthroplasty: A 15-years survivorship study. *Clin Orthop Relat Res* 1993;286:94-102.
39. Gioe TJ, Killeen KK, Grimm K, et al. Why are total replacement revised? Analysis of early revision in a community knee implant registry. *Clin Orthop Relat Res* 2004;428:100-06.
40. Sharkey PF, Hozack WJ, Rothman RH, et al. Why are total knee arthroplasties failing today? *Clin Orthop Relat Res* 2002;404:7-13.
41. Lidgren L, Robertsson O: Annual report 2008: The Swedish Knee Arthroplasty Register. Lund, Sweden, Wallin & Dalholm, 2008.
42. Lin WP, Lin J, Horng LC, et al. Quadriceps sparing, minimal-incision total knee arthroplasty: A comparative study. *J Arthroplasty* 2009;24(7):1024-32.
43. Matsumoto T, Muratsu H, Kubo S, et al. soft tissue balance measurement in minimal incision surgery compared to conventional total knee arthroplasty. *Knee Surg Sports Traumatol Arthrosc* 2011;19(6):880-86.
44. Fang DM, Ritter MA, Davis KE. Coronal alignment in total knee arthroplasty: just how important is it? *J Arthroplasty* 2009;24:39-43.
45. Jeffery RS, Morris RW, Denham RA. Coronal alignment after total knee replacement. *J Bone Joint Surg Br* 1991;73:709-14
46. Parratte S, Pagnano MW, Trousdale RT, et al. Effect of postoperative mechanical axis alignment on the fifteen-year survival of modern, cemented total knee replacements. *J Bone Joint Surg Am*. 2010;92:2143-49.
47. Verdonk PC, Pernin J, Pinaroli A, et al. Soft tissue balancing in varus total knee arthroplasty: an algorithmic approach. *Knee Surg Sports Traumatol Arthrosc* 2009;17:660-66.



48. Hungerford DS, Krackow KA. Total joint arthroplasty of the knee. *Clin Orthop Relat Res* 1985;192:23-33
49. Dennis DA, Komistek RD, Kim RH, et al. Gap balancing versus measured resection technique for total knee arthroplasty. *Clin Orthop Relat Res* 2010;468:102-07.
50. Berger RA, Rubash HE. Rotational instability and malrotation after total knee arthroplasty. *Orthop Clin North Am* 2001;32:639-47.
51. Rhoads DD, Noble PC, Reuben JD, et al. The effect of femoral component on the kinematics of total knee arthroplasty. *Clin Orthop Relat Res* 1993;286:122-29.
52. Park JW, kim YH. Simultaneous cemented and cementless total knee arthroplasty in the same patients: A prospective comparison of long-term outcomes using an identical design of kexGen prosthesis. *J Bone Joint Surg Br* 2011;93-B(11):1479-86.
53. Hofmann AA, Evanich JD, Ferguson RP, et al. Ten-to 14-years clinical followup of the cementless Natural Knee system. *Clin Orthop Relat Res* 2001;388:85-94.



*Dr. Nikolaos Gougoulas, MD, PhD, EFAS certification*

Consultant Orthopaedic Surgeon  
General Hospital of Katerini, Greece

gougnik@yahoo.com Tel: +306978587347  
General Hospital of Katerini. 60100 Katerini. Greece

## **Ankle Osteoarthrosis, Adult Acquired Flatfoot Deformity & Hallux Valgus**

### **Abstract**

Ankle osteoarthrosis is usually post-traumatic, associated with chronic ligamentous instability and malleolar or tibial plafond fractures. Surgical management options include realignment osteotomies, distraction arthroplasty, total ankle arthroplasty and ankle arthrodesis (open or arthroscopic).

Flatfoot deformity is the result of loss of structural integrity of the medial column (arch) of the foot. Tibialis posterior tendon dysfunction is usually the result rather than the cause of the deformity. Progressive deformities are associated with midfoot arthrosis, and/or ligamentous injuries or laxity and can be flexible or rigid. Flexible deformities require joint preserving procedures (osteotomies, soft-tissue reconstructions), whilst stiff deformities may require arthrodesis.

Hallux valgus is probably the most common foot deformity, affecting mostly female patients. Hereditary predisposition has been established. Rotational (pronation) first metatarsal deformity, possibly as a result of medial midfoot joints laxity, is currently recognized as a key feature. Corrective surgery is indicated when it becomes symptomatic, and not for cosmetic reasons. Corrective osteotomies using stable internal fixation offer good outcomes. Contemporary minimally invasive techniques using special instrumentation and internal fixation, with appropriate surgeons' training, offer good results. Recurrence is common in the long term, but revision surgery is not required often. In severe deformities or when arthritis is present, arthrodesis (at the first tarsometatarsal or the first metatarsophalangeal joints) may be required.

## **1. Ankle Osteoarthrosis**

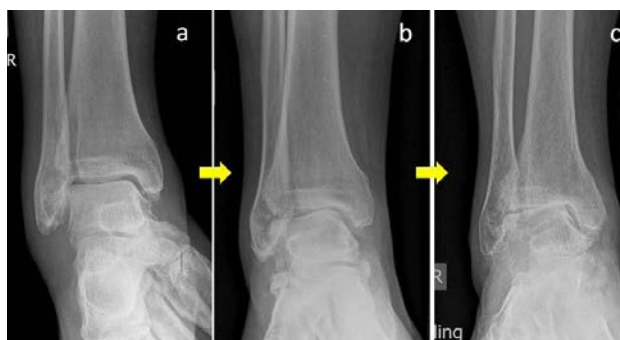### **1.1 Etiology and Epidemiology**

Ankle osteoarthrosis affects 1% of the world's population, is usually post-traumatic (75%), unlike hip and knee arthrosis. It is associated with either chronic ligamentous instability or previous rotational malleolar and/or tibial plafond fractures. Other, less common causes of ankle arthrosis are autoimmune disease, developmental dysplasia, metabolic disorders, neuropathy, avascular necrosis, haematological conditions, infection and several hereditary conditions like Ehlers-Danlos syndrome, Paget's disease. Patients with advanced ankle arthritis are usually younger compared with those with hip or knee arthritis.

### **1.2 Pathogenesis**

Some fundamental differences between ankle and knee cartilage have been identified, that may be responsible for the different patterns of arthrosis development. Ankle cartilage has higher water content and is less sensitive to mechanical loading. At the same time, the ankle is a congruent joint and this allows distribution of the pressure over a larger area.

Primary arthrosis is therefore rare in the ankle. On the other hand, it has been shown that 1mm of talar shift (e.g. as a result of ligamentous instability, or ankle fracture malunion) can decrease the tibiotalar contact area by approximately 40%. This means that the reduced contact area of the potentially injured articular cartilage, will receive increased load and this may lead to osteoarthrosis in the longer term (Figure 1). Several studies revealed a latency period of 20-35 years between the original injury and the development of advanced arthrosis of the tibiotalar joint.



*Figure 1: The above radiographs represent the natural history of ankle ligamentous injuries (a), causing chronic lateral instability and varus deformity (b), and over the years osteoarthrosis (c).*

### **1.3 Clinical presentation and diagnosis**

Patients with ankle osteoarthrosis present with "deep" pain and may also have hindfoot deformity (usually varus). Pain can be activity related, but can also be present at rest. Range of motion, especially dorsiflexion, can be reduced. Patients adopt an antalgic gait, and their mental and physical disability scores have been shown to be similar to those patients with advanced hip arthrosis and chronic disease.

Clinical examination should include assessment of alignment, stability and function of the ankle and the adjacent joints. The physician should try to identify whether the tibiotalar joint is the only source of pain, or whether it arises also from other foot joints and/or tendons. Neurovascular assessment of the leg is essential.

1.4 Imaging

Weight bearing radiographs are essential for the diagnosis of ankle osteoarthritis, whilst special views (e.g. Mortise view, Saltzman hindfoot view, oblique views) can be required for the initial assessment (Figure 2). More advanced imaging (e.g. MRI, CT, or SPECT/CT scanning) (Figure 3) may be required to more accurately assess the extent of cartilage degeneration in the ankle and the adjacent (subtalar, talonavicular, midfoot) joints, the condition of tendons and ligaments, or to reveal avascular necrosis of the talus. Weight bearing CT scan is a new advanced imaging modality offering information regarding alignment and joint degeneration.

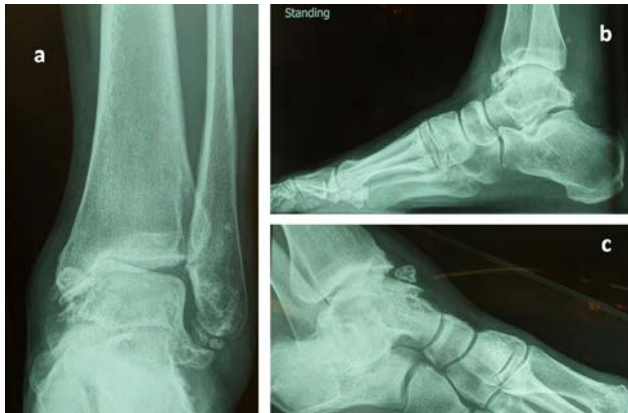

Figure 2: Anteroposterior (a), lateral (b) weight bearing, and medial oblique (c) radiographs are diagnostic of ankle osteoarthritis.

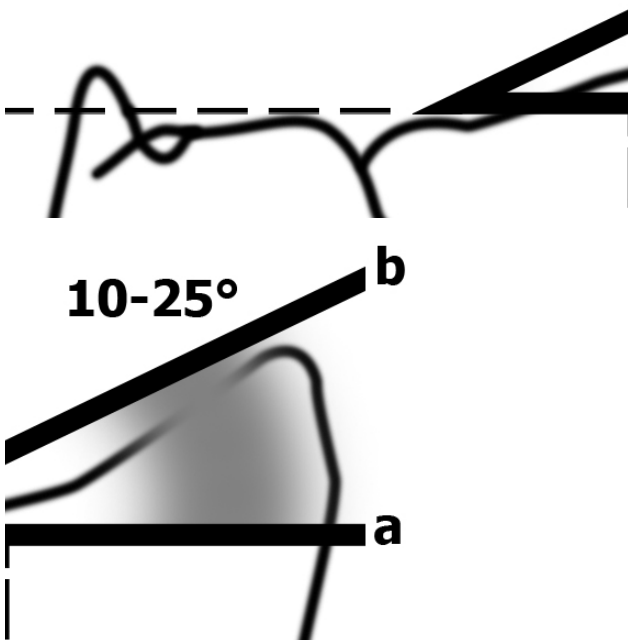


Figure 3: The “hot spots” (high uptake; white arrows) in this CT co-registered bone scan (SPECT-CT), reveal areas of acute inflammation, and are diagnostic of medial ankle arthrosis, whilst the subtalar is normal. This can aid the treatment decision making process and preoperative planning.

1.5 Classification

Several classification systems for ankle osteoarthritis have been proposed, based on the degree of cartilage damage, presence of osteophytes, loss of joint space, malalignment and degeneration of neighboring joints.

The “classic” Kellgren and Lawrence classification (stages I-IV) was initially developed for knee arthritis and later also used in the ankle and describes different degrees of joint space narrowing and osteophytes formation on radiographs.

More detailed is the Takakura classification, mainly because it describes separately the medial tibio-talar space radiographic appearance (Table 1).

Table 1. Takakura-Tanaka classification for ankle arthritis	
Stage	
I	Early sclerosis, osteophyte formation, no joint space narrowing
II	Narrowing of medial joint space (no bone contact)
IIIa	Obliteration of joint space at medial malleolus, with bone contact
IIIb	Obliteration of joint space over talar dome, with bone contact
IV	Obliteration of joint space with complete bone contact

The Canadian Orthopaedic Foot & Ankle Society (COFAS) classification system, proposed in 2010, is based on a different rationale, as it takes into consideration other pathologies is the foot (deformity, adjacent joints arthritis, Achilles tendon tightness) (Table 2).

Table 2. Canadian Orthopaedic Foot & Ankle Society (COFAS) classification system for ankle arthritis	
Type	
1	Isolated ankle arthritis
2	Ankle arthritis & intra-articular varus or valgus deformity and/or tight heel cord
3	Ankle arthritis & hindfoot or midfoot deformity, tibial malunion, plantarflexed first ray, or other deformity
4	Types 1-3 plus subtalar, talonavicular, or calcaneocuboid joint arthritis

1.6 Treatment

Management of patient’s expectations is mandatory, given there is no “cure” for ankle osteoarthritis. The focus should be on managing the symptoms.

**Initial management is nonoperative** and includes modification of activities and shoes (eg using rocker sole shoes), use of corrective insoles for flexible deformities, or braces to stabilize the ankle. Analgesic and anti-inflammatory medications, weight loss, intra-articular injections (steroid, hyaluronic acid), all aid in the management of symptoms. Steroid injections can predictably offer short to medium term pain relief, with a risk of soft tissue damage (catabolic effect) and infection, and can become gradually ineffective after repeated treatments. Currently there is evidence regarding pain reduction after hyaluronic acid injections for 6 months, but no evidence regarding the use of PRP or stem cells.

Operative management of ankle osteoarthritis includes arthroscopic debridement, realignment osteotomies, distraction arthroplasty, allograft arthroplasty, total ankle replacement and ankle arthrosis.

Operative management of ankle osteoarthritis includes arthroscopic debridement, realignment osteotomies, distraction arthroplasty, allograft arthroplasty, total ankle replacement and ankle arthrodesis.

**Arthroscopic debridement** is a procedure of limited value

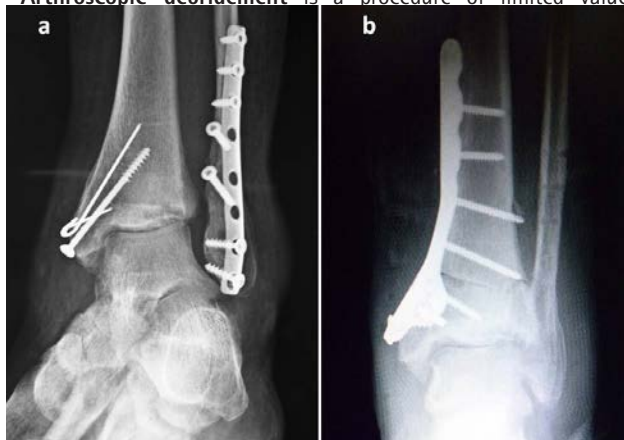

Figure 4: Malunion of a trimalleolar fracture (a) and ankle instability resulted in lateral ankle osteoarthritis and valgus hindfoot alignment in a 46-year-old female patient. Medial closing wedge distal tibia osteotomy (b), performed simultaneously with ankle arthroscopic debridement, resulted in re-alignment of the hindfoot to neutral and improvement in patient's symptoms.

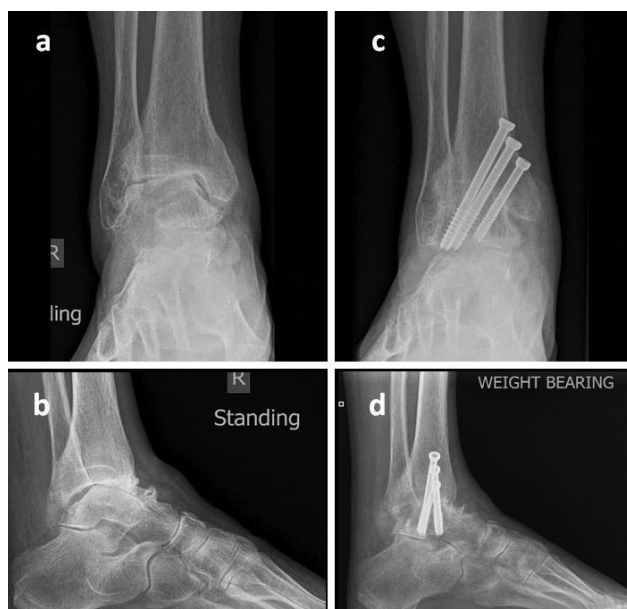

Figure 5: Pre- (a,b) and postoperative (c,d) radiographs of ankle arthrodesis performed arthroscopically.

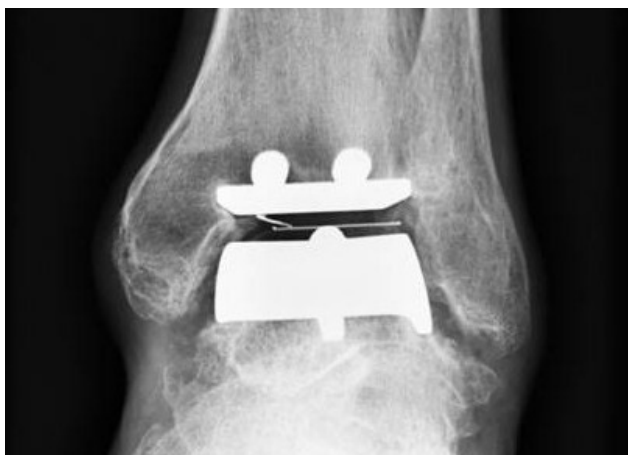

Figure 6: Anteroposterior radiograph of total ankle arthroplasty, using a three-component, mobile bearing design.

in arthritic joints of the lower extremities. It may have a role in moderate ankle osteoarthritis, or in patients with well defined anterior tenderness and soft tissue or bony impingement, or those with loose bodies causing discomfort. Careful patients' counseling is required to inform them about the risk the pain becoming worse, and the joint more unstable after arthroscopy and debridement of their arthritic ankle. It may be used as an adjunct to other procedures (eg. realignment osteotomies).

**Realignment osteotomies** (supramalleolar, intra-articular, fibular, calcaneal, or a combination of those) are indicated in the presence of deformity, or intra-articular malalignment associated with partial cartilage loss of the tibiotalar joint (Figure 4). These procedures need to be accompanied by ligament repairs or reconstructions, and/or total ankle replacement simultaneously, or at a later stage. Extensive surgical experience and deep knowledge of the principles of foot and ankle deformity correction is required. Careful preoperative planning and appropriate patients' selection and counseling, are essential. Supramalleolar osteotomies are indicated in younger patients with asymmetric arthritis, offering clinical improvement, while complications are not common. The rate of conversion to ankle arthrodesis or arthroplasty is approx. 12% at 5 years.

**Distraction arthroplasty** (that can be combined with deformity correction), using circular external fixation, has been shown, according to some studies, to delay the need for arthrodesis or ankle replacement. Risk associated with pin tract infections has to be highlighted. Complications have been reported in 20% of surgeries. "Survivorship" of the native joint has been reported at 55% at 5 years, whilst combination with osteotomy has been successful in 84% at 5 years, according to another study.

**Allograft arthroplasties** have been associated with very high (up to 60%) complication rates and should be considered as experimental procedure. It should be performed only in specialized centers, with strict protocols and documentation of outcomes.

**Ankle arthrodesis (AA)** (Figure 5) has been the "gold standard" treatment for advanced ankle osteoarthritis for many decades. Open techniques offered success rates of approximately 80-85%, whereas the arthroscopic technique allowed higher fusion rates (above 90% according to various studies), with shorter times to fusion, and lower morbidity. Optimal positioning of the fused ankle (neutral in the sagittal plane, 5° hindfoot valgus in the coronal plane, mild external rotation of the foot) is mandatory for a good functional outcome. The general rule is that the talus should be placed under the tibia in all planes. Postoperative immobilization in a cast or walking boot for 3 months is required. Patients lose any residual range of motion at the tibiotalar joint, and this may aggravate pre-existing arthritic changes in the neighboring joints in the longer term.

**Total ankle replacement (TAR)** (Figure 6) is performed since 1973, and implant designs are still evolving. Over the years several implants have been used and were subsequently withdrawn. It has been gaining in popularity in the past two decades, with its success remaining well below that for hip and knee replacement. Implant survivorship rates between 70-90% at 10 years have been reported. In recent years, several new implants have been introduced, some of them offering fixed and mobile bearing options. Studies have shown comparable patient satisfaction rates and function scores, compared to ankle arthrodesis in the short to medium term. However, one has to highlight that outcomes are better if the procedures are performed in "high volume" referral centers. TAR be performed in deformed



ankles, provided that supplementary procedures (e.g. osteotomies, subtalar arthrodesis, soft-tissue reconstructions) to realign the hindfoot to neutral have been performed. Osteolysis is very frequent around total ankle replacements, and remains an unsolved issue. Active infection and Charcot neuroarthropathy are contraindications for TAR, whilst neuromuscular disorders and talus avascular necrosis are considered relative contra-indications. Failure of total ankle prosthesis may require revision of the components, or complex arthrodesis taking into consideration the bone loss associated with osteolysis and implant removal. The thin soft-tissue envelope makes these procedures prone to wound healing problems, and amputation may be the end result in 1% of total ankle replacements.

**AA vs. TAR.** Current evidence suggests that both procedures improve functional outcomes, but can also be associated with complications and have advantages and disadvantages. Thus, it is important to choose the procedure that is more suitable for the individual patient, based on her/his needs and expectations. Preoperative patients' counselling and selection is, therefore, mandatory.

## 2. Adult Acquired Planovalgus Deformity

### 2.1 Definition

Historically the progressive flatfoot appearance (Figure 7) in adults has been attributed to tibialis posterior tendon dysfunction. However, the terminology has changed. It is currently accepted that adult acquired planovalgus (flatfoot) deformity includes a wide range of structural abnormalities affecting soft-tissue and bone, in the hindfoot and midfoot, and that tibialis posterior tendon insufficiency is usually the result, rather than the cause of the deformity. Recently (2020), leading experts have proposed a new classification system of the condition, which was defined as "Progressive Collapsing Foot Deformity".

### 2.2 Etiology – Pathomechanics

Collapse of the medial longitudinal arch of the foot that results in pes planus deformity is caused by loss of the integrity of, either the soft-tissue structures, or the bones, in the medial column of the foot. Soft-tissue structures contributing to the stability of the medial foot arch (Figure 8) include tibialis posterior tendon, calcaneonavicular ligament –the so called "spring ligament", the deltoid ligament and other interosseus midfoot ligaments. One must also take into consideration the "windlass mechanism" generated by the function of the gastroc-soleus complex, through the Achilles tendon, the calcaneum, and the plantar fascia that results in stability of the bones of the medial foot arch, which in terms of engineering resembles the structural integrity of the "Roman arch". Trauma or gradual degeneration of the soft-tissues (e.g. spring ligament, Lisfranc's ligament, tibialis posterior tendon) can lead to weak support of the bones and gradual deformation of the foot. In a different scenario, degeneration of the midfoot (tarsometatarsal and/or naviculocuneiform) joints, results in loss of cartilage and bone, so the ligamentous structures become loose, and the midfoot collapses. Similarly tarsal coalition (congenital condition that can become symptomatic in teenagers but also in adult life) causes abnormal mechanics not allowing normal inversion of the subtalar

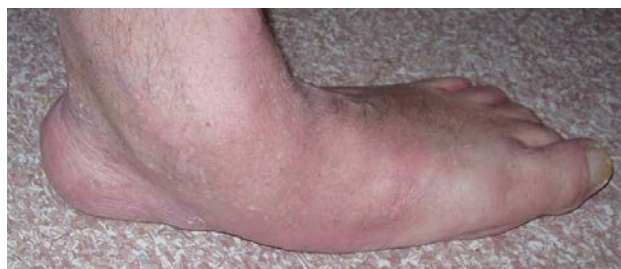

Figure 7: Adult acquired flatfoot deformity: Loss of height of the medial arch, and hyperpronation of the foot.

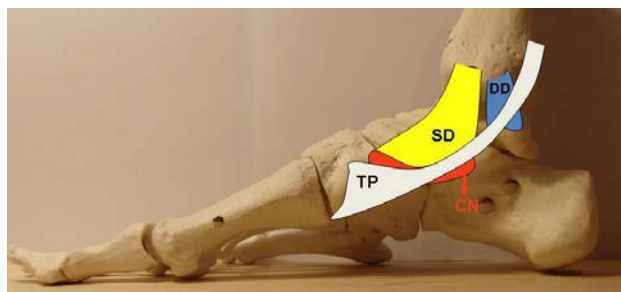


Figure 8 : Medial hindfoot stabilizing structures include tibialis posterior tendon (TP, white), calcaneonavicular ligament (CN, red), superficial (SD, yellow) and deep (DD, blue) deltoid ligament. TP is a dynamic stabilizer of the medial foot arch, but also initiates heel raising by inserting/supinating the subtalar joint. The calcaneonavicular ("spring") ligament connect the sustentaculum tali with the naviculum, "suspending" the talar head. One has to note that SD has a broad attachment to the sustentaculum tali, the spring ligament and the naviculum, so is not directly attached to the talus, and is tight when the foot is in plantar flexion, whilst DD is relatively short and attaches to the talar body and is tight in the plantigrade (neutral) foot position.

joint. The windlass mechanism becomes dysfunctional. The medial arch, tibialis posterior tendon and the spring ligament are overloaded, and become weak, and thus peroneal muscle's function remains unopposed, causing excessive eversion. Progressive foot arch collapse worsens and arthritic changes in the hindfoot and midfoot joints can develop. Thus, although in the past it was felt that tibialis posterior tendon dysfunction is the only primary cause of planovalgus foot deformities, it has been realized, that it is unclear which anatomic structure becomes dysfunctional first. It is likely that we are dealing with a complex sequence of pathomechanical episodes and a vicious cycle of events that lead to soft tissue and/or bone degeneration and, therefore, medial arch collapse and progressive foot deformity.

### 2.3 Classification

Classifications to describe flatfoot deformities have been changing over the years, as our understanding of its pathomechanics of the deformities is evolving. Initially, pathogenesis was attributed to a linear progression of events starting with tibialis posterior tendon tendinopathy and dysfunction, leading to a loss of the median arch of the foot, progressing from flexible to rigid deformities. The ankle joint was supposed to only be involved in the most advanced stage.

Thus, Johnson and Storm classification in 1989 recognized three stages. In stage I, there is mild pain, no deformity, mild weakness on heel-raise test, the tendon is almost normal and there is no arthritis. In stage II, the pain and weakness get worse, planovalgus deformity appears, but is passively correctable (flexible foot), and the tendon is elongated with "longitudinal tears". In stage III symptoms become worse, with marked weakness and tendon degeneration, whilst the deformity is stiff with arthritic changes on radiographs.

Myerson was credited in 1997 with the formal publication of stage

Table 3. Myerson's AAFD classification (2007)			
Stage I	Clinical findings	Imaging	Treatment
A	TP tenderness, normal anatomy	Normal	Immobilisation, orthotics, NSAID's, tenosynovectomy
B	TP tenderness, normal anatomy	Normal	
C	Slight hindfoot valgus, normal anatomy	Slight hindfoot valgus	
Stage II			
A1	Supple hindfoot valgus, flexible forefoot varus	Hindfoot valgus Meary's line disrupted Loss of calcaneal pitch	Orthosis, medial displacement calcaneal osteotomy, Achilles tendon or gastrocnemius lengthening and flexor digitorum longus transfer if deformity corrects only with ankle plantar flexion plantar flexion
A2	Supple hindfoot valgus, fixed forefoot varus		Orthosis, medial displacement calcaneal osteotomy, flexor digitorum longus transfer, cotton osteotomy
B	A2 + forefoot abduction	Talonavicular joint uncovered, forefoot abduction	Orthosis, medial displacement calcaneal osteotomy, flexor digitorum longus transfer, lateral column lengthening
C	B + medial column instability, first ray dorsiflexion with hindfoot correction, sinus tarsi pain	First tarsometatarsal plantar gapping	Medial displacement calcaneal osteotomy, flexor digitorum longus transfer, cotton osteotomy or medial column fusion
Stage III			
A	Rigid hindfoot valgus, lateral hindfoot pain (sinus tarsi)	Subtalar joint space loss, angle of Gissane sclerosis, hindfoot valgus	Triple arthrodesis or custom bracing if not surgical candidate
B	A + forefoot abduction	A+ forefoot abduction	A+ lateral column lengthening
Stage IV			
A	Supple ankle valgus	Ankle valgus	Surgery aiming at plantigrade foot+ deltoid reconstruction
B	Rigid ankle valgus		Tibiototalcalcaneal arthrodesis

(AAFD: Adult acquired flatfoot deformity)

IV, describing valgus alignment and arthritis at the ankle. Later (2007) Myerson's team revisited the problem to propose a more comprehensive, but relatively complicated classification system (Table 3). Stage IV was subdivided in subtle versus rigid ankle valgus, with the authors proposing as treatment options, deltoid ligament reconstruction versus tibiototalcalcaneal fusion, respectively. Parsons (2010) subdivided stage II, based on the degree of forefoot residual supination, when the hindfoot is brought to neutral. Raikin (2012) proposed a classification system that takes into consideration the degree of talonavicular joint incongruity, but also the changes in the midfoot and the ankle.

In 2020 Myerson, with the collaboration of a group of experts foot and ankle orthopaedic surgeons, proposed a new classification system and suggested for the condition to be renamed, as "Progressive Collapsing Foot Deformity, PCFD". According to this complex

classification system, consisting of more than 250 subtypes, changes occurring in the foot are not linear. Multiple foot structures might be affected at the same time, resulting in a variety of pathologies and a complex 3-dimensional foot deformity. They made a distinction between flexible and rigid foot, whilst in each category deformities of different parts of the foot can occur in isolation or combined (Table 4).

## 2.4 Clinical presentation and Diagnosis

Patients present with medial hindfoot / midfoot pain and in more advanced stages with lateral hindfoot pain, as well. Also depending on the stage, there are variable degrees of foot planovalgus deformity. The so called "too many toes sign" is characteristic for the condition (Figure 9). In severe deformities, the gait becomes imbalanced, as the windlass mechanism is dysfunctional, the

Table 4. Myerson et al. (2020) classification system of "progressive collapsing foot deformity" Stage I (flexible)		
Stage I (flexible)		Stage II (rigid)
Type of deformity (classes – isolated or combined)	Deformity type / location	Consistent clinical / radiographic findings foot and ankle offset
Class A	Hindfoot valgus	Increased hindfoot moment arm, hindfoot alignment angle, foot and ankle offset
Class B	Midfoot/forefoot abduction	Decreased talar head coverage Increased talonavicular coverage angle
Class C	Forefoot varus / medial column instability	Sinus tarsi impingement Increased talus-1st metatarsal angle
Class D	Peritalar subluxation / dislocation	Plantar gapping 1st TMTJ/NCJ Clinical forefoot varus Sinifficant subtalar joint subluxation/subfibular impingement
Class E	Ankle instability	Valgus tilting at the ankle joint

foot does not supinate in the midstance phase, and the heel does not invert during single heel-raise (stiff deformity) (Figure 10). Pain and tenderness on the medial side can be associated with the tibialis posterior tendon and/or the joints (talonavicular, naviculocuneiform, tarsometatarsal). Lateral hindfoot pain can be associated with subtalar +/- calcaneocuboid +/- ankle joint arthritis, and/or calcaneo-fibular impingement due to gross valgus deformity. The Silverskioldt test can reveal gastrocnemius or gastroc-soleus tightness, whilst neurovascular assessment is an essential part of the examination.

## 2.5 Imaging

Imaging is essential for the initial assessment and includes a series of weight bearing radiographs of the foot and ankle (Figure 11). MR scan is usually required to reveal information regarding the condition of tendons, ligaments, and joints degeneration. SPECT-CT scan can also be useful in diagnosing symptomatic arthritic joints (high uptake on the scan). Ultrasound scanning is helpful in assessing tibialis posterior tendinopathy. Weight bearing CT scan is a new advanced imaging modality offering information regarding ankle and foot alignment and joints' degeneration.

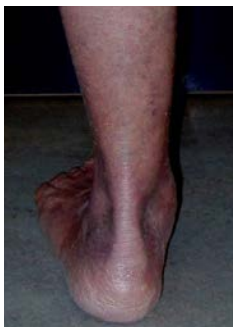

Figure 9: Observation of the patient's foot from the back, allows the examiner to see "too many toes". This should not be possible in a neutrally aligned foot.

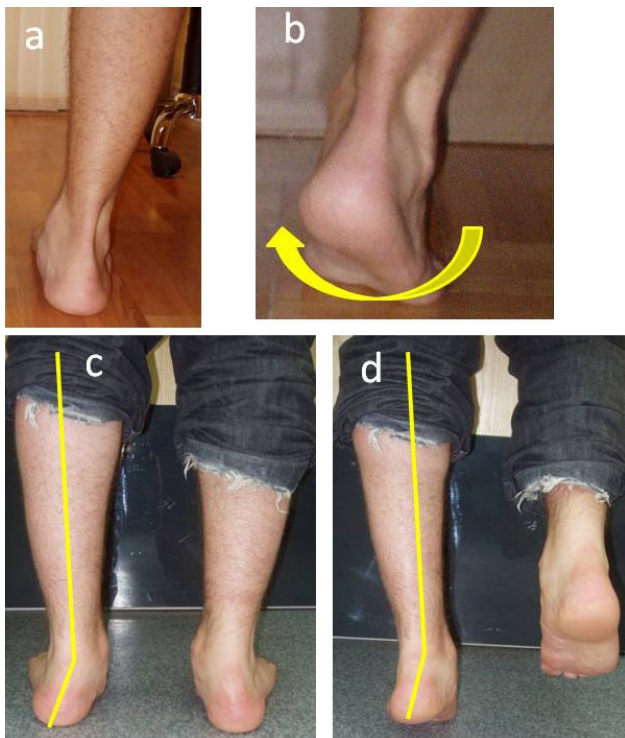

Figure 10: The mild flatfoot deformity in figure 9a, is dynamically corrected (normal heel inversion into varus) (b) when the patient goes on tiptoes on one foot (single heel raise). This indicates flexible deformity. A more severe deformity (c) does not fully correct with the single heel raise test (d).

## 2.6 Treatment

Irrespective of the stage of presentation, nonoperative management for 6 months is indicated. Flexible feet respond better to nonoperative management. Surgery can be considered after nonoperative management has failed to control symptoms.

**Nonoperative** management includes:

- Modification of activities
- Weight loss
- Analgesic and anti-inflammatory medications
- Physiotherapy (to strengthen tibialis posterior tendon and

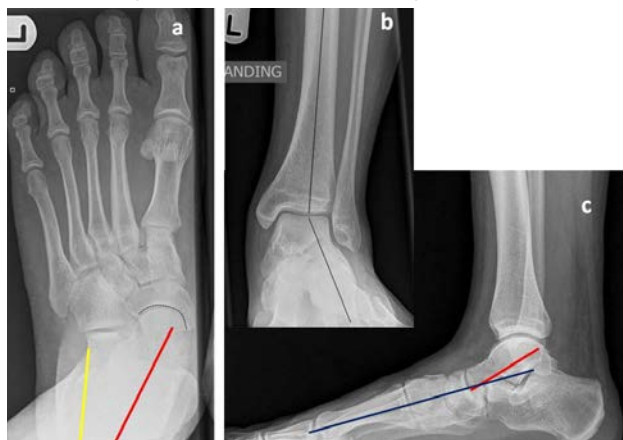


Figure 11: Weight bearing radiographs of a planovalgus foot. On the anteroposterior foot view (a) one can measure Kite's angle (normal if less than 25°), formed by the intersection of a line bisecting the head of the talus (red line), and a line that crosses parallel to the calcaneus (yellow line). In this occasion the talonavicular joint remains congruent. On the ankle anteroposterior view (b), one can assess the increased valgus of the heel in relation to the tibial axis (black lines). On the lateral foot view (c), the Meary's angle is measured, formed by axis of the talus (red line) and the first metatarsal (blue line). It should be zero (talus and first metatarsal axis parallel) in normal feet.

lengthen gastrocnemius muscle if tight)

- Orthotics: Corrective insoles (in flexible deformities) or accommodative and supportive (in stiff deformities) custom made orthoses/ braces. Typically, an insole with a corrective medial heel wedge and soft arch support is indicated for flexible deformities, whereas more rigid orthoses (e.g. University of California brace, Ankle Foot rigid Orthosis) can help patients with advanced fixed deformities.
- Injections: Guided intra-articular steroid injections, in arthritic joints, can offer short term pain relief. Steroid injections within the tibialis posterior tendon sheath can reduce tenosynovitis and offer pain relief in the initial stages but carry the risk of tendon rupture. PRP injections are currently used for tendinopathies, but their use remains controversial.

**Surgical** treatment includes joint preserving procedures or arthrodesis, depending on the degree and flexibility of the deformity, and the presence or not of arthritic changes.

In the absence of deformity, open or endoscopic debridement of tibialis posterior tenosynovitis, can be considered. In the presence of longitudinal tear of the tendon, open repair is an option.

In flexible deformities, a calcaneal medial displacement osteotomy (Figure 12) is indicated to restore the hindfoot's mechanical axis (Figure 13), off-load the painful medial structures, and improve the function of the Achilles tendon and the gastroc-soleus muscle complex. Exploration of tibialis posterior tendon will allow assessment of the degree of tendinopathy. In early stages,



# Reconstruction

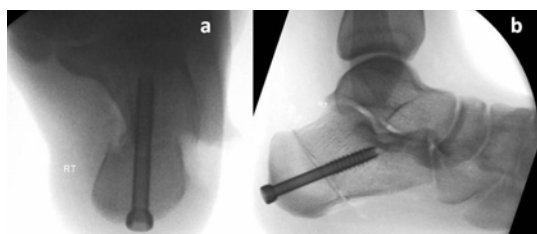


Figure 12: Axial (a) and lateral (b) calcaneus intraoperative image intensifier views, of a medial displacement (varization) calcaneal osteotomy.

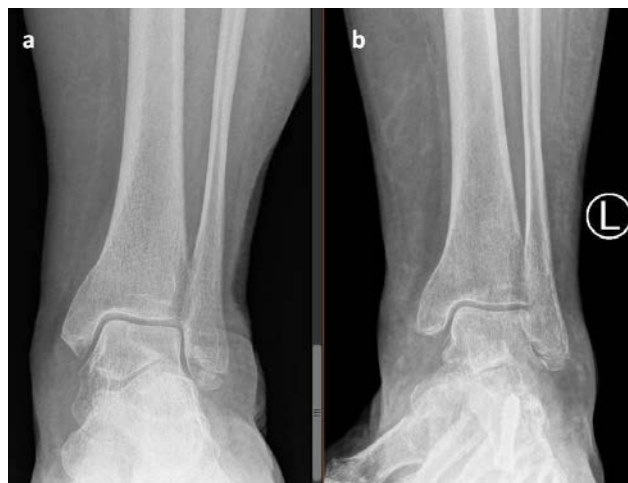

Figure 13: Hindfoot valgus alignment (a) was corrected to neutral (b), performing medial displacement calcaneal osteotomy.

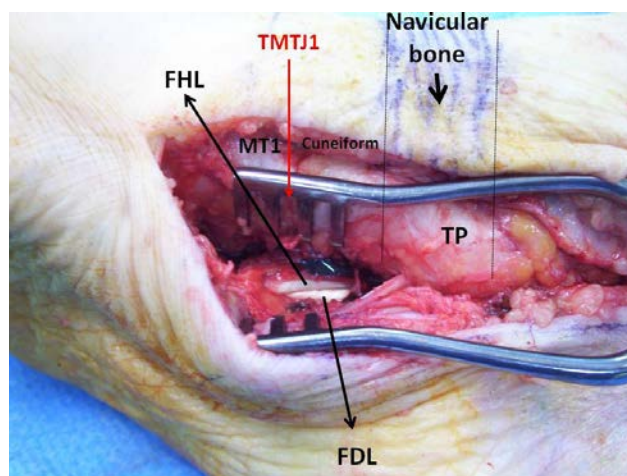


Figure 14: A medial midfoot approach allows exposure and debridement of tibialis posterior (TP) and access to the "knot of Henry", to identify flexor hallucis longus (FHL) and flexor digitorum longus (FDL) tendons. FDL is used to reconstruct the degenerate TP. (MT1: 1st metatarsal, TMTJ1: 1st tarsometatarsal joint).

debridement and repair can be performed, whereas in advanced stages, the tendon is sacrificed and reconstructed using a tendon transfer (usually flexor digitorus longus; FDL is the preferred option) (Figure 14).

In acute deformities, following a severe hyperpronation injury mechanism, one has to consider repair of the spring ligament +/- augmentation with orthobiologics, can be considered.

Some authors advocate the use of the arthroereisis screw, instead of a calcaneal osteotomy, to correct the hindfoot deformity, together with surgery to the tibialis posterior tendon. The indications for this procedure have not been fully defined, yet.

Depending on the degree of deformity and, in the presence of

forefoot adduction, lateral column lengthening (using a calcaneal lengthening osteotomy or calcaneocuboid bone block fusion), is an option. The disadvantage of this procedure is that, if not fused it can "overtighten" the lateral column and cause pain in lateral midfoot joints or the calcaneocuboid joint, if not fused.

If residual forefoot supination remains after hindfoot correction a medial cuneiform dorsal closing wedge (Cotton) osteotomy can be performed, to plantar-flex the first ray. Alternatively 1st tarsometatarsal, and/or naviculocuneiform joint arthrodesis is needed, if the medial column is unstable or arthritic.

Stiff deformities require arthrodesis. Triple arthrodesis (Figure 15) involves the talonavicular, subtalar and calcaneocuboid joints, although recently there is a trend for "double arthrodesis" (talonavicular and subtalar joints), avoiding fusion if the calcaneocuboid joint (Figure 16).

In severe deformities subtalar arthrodesis can be combined with calcaneal (medial displacement) osteotomy, to correct hindfoot valgus.

In cases with midfoot collapse (at the tarsometatarsal and/or naviculocuneiform joints), additional corrective medial column arthrodesis is needed (Figure 17).

In the presence of valgus ankle alignment, an attempt to preserve the joint, if flexible, can be undertaken (eg. deltoid ligament reconstruction +/- distal tibia-fibula, or calcaneal osteotomies). However, tibio-talo-calcaneal arthrodesis is the most reliable surgical treatment option, with predictable results in stage IV planovalgus deformities.

Gastrocnemius slide or Achilles tendon lengthening is sometimes required, for severe deformities.

In conclusion, flatfoot is a complex 3-dimensional foot deformity, where different pathologies co-exist. Experience, careful examination, preoperative planning and individualized ("a la carte") surgery, are required.

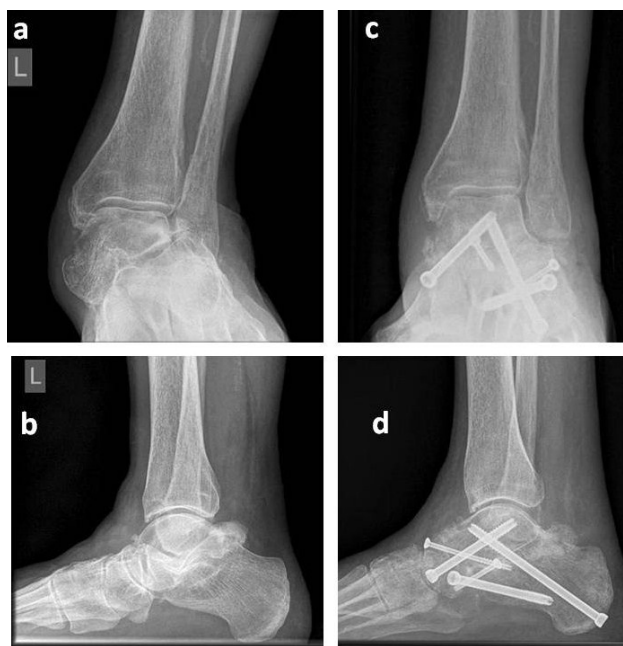

Figure 15: Triple hindfoot arthrodesis. Pre- (a,b) and postoperative (c,d) radiographs.



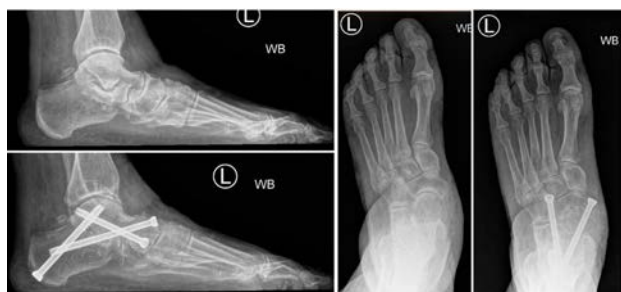

Figure 16: "Double" (subtalar and talonavicular joints) hindfoot arthrodesis.

## 3. Hallux Valgus

### 3.1 Etiology–Epidemiology

The etiology of this common condition defined as lateral deviation of the big toe at the 1st metatarsophalangeal joint, and usually affects women (90%), is unknown. Genetic predisposition is suspected as hallux valgus is common among family members, whilst some correlation with restrictive footwear and high heeled shoes has been established. Other factors contributing to development of hallux valgus are ligamentous laxity, hindfoot valgus and pes planus, first ray hypermobility, calf muscle tightness, have also been described. Hallux valgus is, often, associated with lesser toe deformities and metatarsalgia.

### 3.2 Pathomechanics

There are no tendon attachments to the first metatarsal head, thus making it prone to deviation from neutral axis, as a result of forces acting on the big toe during stance and gait. In the normal foot static stabilizers (ligaments and sesamoids apparatus) prevent deformation. However, deformity (eg pes planus) causes abnormal foot mechanics, driving the big toe into valgus, whilst the first metatarsal deviates into varus. Rotational 3-D first metatarsal deformity (torsion), possibly as a result of medial midfoot joints laxity, causes hyperpronation, and is currently recognized as a key feature in the pathogenesis of hallux valgus. The foot loses its normal function as a "tripod" (where forces would be distributed between the heel, the medial column and the lateral column), the medial arch drops, and the foot is leaning medially (Figure 19). The long flexor and extensor hallucis tendons become deforming forces and the deformity worsens (Figure 20). As a result, the second ray (metatarsal and toe) becomes overloaded (Figure 21), and the patient can develop hard plantar skin callosities and metatarsalgia. The plantar plate cannot withstand the increasing forces, degenerates and can rupture with time, destabilizing the second metatarsophalangeal joint that can subluxate. The forces acting on the second toe become imbalanced, losing the stabilizing effect of foot intrinsic muscles, and hammer or clawed toe deformities develop.

### 3.3 Clinical presentation and diagnosis

Patients present with obvious forefoot deformity and pain associated with the first and/or the lesser rays of the foot. The pain is usually associated with the prominent medial eminence of the first metatarsal head ("bunion"). Sometimes, the patient complains mostly of pain

affecting the second toe, or the plantar aspect of the second metatarsal head, developing skin callosities. Thorough examination of the foot and ankle, including neurovascular assessment, and examination for possible gastrocnemius muscle tightness, is required. Hallux metatarsophalangeal joint should be examined to establish whether it has unrestricted and pain-free range of motion. Hallucal sesamoids should also be examined for potential tenderness. Lesser rays' overload can cause subluxation of the lesser metatarsophalangeal joints, toe deformities, but also neuritic pain associated with interdigital ("Morton's") neuroma. Overload of the lesser rays may also result in stress fractures of the lesser metatarsals, or arthritis of the second and third tarsometatarsal joint. It may also be associated (as result or cause), with pes planus and hindfoot valgus.

### 3.4 Imaging

Weight bearing foot dorsoplantar and lateral radiographs and foot oblique radiograph are essential. More advanced imaging studies are only needed if indicated by clinical examination findings, to assess the condition of articular cartilage, sesamoids, presence of interdigital neuromata etc.

On the dorsoplantar weight bearing radiograph angles between the first, second metatarsals and proximal phalanx of the hallux are measured to classify the degree of deformity. Sesamoids position in relation to the metatarsal head is another indicator of deformity and joint congruity, measured by the distal metatarsal articular angle (Figure 22). Weight-bearing CT has been recently introduced in the 3-D assessment of hallux valgus deformities, offering information regarding first metatarsal pronation and hallucal sesamoid position, to aid preoperative planning.

### 3.5 Treatment

Asymptomatic hallux valgus deformities do not require active treatment. There is no evidence that corrective braces, orthotics, or custom made shoes can delay the progression of deformity. Furthermore, surgery is contraindicated solely for cosmetic reasons. Preoperative patients' counselling and management of expectation, and is very important.

**Nonoperative** management includes wide fitting, accommodative footwear, metatarsal dome off-loading insoles in the presence of metatarsalgia, lesser toe sleeves, or other types of lesser toe orthotics.

**Surgical** management is indicated for forefoot pain associated with activities of daily living, or for progressive deformities affecting the lesser rays. Historically more than 150 types of surgical procedures for treatment of hallux valgus have been described, many of which have been abandoned over the years. Aim of surgery is to re-balance forces around the first metatarsal head, to re-align the big toe. This is unlikely to be achieved with soft tissue release, only. Osseous procedures are aiming at de-tensioning the soft tissues, by (slightly) shortening the first metatarsal. On the other hand, excessive shortening will result in de-functioning of the first ray, and increasing transfer loading metatarsalgia.

One of the "historic" procedures is Keller's excision arthroplasty (Figure 23). It is very powerful in eliminating pain and hallux valgus deformity, however, it sacrifices the joint and is usually associated lesser ray metatarsalgia and de-functioning of the big toe, for reasons stated above. Therefore, currently it is rarely used, and only reserved for elderly patients, who would not tolerate

postoperative weight bearing restriction. For similar reasons, procedures like the Wilson's osteotomy (causing excessive shortening of 1st metatarsal) have also been abandoned.

Contemporary foot surgery favors osteotomies, that restore forefoot alignment and more normal foot biomechanics, that are reproducible, using internal fixation to provide a stable construct and allow early mobilization. Osteotomies are usually combined with lateral soft tissue release that allows sesamoid reduction under the metatarsal head.

Usually, orthopaedic foot and ankle surgeons master one procedure, which they use for the vast majority of surgeries they perform, whilst they perform some other procedures for less common deformities.

In Europe Scarf (Figure 24) and Chevron (Figure 25) osteotomies of first metatarsal, using double threaded compression screws for fixation, are frequently performed. Both have the advantage of intrinsic stability. **Chevron** is a less technically demanding, distal metaphyseal osteotomy. Performing a Chevron osteotomy with a longer plantar limb reduces the risk of avascular necrosis of the metatarsal head, as the vessels enter the plantar aspect of the metatarsal neck. **Scarf** is at the same time distal, diaphyseal, and proximal osteotomy, allowing for multiplanar correction, but is more invasive, and requires a longer

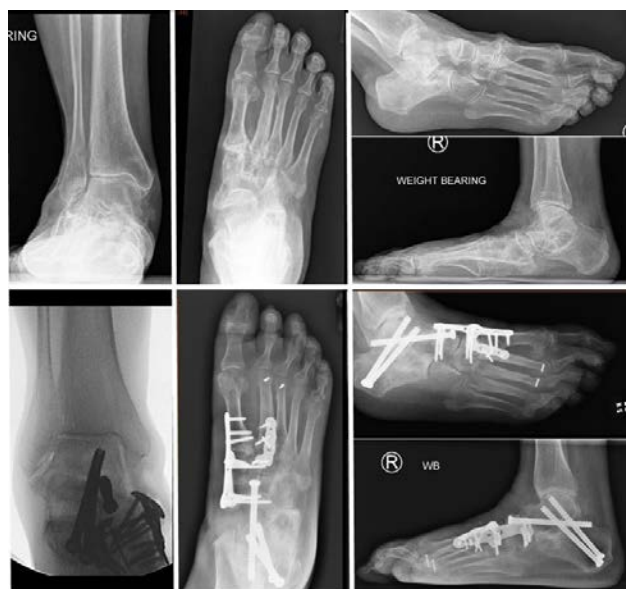

Figure 17: Complex flatfoot deformity with midfoot collapse and medial instability, requiring midfoot arthrodesis (in addition to a double hindfoot arthrodesis).

learning curve. In addition to the metatarsal osteotomy a medial closing wedge (Akin) proximal phalanx osteotomy can be performed to reduce valgus interphalangeus and big toe hyperpronation (Figure 26). It has been quoted that Chevron osteotomies should be used for intermetatarsal angles of less than 15°, whereas Scarf osteotomies are suitable for moderate to severe deformities with an intermetatarsal angle limit of 22°. Recent evidence, however, has shown that similar corrections can be performed using Scarf osteotomy, or modified Chevron osteotomy with a long plantar limb.

In the last few years studies using weight bearing CT scans to evaluate 3-dimensional forefoot alignment, revealed that rotational – pronation – deformity of the 1st metatarsal (also associated with increased mobility of the 1st ray) resulting in hallux valgus deformities, is an issue that cannot be assessed with 2-dimensional imaging, and may also require derotation osteotomy of the 1st metatarsal at the level of the proximal metaphysis (osteotomy, Figure 27) or the 1st

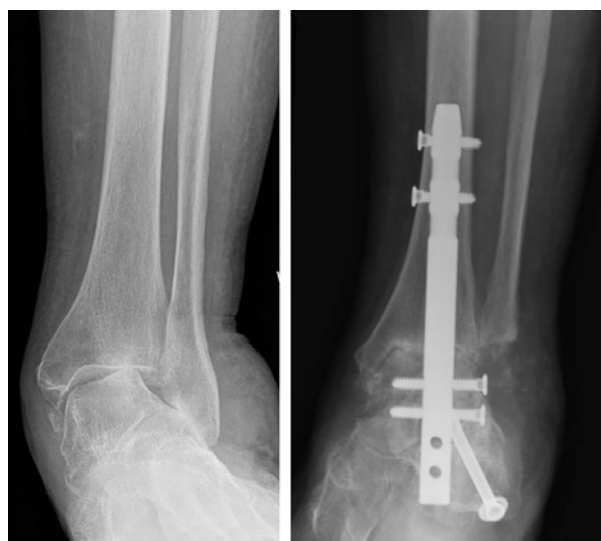

Figure 18: Tibiotalocalcaneal (TTC) arthrodesis using retrograde hindfoot nail fixation, is the treatment of choice for the majority of patients with flatfoot deformity that has affected the ankle joint.

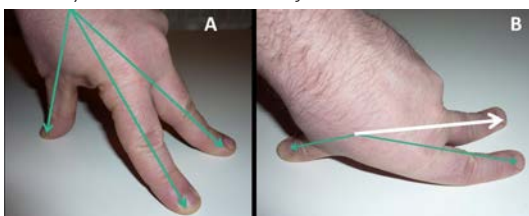


Figure 19: The position of the hand in these pictures (A, B) represents the pressure distribution in the foot. The foot behaves like a "tripod". Pressure is evenly distributed in neutral position (A) Valgus deformity with drop of medial arch, results in increased pressure across the lesser rays of the foot (B).

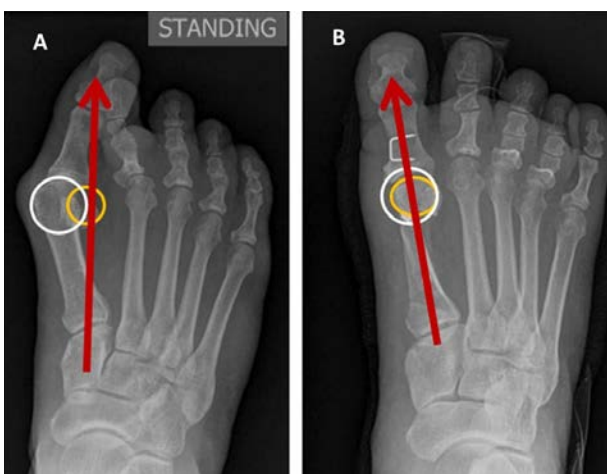


Figure 20: The red arrows represent the axis of the hallux long flexor and extensor tendons. In the deformed foot these tendons become deforming forces driving the big toe phalanges into valgus. In the corrected foot, the hallux sesamoids (orange circle) are, ideally, reduced under the 1st metatarsal head (white circle). Thus, the long flexor tendon (located) between the sesamoids), and the long extensor, are balanced, and in line with the metatarsal and the toe.

tarsometatarsal joint (Lapidus corrective arthrodesis). (Figure 28).

Hallux metatarsophalangeal joint corrective arthrodesis is also a very reliable procedure to treat severe deformities, with joint instability, with or without arthritis (Figure 29).

Deformities of the lesser rays and restoration of the normal forefoot cascade performing lesser metatarsal (eg. open Weil's, or percutaneous distal metatarsal) osteotomies are often performed simultaneously (Figure 26).

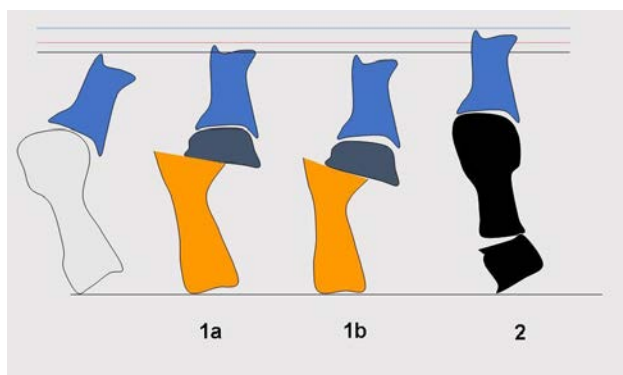


Figure 21 Dynamic pressure distribution in a neutral foot (A) and a foot with hallux valgus deformity (B). Hallux valgus results in overload of the 2nd and 3rd rays (red ellipsis).

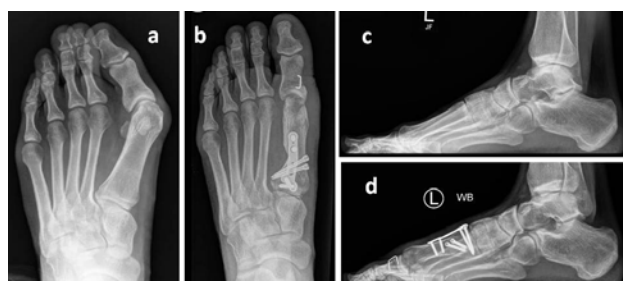

Figure 22: Severe hallux valgus deformity and widening of the medial cuneiform – second metatarsal interspace (a, white arrow) indicated the need for Lapidus arthrodesis (b).

Postoperatively patients use a surgical shoe, remaining touch to Postoperatively patients use a surgical shoe, remaining touch to partially weight bearing initially, gradually progressing to full weight bearing over a period of 6 weeks. Swelling and stiffness can be expected for 6 months. With contemporary surgical techniques these procedures are successful in 80-90% of cases in the short term, with satisfaction rate declining to 74% at 5 years. Recurrences are relatively uncommon (<10%) in the short term, whilst they occur frequently in the long term (up to 75% at 14 years). However, revision surgery is not required frequently. Postoperative metatarsalgia is reported in up to 20% of patients, infections occur in 3%, intraoperative fractures have been reported mainly during the learning curve with the Scarf osteotomy, nerve injury occurs in 6%, nonunions are rare, hallux varus (overcorrection) in 0-8%, deep vein thrombosis in less than 1%, whilst incidence of avascular necrosis of the first metatarsal head is around 4%, and often asymptomatic.

**Less invasive techniques** have been re-introduced in hallux valgus corrective surgery in recent years. Some percutaneous procedures are re-inventions of procedures described in the 1950's and 1960's (especially those not using fixation), and have been associated with high complication rates, with little or no scientific evidence to support their use. Contemporary ("3rd generation MIS") techniques, however, of percutaneous distal metatarsal osteotomies performed using special instrumentation, fluoroscopy and designed

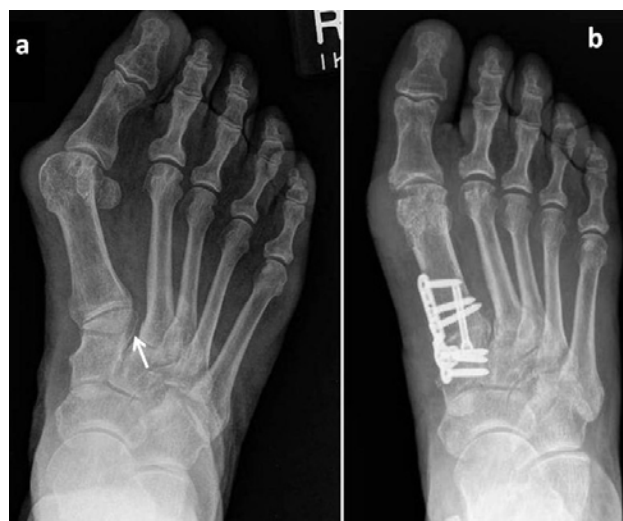

Figure 23: Radiograph (a) and clinical appearance (b) of recurrent hallux valgus and severe joint instability, treated successfully with corrective arthrodesis (c, d).

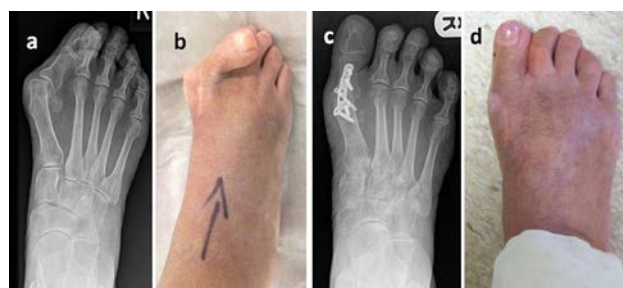

Figure 24: The Scarf is a "Z-type" diaphyseal first metatarsal osteotomy. The metatarsal head is displaced medially and fixed with low profile cannulated screws.

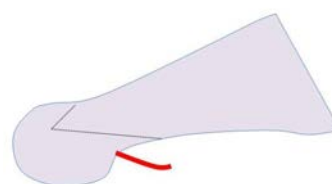


Figure 25: The Chevron osteotomy is a metaphyseal osteotomy. A long lower limb of the osteotomy (dotted line) preserves the blood supply (red) to the metatarsal head.

screws for fixation (Figure 30), have been shown to offer optimal short to mid-term results, similar to those of open procedures.



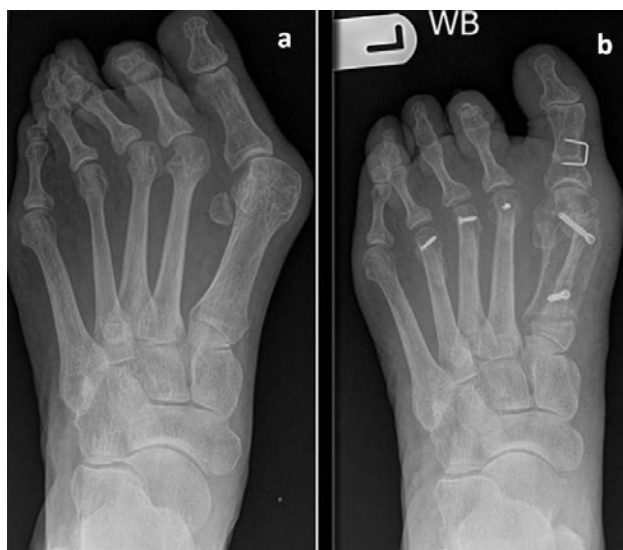

Figure 26: A 65-year old lady presented with symptomatic hallux valgus with hyperpronation, and painful deformities and subluxation of the lesser toes (a). Forefoot reconstruction including Scarf osteotomy of the first metatarsal, Akin osteotomy of the proximal phalanx and Weil's corrective osteotomies of the lesser metatarsals was performed.

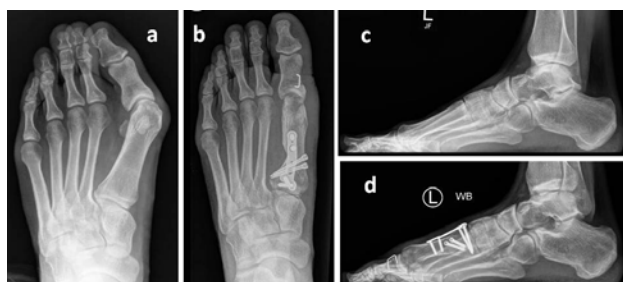

Figure 27: A young male patient presented with severe hallux valgus deformity (since his childhood) (a,c). The first metatarsal was long (a) and the joint very stiff. Lateral closing wedge first metatarsal osteotomy, supplemented by an Akin osteotomy, allowed very good correction (b,d). Stable fixation allowed early mobilization.

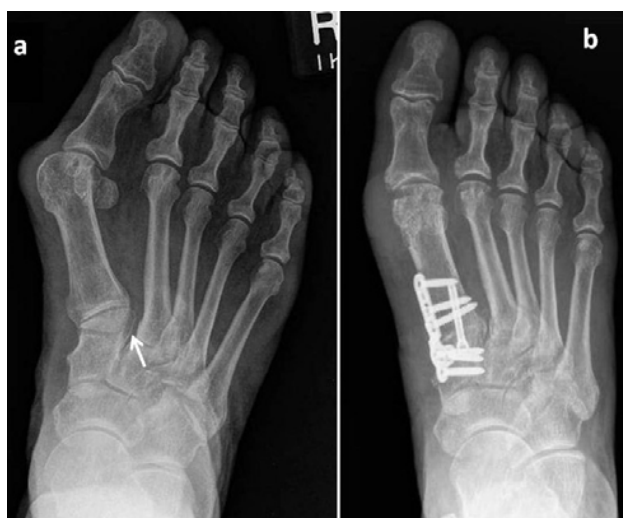

Figure 28: Severe hallux valgus deformity and widening of the medial cuneiform – second metatarsal interspace (a, white arrow) indicated the need for Lapidus arthrodesis (b).

Before undertaking percutaneous foot surgery, cadaveric training is mandatory. The relevant learning curve and increased intraoperative radiation exposure have to be taken into consideration, whilst the clinical benefits of the percutaneous technique are, so far, unclear,

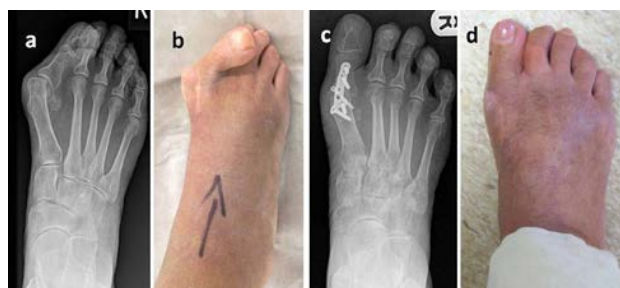

Figure 29: Radiograph (a) and clinical appearance (b) of recurrent hallux valgus and severe joint instability, treated successfully with corrective arthrodesis (c,d).

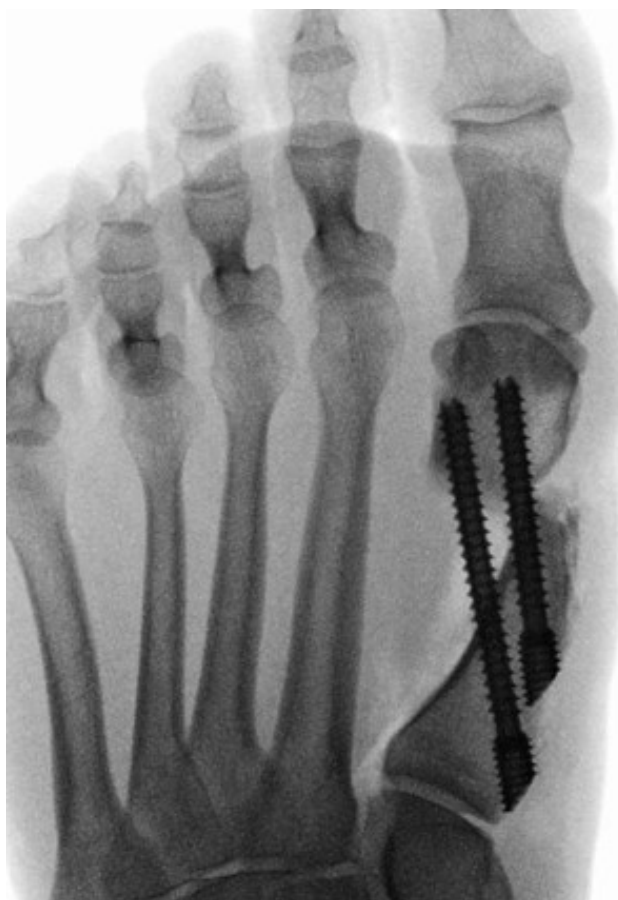

Figure 30: Example of "3rd generation" percutaneous distal metatarsal osteotomy with screw fixation.

as there is no scientific evidence of superiority of one technique over another.

## References:

1. Barg A, Pagenstert G, Hugle T, Gloyer M, Wiewiorski M, Henninger HB, Valderrabano V. Ankle Osteoarthritis. *Foot Ankle Clin N Am* 18 (2013) 411–426
2. Townshend D, Di Silvestro M, Krause F, Penner M, Younger A, Glazebrook M, Wing K. Arthroscopic versus open ankle arthrodesis: a multicenter comparative case series. *J Bone Joint Surg Am.* 2013 Jan 16;95(2):98–102.
3. Daniels TR, Younger AS, Penner M, Wing K, Dryden PJ, Wong H, Glazebrook M. Intermediate-term results of total ankle replacement and ankle arthrodesis: a COFAS multicenter study. *J Bone Joint Surg Am.* 2014 Jan 15;96(2):135–42.



4. Shih CL, Chen SJ, Huang PJ. Clinical Outcomes of Total Ankle Arthroplasty Versus Ankle Arthrodesis for the Treatment of End-Stage Ankle Arthritis in the Last Decade: a Systematic Review and Meta-analysis. *J Foot Ankle Surg.* 2020; 59(5):1032-1039. doi: 10.1053/j.jfas.2019.10.008.
5. Goldberg et al. Total Ankle Replacement Versus Arthrodesis for End-Stage Ankle Osteoarthritis: A Randomized Controlled Trial. *Ann Intern Med.* 2022 Dec;175(12):1648-1657. doi: 10.7326/M22-2058.
6. Christidis P, Lampridis V, Kalitsis C, Kantas T, Biniaris G, Gougoulas N. Supramalleolar osteotomies for ankle arthritis: a systematic review. *Arch Orthop Trauma Surg.* 2023;143(9):5549-5564. doi: 10.1007/s00402-023-04867-1.
7. Toullec E. Adult flatfoot. *Orthop Traumatol Surg Res.* 2015;101(1 Suppl):S11-7.
8. Gougoulas N. Adult acquired flatfoot deformity. *Acta Orthopædica et Traumatologica Hellenica* 2018;69(2):85-98. (available online at: [http://eexot.gr/wp-content/uploads/2018/09/ISSUE\\_2\\_2018-1.pdf](http://eexot.gr/wp-content/uploads/2018/09/ISSUE_2_2018-1.pdf))
9. Myerson MS, Thordarson DB, Johnson JE, Hintermann B, Sangeorzan BJ, Deland JT, Schon LC, Ellis SJ, de Cesar Netto C. Classification and Nomenclature: Progressive Collapsing Foot Deformity. *Foot Ankle Int* 2020;41(10):1271-1276.
10. Chien BY, Vosseller JT, Younger A, Greisberg J. Surgical Treatment of the Flexible, Progressive Collapsing Foot: Deformities, Definitions, and Decisions. *Instr Course Lect.* 2023;72:555-563
11. Perera AM, Mason L, Stephens MM. The pathogenesis of hallux valgus. *J Bone Joint Surg Am.* 2011;93:1650-61
12. Chong A, Nazarian N, Chandrananth J, Tacey M, Shepherd D, Tran P. Surgery for the correction of hallux valgus: minimum five-year results with a validated patient-reported outcome tool and regression analysis. *Bone Joint J.* 2015;97-B(2):208-14.
13. Steadman J, Barg A, Saltzman CL. First Metatarsal Rotation in Hallux Valgus Deformity. *Foot Ankle Int.* 2021;42(4):510-522. doi: 10.1177/1071100721997149.
14. Trnka HJ. Percutaneous, MIS and open hallux valgus surgery. *EFORT Open Rev.* 2021;28;6(6):432-438. doi: 10.1302/2058-5241.6.210029.
15. Miranda MAM, Martins C, Cortegana IM, Campos G, Pérez MFM, Oliva XM. Complications on Percutaneous Hallux Valgus Surgery: A Systematic Review. *J Foot Ankle Surg.* 2021;60(3):548-554. doi: 10.1053/j.jfas.2020.06.015.
16. Lewis TL, Ray R, Robinson P, Dearden PMC, Goff TJ, Watt C, Lam P. Percutaneous Chevron and Akin (PECA) Osteotomies for Severe Hallux Valgus Deformity With Mean 3-Year Follow-up. *Foot Ankle Int.* 2021;42(10):1231-1240. doi: 10.1177/10711007211008498.
17. Besse JL. Metatarsalgia. *Orthop Traumatol Surg Res.* 2017 Feb;103(1S):S29-S39. doi: 10.1016/j.otsr.2016.06.020
18. Matar HE, Platt SR. Overview of randomised controlled trials in hallux valgus surgery (2,184 patients). *Foot Ankle Surg.* 2021;27(4):351-356. doi:10.1016/j.fas.2020.04.013.
19. Alimy AR, Polzer H, Ockoljic A, Ray R, Lewis TL, Rolvien T, Waizy H. Does Minimally Invasive Surgery Provide Better Clinical or Radiographic Outcomes Than Open Surgery in the Treatment of Hallux Valgus Deformity? A Systematic Review and Meta-analysis *Clin Orthop Relat Res.* 2023 Jun 1;481(6):1143-1155. doi: 10.1097/CORR.0000000000002471.

## Multiple Choice Questions

1. What is not true about adult flatfoot deformity (one correct answer):
  - a. It is a 3-dimensional deformity
  - b. Calcaneal osteotomy is indicated in rigid deformities
  - c. It is associated with progressive foot collapse
  - d. Initial management is nonoperative
2. In stiff adult flatfoot deformity with ankle valgus arthritis (one correct answer):
  - a. Ankle arthroscopy and deltoid repair is the treatment of choice
  - b. The heel corrects into varus during heel raising
  - c. Hindfoot arthrodesis using retrograde nail is the most reliable treatment option
  - d. Triple arthrodesis is always needed
3. Which one is correct for Hallux valgus corrective surgery?
  - a. Lapidus arthrodesis cannot restore metatarsal rotation/torsion
  - b. Minimally invasive offers superior results compared to open surgery
  - c. Recurrence is common 10 years or more after corrective surgery
  - d. Metatarsalgia is not common after surgery
4. Ankle osteoarthritis (one correct answer):
  - a. It is often the result of chronic lateral instability
  - b. Conservative treatment has no role in Takakura Stage 2 and 3 ankle Osteoarthritis
  - c. Hyaluronic Acid Intra-Articular injections offer no benefit in ankle OA
  - d. Arthroscopic debridement offers good results
5. Which one is correct regarding joint sacrificing surgery in end stage ankle OA:
  - a. Aseptic loosening of TAR is a major problem, that can lead to early revision surgery
  - b. Ankle arthrodesis is best performed only in elderly patients
  - c. Ankle arthrodesis is always associated with adjacent joints OA
  - d. Valgus ankle alignment is a good indication for TAR

## Answers

1b, 2c, 3c, 4a, 5a



*Luigi Zagra*  
luigi.zagra@fastwebnet.it

*Rocco D'Apolito*  
roccodapolito@hotmail.it

Hip Department, Istituto Ortopedico Galeazzi IRCCS, Milan Italy

## Hip Reconstruction

### Abstract

Total hip arthroplasty is a successful and cost-effective procedure with more than one million operations performed worldwide each year. To achieve good results and meet patient expectations, surgeons need to be aware of the key points of this procedure, starting with indication and preoperative evaluation. The radiological workup is discussed in the text, reporting what to look for in a standard X-ray and when to use further imaging techniques. The restoration of hip biomechanics is crucial to obtain good results, and preoperative templating helps surgeons achieve this goal by anticipating possible intraoperative troubles. Several surgical approaches exist, each one with advantages and disadvantages. The morphology of the proximal femur influences the stem choice, whereas the age holds sway over the fixation method. Respecting the principles of press-fit and cemented fixation is of paramount importance to ensure satisfactory long-term results. Therefore, basics of reaming and cementing techniques are also reported. Moreover, anatomical landmarks and components orientation have to be taken into account intraoperatively. Available bearing options allow the surgeon to choose the best coupling for the single case, selecting among ceramic or polyethylene inserts and ceramic or metal heads.

### 1. Introduction

Hip reconstruction is aimed to give full function recovery of the hip joint. When severely affected, the hip joint can become cause of serious discomfort and limitations for the patient, leading to the loss of ability to walk.

Major intra-articular deformities or incongruencies and/or cartilage degeneration require joint replacement, which is reconstructed using artificial materials. This procedure is called Total Hip Replacement (THR) or Total Hip Arthroplasty (THA) and it is one of the most successful operations ever performed. It has been defined the operation of the century because of its high cost-effectiveness <sup>(1)</sup>. More than one million THRs are performed worldwide per year. The clinical outcome is excellent and the implant is functioning over time: survivorship greater than 95% at 10 years is reported by registries data and more than 80% of the prostheses survive at 25 years follow-up <sup>(2)</sup>.

The "happy" or "forgotten" replaced hip is the result of a series of standardised and well executed steps. These include indication, preoperative assessment, prevention of complications, preoperative

planning and templating for good implant selection and restoration of biomechanics, careful surgery and finally controlled postoperative phase.

### 2. Indications

Indications for THR are listed in Table 1. The correct indication is the first step of a successful joint reconstruction, as the optimal clinical results are achieved through a careful patient selection. It should be based on pain, functional impairment, physical examination and not just on radiographic findings. The risks of surgery must always be weighed against the benefits, so even though THR is a safe procedure the pros and cons of each operation must always be carefully evaluated and discussed, offering the best evidence-based option available to the individual patient <sup>(3)</sup>. The surgeon should always bear in mind that the most important factor in satisfaction is meeting patient's expectations <sup>(4)</sup>, as unrealistic expectations are the main cause of dissatisfaction and health-care providers should help their patients to develop realistic expectations.

Pain, functional impairment such as limping, loss of range of motion, leg length discrepancy can be effectively treated with a THR. Differential diagnosis should always be considered and other sources of pain in the hip region should be excluded. (Table 2)

Diagnosis is based on clinical and radiological findings. X-rays are usually sufficient for this purpose. More sophisticated

**Table 1. Indications for THR**

Primary osteoarthritis
Secondary osteoarthritis
<ul style="list-style-type: none"> <li>• DDH</li> <li>• SCFE</li> <li>• LCP</li> <li>• AVN</li> <li>• Inflammatory disease (RA, SA)</li> <li>• Post-traumatic</li> <li>• Tumours</li> </ul>
Femoral head/neck fractures

**Table 2. Differential diagnosis of hip pain**

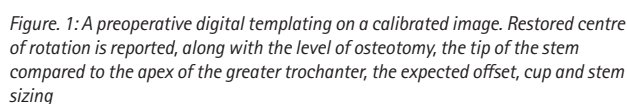
Pain of spine origin
Trochanteric syndrome
Tendon problems (Ad muscles, ileopsoas)
Inguinal hernia or other non orthopaedic origins (neurologic, vascular, visceral)

### 3. Preoperative evaluation

Preoperative antero-posterior view of the pelvis is mandatory. The X-ray should be taken in supine position with symmetric internal-rotation of the legs. The surgeon must be aware that in case of more severe arthritis, the hip is usually externally rotated and for this reason X-rays can be misleading. Signs of external rotation that can influence radiographic parameters in the AP view such as the femoral off-set or the neck inclination are listed in Table 5. X-rays should be completed by a shoot-through lateral hip view in all the cases. In the presence of more complex lower limb deformities such as high dislocated hips, major shortening or lower limb deformities, lower extremity full leg standing X-ray for the off-set and axis of the lower limbs is recommended. Based on clinical features, X-rays of the spine in antero-posterior and lateral view in standing and if necessary in sitting position can be useful for evaluating the hip/spine parameters. In case of post-traumatic acetabula, protrusion, or major development dysplastic deformities, a CT scan is also recommended in order to evaluate the acetabular orientation and depth, the presence of osteophytes and of previous hardware, the shape of the proximal femur and the neck anteversion.

Internal rotation	Spherical head (without fovea capitis)
	Femoral neck clear
	Less trochanter quite hidden
Neutral rotation	Femoral head deformed by the fovea capitis
	Short femoral neck
	Visible less trochanter
External rotation	Round head
	Short and vertical neck
	Great trochanter superimposed on the neck
	Bulky less trochanter

Restoration of hip biomechanics during joint reconstruction is of paramount importance for several reasons: functional outcome, joint stability, implant longevity as poor biomechanics is associated with wear. It includes the restoration of the centre of rotation of the joint, the proper femoral off-set to achieve the correct lever arm of the Ab muscles, the exact neck inclination and the leg length control. For these aims preoperative templating is mandatory. Nowadays templating is digital (Fig. 1) with promising 3D developments for the future.



It is essential for choosing the type of implant and for the size of the implant components. In this way, information on the level of the neck osteotomy and on the position of the cup is obtained prior to surgery.

Both cups and stems, whether cemented or not, should be selected according to the bone shape (Dorr's classification), bone quality and age of the patient and femoral templating is essential to this choice. The different designs, in particular of the cementless stems, are then evaluated to better fit into the proximal femur.

Implant fixation could be cemented, cementless or hybrid. Irrespective of the preferences which change among the countries and among the different centres, correct principles and techniques must be applied for each case in order to avoid complications. An orthopaedic surgeon should be confident with both cemented and cementless techniques in order to apply them in each individual case.

## 5. Principles of fixation and surgical technique

### 5.1 The cup

The principles of cementless fixation include reliable mechanical primary stability to allow osseointegration that guarantees a durable biological secondary stability. "Osseointegration" is the attachment of lamellar bone to implants without fibrous tissue. It takes four to twelve weeks and may continue for up to three years<sup>[5]</sup>. Micromotion is not conducive to bony incorporation, if greater than 150  $\mu\text{m}$ , it is incompatible with bone ingrowth, between 40 and 150  $\mu\text{m}$ , leads to a combination of bone and fibrous tissue formation, and if <20  $\mu\text{m}$  results in predominantly bone formation<sup>[6]</sup>. For this purpose, a rough surface with adequate grip and biocompatibility is necessary. Titanium has widely demonstrated to have these features and titanium plasma-sprayed is the coating more commonly used for primary routine cases. In the last decades different high porosity implants have been developed. Porous structures have the possibility to balance different properties both with tantalum and titanium: an elastic modulus close to the bone able to prevent stress shielding, an average mechanical strength capable to resist to the applied load, controlled single pore dimensions to stimulate osseointegration, an overall porosity to grant interconnection among pores and of course corrosion resistance and biocompatibility. These materials can make a great difference and an improvement in revision surgery and in complex case with poor bone stock.

As well as the material and surface finishing, the shape of the cup is also important, and the majority of cups used today are hemispherical in shape. The primary stability is guaranteed by press-fit insertion. There are two options for improving the press-fit: the cup is squeezed at the equatorial plane (Fig 2A) or the cup is larger than the allocated seat (Fig. 2B). According to this technique, underreaming 1-2 mm is mandatory to achieve a reliable stability<sup>[7]</sup>. For this purpose, it is important to retain the "sandwich" structure of the acetabulum preserving the bone and reaming only the cartilage and the osteophytes, as a damage of the outer cortex and/or of the quadrilateral surface can lead to a progressive migration. In case of lack of primary stability, two or more screws can be added in the safe zone

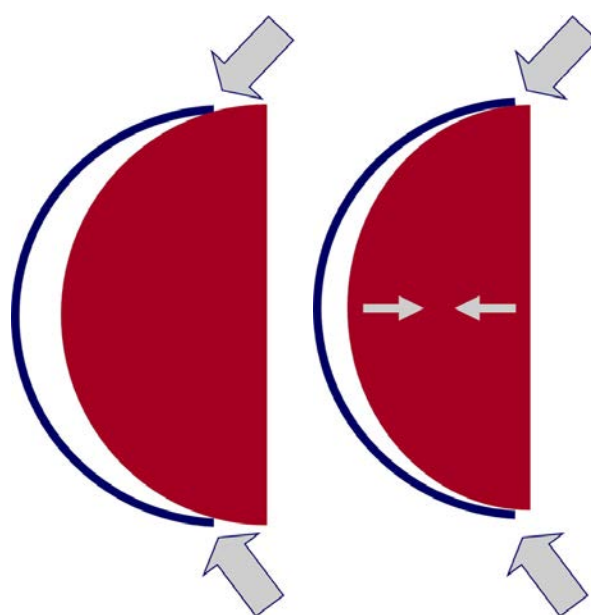


Figure. 2A: Cup squeezed at the equatorial plane

Figure. 2B: Cup larger than the reamed socket.

(supero-lateral quadrant).

In case of cemented cup, a good surgical technique is essential. Acetabular preparation includes reaming, creation of some holes in the reamed acetabulum for cement inter-digitation, accurate drying and pressurization of the all poly cup during cement polymerization.

Regardless of the implant or type of fixation is used, cup orientation is a key point for implant success as malalignment can lead to both early (dislocation) and late (wear) complications. According to historical Lawinnek's safe zones<sup>[8]</sup>, cup must be placed at  $40^\circ \pm 10^\circ$  of inclination and between  $15^\circ \pm 10^\circ$  of anteversion. These parameters are still valid nowadays but should be interpreted in light of more recent findings including hip/spine relationships and anatomical variations of the pelvis, so that the ideal cup position for some patients will lie outside this zones.

The transverse acetabular ligament (TAL) is a simple and easy to use landmark. It is identifiable in most cases and can guide the surgeon to optimise cup version. TAL should be recognised and followed in all the procedures.

### 5.2 The stem

The principles of cementless fixation are the same on the femoral side:

- Reliable mechanical primary stability to allow osseointegration
- Durable biological secondary stability
- If possible load transfer to the proximal femur
- Bone stock preservation

Titanium alloy with a rough surface is the material of choice for achieving these purposes. The size of the pores on the surface should be between 50  $\mu\text{m}$  and 400  $\mu\text{m}$ , and the percentage of voids within the coating should be between 30% and 40% to maintain mechanical strength<sup>[10]</sup>.

The reason for transmitting the forces to the proximal femur is to avoid stress shielding (which means loss of bone quality in the proximal femur due to distal fixation and transmission of forces), cortical hypertrophy at the level of the distal fixation and thigh



pain, that was frequently associated in the past with cementless stems with "fit and fill" principles at the distal part of the stem. Whenever possible, proximal fixation of the stem should be preferred, according to femoral shape and bone quality.

Cementless designs differ from one another in terms of geometry and the means of achieving initial fixation. According to the design, the cementless stems are classified into two main categories: straight stems (which include different types of wedge shape and/or taper geometry) and curved anatomic stems<sup>(11)</sup>. Special designs and modular implants should be consider in complex cases or deformities. Each type of stem has a different surgical technique, which can vary significantly. Although loosening and thigh pain are less common with modern stem designs, stress shielding may still be observed. In the last decades the so called "short stems" have been introduced with the aim of bone preserving and transmission of forces in the proximal femur. Even though they are theoretically promising, there is still paucity of long-term data when compared to traditional well documented implants.

Stem selection is part of the procedure. No single cementless stem is suitable for all the different types of femurs. The choice should be based on the bone shape according to Dorr's classification and on the bone quality, as well as the age of the patient. According to registry data and clinical trials there is quite clear evidence that, at least over the age of 70/75, cemented fixation of the femur has better survival compared to cementless.

Cemented stems are most commonly of cobalt-chrome and polished. Principles of modern fourth generation cementation technique include the use of femoral plug, accurate drying of the bone after jet lavage (the latter being controversial), retrograde cement insertion with a long syringe and pressurization after vacuum preparation of the cement, distal and possibly proximal centralizer. Most of the studies and large registry data are in favour of the use antibiotic-loaded cement. According to registries, hybrid fixation with cementless cup and cemented stem can be considered a good option for the older population, full cemented implants are also a good choice for the old patient, while in patients younger than 70 the first choice might be cementless fixation. Anyway, as mentioned above, age is only one aspect of the parameters influencing a successful fixation, as there are others as bone quality , shape and comorbidities.

The orthopaedic surgeon should be familiar with both cemented and different types of cementless stems. Some cementless designs can harm the greater trochanter in different ways and may require different lateral preparation. In general, care must be taken to avoid under sizing of the stem, avoiding varus position (this might be more important when using some design than others) and controlling the anteversion. Stem positioning influences leg length, soft tissues tension and stability. In this regard, to make a leg longer, a cemented stem can be left prouder (on the contrary, sunk deeper to shorten the limb), while implanting a bigger cementless stem to increase the length usually increases off-set as well. Heads with longer necks increases both length and off-set. Extended off-set stems can be carefully used when the anatomy or the joint stability require this type of solution.

5.3 Approaches

Various approaches are suitable for successful hip reconstruction, including anterior, antero-lateral, direct lateral, superior, posterior,

or 'mini' posterior, each with its own advantages and disadvantages. It is important to note that popularity and fashion should not be the sole determining factors in selecting an approach. Objective evaluation of the benefits and drawbacks of each technique is crucial. It is crucial to fully preserve Ab muscle function as any damage can lead to poor outcomes with no effective solution. Additionally, it is important to balance the rate of complications with the supposed advantages and ensure a clear view of the landmarks for optimal implant positioning to ensure long-term implant survival. The approach should also be relatively simple, without causing significant damage to the soft tissues, and capable of addressing intraoperative complications in a straightforward manner. Additionally, the approach must be suitable for using different types of implants, particularly those with the best long-term results, including cemented components. The current evidence comparing outcomes following anterior versus posterior THR does not demonstrate clear superiority of either approach. We recommend that the choice of surgical approach for THR be based on patient characteristics, surgeon experience, and the preferences of both the surgeon and the patient until more rigorous, randomized evidence becomes available.

5.4 Type of bearings

Late failure of joint replacements is commonly caused by wear and osteolysis. Therefore, selecting the appropriate bearing surface is crucial, as is having knowledge of tribology<sup>(12)</sup>. Tribology is the science that studies friction, lubrication and wear between two surfaces which are in close contact and move one on the other. The name is derived from the Greek word 'Τριβος,' which means rubbing. Wear is the surface damage with progressive loss of material (debris) due to friction between moving surfaces. Debris is composed by articles of different material and size shed from the surface of the various parts of the implant due to wear. Osteolysis is the bone resorption due to biological response to debris including osteoclasts activation that can compromise the bone stock around the implant and lead to loosening of the prosthesis in the advanced phase. Fretting is the relative low amplitude movement (oscillation

Table 6. Main disadvantages for each bearing surface

Bearing surface	Disadvantages
Metal-on-polyethylene	Wear and osteolysis
Ceramic-on-polyethylene	Wear and osteolysis
Metal-on-XLPE	Decreased mechanical properties
Ceramic-on-XLPE	Decreased mechanical properties
Ceramic-on-ceramic	Breakage and squeaking
Metal-on-metal	ARMD (ALVAL, high ion levels, osteolysis, pseudotumours)

XLPE, highly cross-linked polyethylene; ARMD, adverse reaction to metal debris; ALVAL, aseptic lymphocyte-dominant, vasculitis-associated lesion

and sliding) between two mechanically joined parts, under load conditions (between 1 µm and 100 µm). All modular junctions are susceptible to the loading of the body. It provokes wear (debris) and corrosion.

Corrosion is the surface degradation due to electrochemical interactions producing metallic ions and salts which applies only to metals. Different distinct forms of corrosion have been described (galvanic, fretting, crevice, stress, etc.).

Adverse Reaction to Metal Debris (ARMD) or Adverse Local Tissue Reaction (ALTR) includes a variety of effects of metal debris including osteolysis and pseudotumors, blood metal ions can be elevated.

Each bearing surface has its well-known disadvantages (Tab 6). On the other hand, there is limited evidence regarding comparative effectiveness of various hip implant bearings. RCTs show similar short- to mid-term survivorship among Ceramic on Ceramic (CoC), Ceramic on Crosslinked Polyethylene (CoXLPE) and Metal on Crosslinked Polyethylene (MoXLPE) in patients younger than 65.

Conventional polyethylene (PE), sterilized by oxygen free gamma irradiation or ethylene oxide, with correct packaging, may yield good clinical long-term results. However, metal-on-conventional PE (MoPE) has a higher risk of revision compared with MoXLPE. For this reason, XLPE is considered a better option<sup>(13)</sup>. XLPE is going to achieve good medium to long term results. The improved wear resistance made possible the use of larger heads (32 mm and 36 mm, depending on the cup size) improving the joint stability. The cross-linking process, while increasing the wear properties of PE decreases the mechanical ones, making the liners more at risk of fatigue fracture. For this reason, a minimum XLPE thickness (5-6 mm) should be preserved. Recently, XLPE liners with the addition of antioxidants such as vitamin E were introduced into the market with the aim of reducing the oxidation in vivo. In this way, re-melting is not necessary to avoid the oxidation, and mechanical proprieties are better preserved. Consequently, the liner can also be thinner and larger heads can be used.

CoPE is at least the same, but usually better than Met-PE, with less wear and lower revision rate. The reason is that ceramic has a higher hardness (5x), it cannot be scratched (less risk of damage during implantation). The surface finishing has only negative roughness rather than deformation. It has better wettability and thus a better lubrication, and it is the material with the highest bio-inertness.

There are growing concerns regarding the trunnions with metal heads in Met-PE, while there are no clinical reports on ceramic heads. Therefore, CoXLPE appears to be a reasonable bearing surface, with the only potential issue being the cost. The risk of breakage is very low, with only occasional reports, and it is insignificant when combined with PE.

The third option for the best performing bearing could be CoC. Registries report better survival rates for heads 32 mm or larger (36 mm). It is important to handle the metal back with care, as ceramic liners can be at risk in the event of shell deformation in thin press-fit cups that depend on bone quality, instruments, and surgical technique. Therefore, a minimum thickness of the metal back is necessary. Additionally, ceramic is highly sensitive to malpositioning, making it less forgiving in this regard. CoC with correct positioning has the lowest wear rate, making it a suitable option for young patients when used in conjunction with careful surgical technique.

## References:

1. Learmonth ID, Young C, Rorabeck C (2007) The "operation of the century": total hip arthroplasty. *Lancet* 370(9597):1508-1519
2. Pivec R, Johnson AJ, Mears SC, Mont MA (2012) Hip arthroplasty. *Lancet* 380(9855):1768-1777
3. Benson M, Boehler N, Szendroi M, Zagra L, Puget J (2014) Ethical standards for orthopaedic surgeons. *Bone Joint J* 96-B(8):1130-1132
4. Anakwe RE, Jenkins PJ, Moran M (2011) Predicting Dissatisfaction After Total Hip Arthroplasty: A Study of 850 Patients. *J Arthroplasty* 26(2):209-213
5. Albrektsson T, Branemark PI, Hansson HA, Lindstrom J (1981) Osseointegrated titanium implants. Requirements for ensuring a long-lasting, direct bone-to-implant anchorage in man. *Acta Orthop Scand* 52 (2):155-170
6. Pilliar RM, Lee JM, Maniopoulos C (1986) Observations on the effect of movements on bone ingrowth into porous-surfaced implants. *Clin Orthop Relat Res* 208:108-113
7. Adler E, Stuchin SA, Kummer FJ (1992) Stability of press-fit acetabular cups. *J Arthroplasty* 7(3):295-301
8. Lewinnek GE, Lewis JL, Tarr R, Compere CL, Zimmerman JR (1978) Dislocations after total hip-replacement arthroplasties. *J Bone Joint Surg* 60 (2):217-220
9. Abdel MP1, von Roth P, Jennings MT, Hanssen AD, Pagnano MW. (2016) What safe zone? The vast majority of dislocated THAs are within the Lewinnek safe zone for acetabular component position. *Clin Orthop Relat Res* 474 (2):386-391
10. Albrektsson T, Branemark PI, Hansson HA, Lindstrom J. (1981) Osseointegrated titanium implants. Requirements for ensuring a long-lasting, direct bone-to-implant anchorage in man. *Acta Orthop Scand* 52 (2):155-170
11. Khanuja HS1, Vakil JJ, Goddard MS, Mont MA (2011) Cementless Femoral Fixation in Total Hip Arthroplasty. *J Bone Joint Surg Am* 93 (5):500-509
12. Zagra L, Gallazzi E (2018) Bearing surfaces in primary total hip arthroplasty. *EFORT Open Rev* 3(5) 217-224
13. Paxton et al (2015) Metal-on-conventional polyethylene total hip arthroplasty bearing surfaces have a higher risk of revision than metal-on-highly crosslinked polyethylene: results from a US registry. *Clin Orthop Relat Res* 473(3):1011-1121

## Questions

1. Regarding the acetabular component:
  - a. Micromotion at the bone-implant interface is advisable to enhance biological fixation
  - b. When using hemispherical cup line-to-line reaming (same size of the real diameter of the cup) is mandatory to achieve press-fit
  - c. Osteophytes must be preserved to strengthen cup fixation
  - d. Underreaming 1 to 2 millimeters is recommended when using hemispherical cup
  - e. Neutral version is the target
2. Regarding the stem:
  - a. The surgeon should be confident with a specific stem design and use it for all femoral shapes
  - b. Fit and fill is the dominant trend for new designs
  - c. Proximal fixation should be preferred, whenever possible
  - d. Extendend off-set stems should be the first choice
  - e. High pain is the most frequent complication of short stems
3. Factors influencing the approach are:
  - a. Surgeon experience, patient characteristics, implant features
  - b. Patient choice, body mass index, age
  - c. Surgeon preference, fixation method, gender
  - d. Surgeon should be guided by patient preference
  - e. Patient characteristics, fixation method, gender
4. Based on available data what is the best choice for a 78-years-old female with osteoporotic bone undergoing THA for primary arthritis:
  - a. Hybrid fixation, using cemented cup and press-fit femoral component
  - b. Uncemented THA, using proximally coated stem
  - c. Hybrid fixation, using uncemented cup and cemented femoral component
  - d. Uncemented THA, enhancing acetabular fixation with 1 or 2 screws
  - e. Uncemented THA, using fully coated stem

## Answers

1d, 2c, 3a, 4c



*Prof. Luc Favard*

University Hospital of Tours,  
CHU Trousseau 37044 Tours Cedex  
Luc.favard@univ-tours.fr

## Degenerative Disorders Of The Shoulder & Elbow

### Abstract

The causes of degenerative disorders of the rotator cuff or glenohumeral joint are multifactorial. However, the morphology of the scapula, and more specifically of the acromion and glenoid, seems to play an important role. Indeed, the critical shoulder angle is a predictive factor of cuff tear and has been associated to a risk of osteoarthritis. The same applies to the glenoid version and inclination. Thus, the genesis of the cuff lesions and the development of glenohumeral arthritis are rather associated to the lateral extension of the acromion, than to an extrinsic component.

The natural history of cuff tears is key for the therapeutic decision-making. On average, the lesions begin 15 mm back to the bicipital groove and then gradually extend either backwards, causing a deficit of the external rotators, or forward, leading to the pseudo paralytic shoulder. At the same time, the tendon retracts and the muscle degenerates with atrophy and fatty infiltration, the stage of this latter being an important prognostic factor of the tendon's reparability. The initial medical treatment lasts around six months. If the tendon is repairable, diverse techniques are available for the treatment but none of them has been shown as being superior. Many techniques have also been described for cases where the tendon is not repairable, but again with no evidence of supremacy for any of them. In the presence of a large antero-superior rupture with a pseudo paralytic shoulder, indications for reverse prosthesis should be favoured.

Osteoarthritis of the shoulder is secondary to many aetiologies (trauma, instability, rheumatoid arthritis (RA), rotator cuff tear, necrosis, etc.). In primary osteoarthritis, analysis of the glenoid orientation and wear is essential for the choice of treatment. As management of posterior decentring of the humeral head can be difficult, a 3D analysis of the abnormalities and/or virtual surgical implantation with patient-specific shoulder guides are extremely helpful.

Osteoarthritis of the elbow is sometimes primary, often secondary to trauma or RA. Failure of conservative treatment with limitation of the joint's functional range of motion is an indication for surgical management. Joint releases, removal of foreign bodies or synovectomy can be performed under arthroscopy. To override conservative treatment, the surgeon should consider either an arthrodesis (rarely performed nowadays) or a prosthesis. There are several types depending on the constraint. The indication of these prostheses depends on the aetiology and functional requirements of the patient.

### I. Degenerative disorders of rotator cuff

The natural history of the rotator cuff disease is tendon deterioration, as shown by the prevalence of tears of these tendons, reported by numerous studies <sup>[1, 2, 3]</sup>. Due to the significant differences in the population traits and the variability in the design of these studies, the reported prevalence in the general population varies widely depending on the age groups and the type of imaging used (ultrasound, MRI or CT), but also on whether or not the patient is asymptomatic. The thickness of the tear is also determining, complete ruptures ranging from 15% <sup>[3]</sup> to 50% <sup>[1]</sup> after the age of 75. Consistent across studies is the finding that a superior age is associated with increased prevalence of rotator cuff pathologies. About 25% of the patients older than 60 years and, half of the patients older than 80 years, developed rotator cuff tear <sup>[4]</sup>.

#### 1.1 Role of the acromion

For long time, the acromion – an extrinsic factor in the subacromial impingement – was the most obvious cause of cuff tear <sup>[5, 6]</sup>. However, recently, other factors – mainly intrinsic – have been identified as risk factors of rupture such as tendon hypovascularization <sup>[7]</sup>, collagen changes during aging, oxidative stress, or general factors such as hypersolicitation (profession, dominant side), diabetes, tobacco, or genetic traits <sup>[8]</sup>.

The relationship between subacromial impingement and rotator cuff disease in the etiology of rotator cuff injury is a matter of debate, as it is not easy to explain early lesions, interstitial lesions or articular sided lesions. Some groups state that rotator cuff disease is due to primary extrinsic compression <sup>[9]</sup>, whereas others maintain that subacromial impingement is secondary to cuff weakness and humeral migration against the overlying structures <sup>[7]</sup>.

Therefore, acromioplasty, which initially grew exponentially <sup>[10]</sup>, no longer seems appropriate in such a systematic way as literature has shown that it does not significantly change the result, compared to a simple bursectomy <sup>[11]</sup> or, also, that the results of cuff repairs associated or not with acromioplasty would not differ fundamentally <sup>[12, 13]</sup>. Finally, only lesions on the bursal side with bursitis and undersurface of the acromion seem to be directly linked to an authentic subacromial conflict, justifying an acromioplasty. It is legitimate to question if apophysis of the scapula has not been wrongly accused in the genesis of rotator cuff tears. In fact, recent studies about the lateral part of the acromion report important information on the relationship between acromion and cuff rupture <sup>[14, 15]</sup>.



The main role of the acromion is to deliver insertion to the deltoid, an essential muscle of the shoulder. This muscle is known and described as an abductor muscle, particularly in its middle part. At the beginning of the abduction, the deltoid force is an ascending force. This force is counterbalanced by the synergistic action of the rotator cuff, which keeps the head centered in front of the glenoid. The more the abduction progresses, the less the ascending force of the deltoid is high, becoming a glenohumeral coaptation force. This commonly accepted notion is not entirely representative of reality. The muscle fibres of the middle deltoid originate from the acromion and wind around the tuberosities before inserting on the humeral shaft. Contraction of this muscle during active abduction pulls the humeral shaft upward and presses the humeral head against the glenoid cavity. This pressure increases the glenohumeral coaptation forces. If the lateral extension of the acromion is small, the compressive force component is high. Conversely, if the lateral extension of the acromion is high, the pressure of the deltoid on the greater tuberosity is lower, the ascending force is predominant, and the rotator cuff muscles are used to maintain the centering of the humeral head. The role of the osteo fibrous coracoacromial arch is to counteract the ascension of the humeral head during arm elevation. Thus, the shape and, particularly, the size of the acromion appears to be an important element of the dynamics of the middle deltoid (Fig. 1).

The radiological analysis is usually done on AP and Y views. Variations in acromial morphology were originally described by Bigliani [16] and classified into three types based on acromial shape: type I, flat; type II, curved; and type III, hooked. However, this classification is not very reproducible and is disturbed when there is ossification of the coracoacromial ligament. Park [17] described a more reliable classification on the same incidence (Fig. 2). On the AP view, it was mainly Nyffeler [14] and Moor [15] who described methods for assessing the lateral extension of the acromion.

Nyffeler [14] has described the acromial index on AP view, tangent the joint and the subacromial space, in neutral rotation (Fig. 3). From a cohort of 102 patients with cuff tears, a matched group with centered omarthrosis and a control group of 70 volunteers without tears or osteoarthritis, the acromial index of patients with cuff tears was shown to be on average 0.73 which is significantly different from the average of patients with osteoarthritis (0.60) and the control group (0.64). However, there was no difference between the control group and the osteoarthritis group.

Later, Moor [15] described the critical shoulder angle (CSA). This is an easy angle to measure (Fig. 3). Inter- and intra-observer reliability was excellent. In the group of 102 cuff tears, the angle is on average 38°, in the 102 centered osteoarthritis, 28.1° and in the control group 33.1°. These three values are significantly different (Fig. 4). In this study, the authors measured many other indexes and the statistical analysis concluded that the CSA was the most powerful predictor of rotator cuff failure. No correlation has been found between this angle and the classic Bigliani and Morison classification.

The CSA appears to be a constitutional element, and not acquired, strongly correlated with the presence of a rotator cuff failure as soon as it exceeds 35°, indicating a significant lateral extension. It is also strongly correlated with the presence of glenohumeral osteoarthritis when it is less than 30°.

The hypothesis that can be put forward is as follows: the

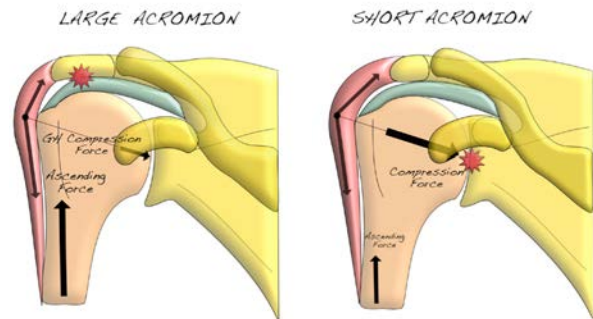


Figure 1: The lateral extension of the acromion appears to be an important element of the dynamics of the middle deltoid

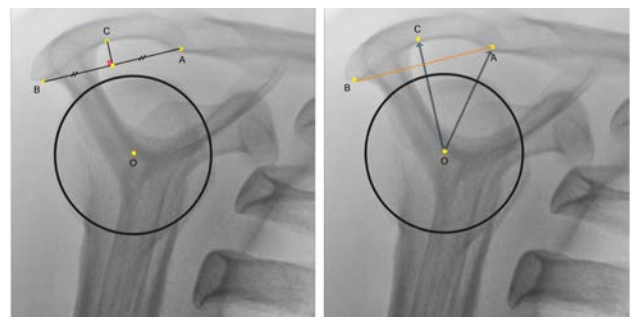


Figure 2: Park classification. O= center of humeral head; B = posterior aspect of the acromion; A= anterior aspect of the acromion. Stage 1: C is on line AB. Stage 2: OA=OC. Stage 3: OA<OC.

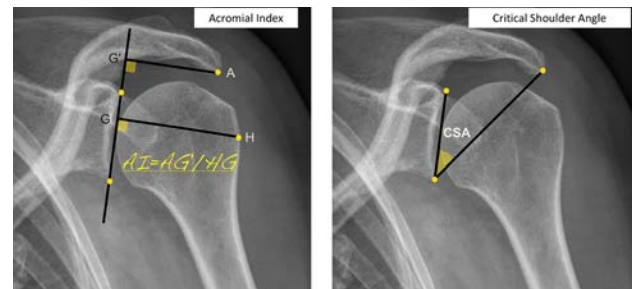


Figure 3: Acromial Index and Critical Shoulder Angle

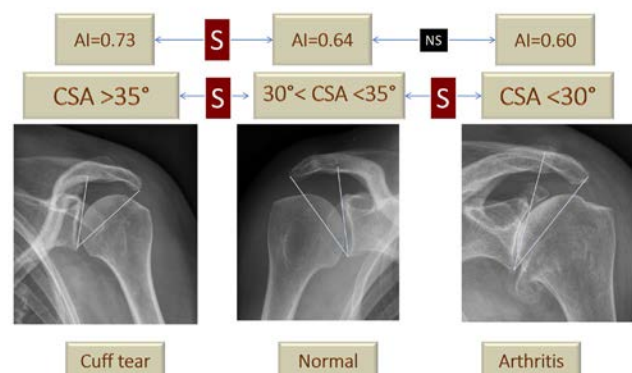

Figure 4: Value of Acromial Index and Critical Shoulder Angle in 3 groups of patients: cuff tears, centered osteoarthritis and control group (normal).

constitutional part of the problem is the extension of lateral acromion. It gives the deltoid a predominant ascending power. The cuff is strained, the head tends to rise, and the arch receives higher stresses responsible for morphological modifications and in particular for a traction entesophyte. Thus, with age, but also with professional constraints, the acromion lengthens and curves. This is

the acquired part of the problem. The contact between the arch and the cuff, which is normally physiological, becomes symptomatic and the acromion may be a cause of impingement against the cuff.

## 1.2 Anatomy and natural history of the rotator cuff disease

In parallel with these concepts, the anatomy of the insertion of the supra- and infraspinatus has been reviewed<sup>[18]</sup>: the footprint of the supraspinatus on the greater tuberosity is much smaller than previously believed, and this area of the greater tuberosity is actually occupied by a substantial amount of the infraspinatus (Fig. 5). By correlating these anatomical data with an ultrasound study, Kim<sup>[19]</sup> was able to specify where the ruptures began. Degenerative rotator cuff tears most commonly involve a location near the junction of the supraspinatus and infraspinatus. This is the junction between the supra and infraspinatus, about 15 mm behind the bicipital groove (Fig. 6). Then the extension is done gradually. For Maman<sup>[20]</sup>, the factors that influence this rate of extension are age (> or < 60 years), full thickness tears, duration of its evolution when it is greater than 18 months and fatty muscle infiltration. Generally speaking, the older the tear is, the more it deteriorates. For Burkhart<sup>[21]</sup>, evolution would be slow and stable as long as the rotator cable remains intact, acting as a suspension bridge and allowing the cuff to maintain a satisfactory humeral head stabilization function.

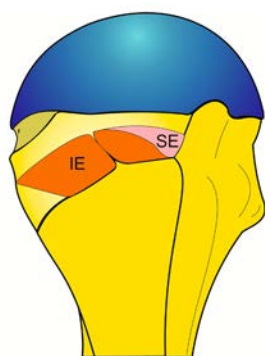


Figure 5: The footprint of the supraspinatus on the greater tuberosity is much smaller than previously believed, and this area of the greater tuberosity is actually occupied by a substantial amount of the infraspinatus.

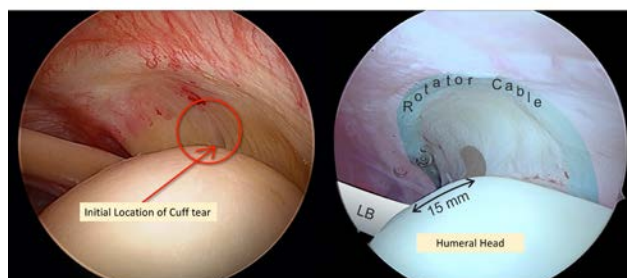


Figure 6: Initial location of cuff tears, 15 mm back to the bicipital groove.

What is the impact of cuff tears on symptomatology?

Mall<sup>[22]</sup> showed that pain development in shoulders with an asymptomatic rotator cuff tear is associated with an increase in tear size. Larger tears are more likely to develop pain in the short term than smaller tears. He also noted that half of these asymptomatic shoulders became symptomatic within 3 years, while the rupture extended.

The impact on the force is seen much later. Halder<sup>[23]</sup> showed that to obtain a significant lack of the elevation force, it was necessary to have a supraspinatus tear extending to the infraspinatus, while a distal tear of the supraspinatus reduced the force by only 1% and an intermediate tear by 11%.

## 1.3 Impact of cuff tears on clinical exam

At the beginning of the rupture, 13 to 17 mm behind the intertubercular groove, and considering Halder's work<sup>[23]</sup>, the test is slightly altered except for the pain. When the supraspinatus is completely ruptured, Jobe's test<sup>[24]</sup> can become positive. However, this test is often painful, which can disrupt the interpretation of the test. When extending to the infraspinatus, there is a lack of strength in the external rotation at side (ER1) test. At this stage, it is useful to look for an external rotation lag sign described by Hertel<sup>[25]</sup>. Then, when the infraspinatus is completely torn, it is frequent to visualize an amyotrophy of the muscle belly. The force in ER1 is significantly reduced. Lastly, when the teres minor muscle is torn, there is a Hornblower's sign<sup>[26]</sup>, or the drop sign in RE2.

If the lesions extend forward, the subscapular muscle is affected. It can be tested by the lift off test described by Gerber<sup>[27]</sup> by the "Belly press test", also described by Gerber in 1996<sup>[27]</sup> and analysed by Tokish<sup>[28]</sup>, or by the Bear Hug test<sup>[30]</sup> which seems to be the most reliable. According to J. Barth<sup>[30]</sup>, this test is the most sensitive for subscapular lesion. These authors evaluated the Bear-hug, Lift off test, Belly press test in 68 patients and verified arthroscopically the involvement of the sub-scapular. They found that in 40% of cases none of the tests detected the subscapular involvement, and that the three tests were specific, but with very variable sensitivity ranging from 17.6% for the lift-off to 60% for the bear-hug test.

When the rupture of the subscapularis is complete and associated to a rupture of the supraspinatus, the risk is the antero-superior instability of the humeral head that escapes anteriorly. The pseudo paralytic shoulder picture is then created, characterized by an active elevation of less than 90°, while passive mobility is normal<sup>[31]</sup>.

## 1.4 Impact of cuff tears on imaging

Hamada<sup>[32]</sup> well analysed the evolution of cuff tears and their impact on subacromial space. The decrease of acromio humeral distance (< 7 mm) only occurs for massive tears and the usual value for pinching is less than 7 mm. Then, it is the progressive evolution towards an "acromiohumeral joint". Regarding muscles, we observe a fatty infiltration, which is secondary to tendon retraction<sup>[33]</sup>. In the event of a tear, the orientation of the muscle fibres changes, with the angulation between the fibres and the fibrous skeleton increasing on average from 30° to 55°. In the space left free by this architectural modification, fat and fibrosis are deposited. Depending on the degree of infiltration, it is possible to establish a gradation that was first described by Goutallier<sup>[34]</sup>, from CT scan. This assessment can also be performed by MRI as described by Fuchs<sup>[35]</sup> (Fig. 7).

- Stage 0 = no fatty infiltration
- Stage 1: some fat stripes
- Stage 2: muscle > fat
- Stage 3: fat = muscle
- Stage 4: fat > muscle.

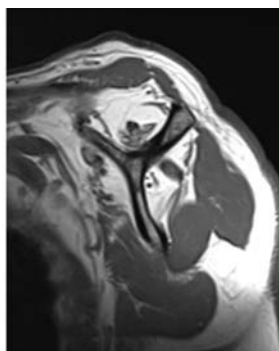
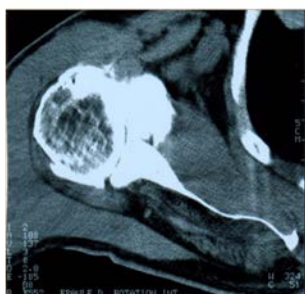

Figure 7: Fatty infiltration stage 4 of infra spinatus on CT scan and MRI.

Muscular atrophy corresponds to the decrease in muscle volume, and is mainly observed at the supraspinatus level, especially on para-sagittal Y view. One of the assessments is the "tangent sign" [36], which has an unfavourable prognostic value. This sign is positive when the muscle body of the supraspinatus does not exceed the line between the spine and the coracoid. This atrophy can also be assessed by the muscle occupancy ratio [37]. For Kim [38], this fatty infiltration is correlated with the size of the tear. In case of partial tear, there is usually no fatty infiltration. For the supraspinatus, fatty infiltration is greater when the rupture reaches the bicipital groove. Fatty infiltration is a major prognostic element of the repair, when it is indicated. Knowing the evolutionary rate of fatty infiltration and atrophy during cuff tears is therefore essential for decision-making and patient advice. The retrospective work of Melis [39] about 1688 cases provides some answers. Thus, in case of a rupture, the average time between the onset of symptoms and the appearance of a fatty infiltration stage 2 is 54 months for the supraspinatus (same time for the appearance of a sign of the tangent), 56 months for the infraspinatus and 36 months for the subscapular, which is therefore more quickly infiltrated. In the case of a traumatic tear, these periods decrease to 35 months for the supraspinatus, 31 months for the infraspinatus and 31 months for the sub-scapular, respectively.

## 1.5 Treatment of cuff tears

In view of these concepts, it is possible to guide the decision-making. In the case of a cuff tear with an acromiohumeral space preserved and a fatty infiltration of the muscles less than or equal to two, it is then possible to consider a surgical repair. In the case of an acromio humeral distance less than 7 mm or a fatty infiltration greater than stage 2, the tear is probably massive and non-repairable.

In any case, it is useful to start with medical treatment based on physiotherapy and infiltration, which often leads to improved symptomatology. If after six months of treatment, there is no improvement, surgical treatment should be considered [40]. In the event of a traumatic injury, surgical treatment is indicated immediately. The same is true for people with subscapular disease, who are often traumatic.

If it is a repairable cuff, the treatment is usually performed under arthroscopy. It consists in reattaching the tendon to the bone using trans osseous sutures or anchors, using various techniques as single or double row sutures. Despite the many studies carried out on the comparison of these techniques, there is currently no formal evidence of the superiority of one technique over another [41].

What is important is to maintain the tendon against the bone for a minimum of six weeks, which is the usual time required for healing.

If the cuff is not repairable and if there is no osteoarthritis (Hamada I and II), several techniques can be considered. For patients who have maintained correct active mobility and whose problem is mainly pain, a simple tenotomy or tenodesis of the long portion of the biceps, a partial repair, the insertion of a balloon in the subacromial space or a superior capsular repair can be considered. There is currently no evidence of the superiority of one technique over the other. For patients who are painful and have lost external rotation, it is advisable to consider a transfer that usually involves latissimus dorsi and sometimes the lower trapezius. For patients who have lost active elevation in relation to a large anterior superior rupture, it is indicated to perform a reverse prosthesis with satisfactory results on function recovery and excellent longevity.

When, in addition to the massive rupture, there is osteoarthritis (Hamada III, IV and V), it is necessary to consider a reverse prosthesis, possibly associated with a transfer of the latissimus dorsi if the infra spinatus and the teres minor are absent.

Lastly, if the benefits of an anterior acromioplasty in the treatment of rotator cuff pathology are not clearly demonstrated, it is reasonable to consider an acromioplasty that reduces the lateral margin of the acromion when the CSA exceeds 35°.

## 2. Shoulder Osteoarthritis

### 2.1 Etiology

Glenohumeral osteoarthritis may be primary or secondary. When it is secondary, there are multiple etiologies: inflammatory diseases, post-traumatic, post-instability, iatrogenic, osteonecrosis, etc. The pathogenesis of primary arthrosis is more complex. Three factors seem to play a major role:

- Acromion plays a definite role as evidenced by the significantly lower CSA in patients with primary osteoarthritis of the shoulder [15].
- The posterior subluxation of the humeral head (whose origin remains poorly understood) present in some patients is responsible for excessive stress on the posterior part of the glenoid, which becomes biconcave corresponding to the different stages, B1, B2 and B3 of the Walch classification [42] (Fig. 8).
- Dysplasia sometimes humeral, most often glenoidal, with a significant retroversion of the glenoid (>25°) corresponding to type C of the Walch classification [42].

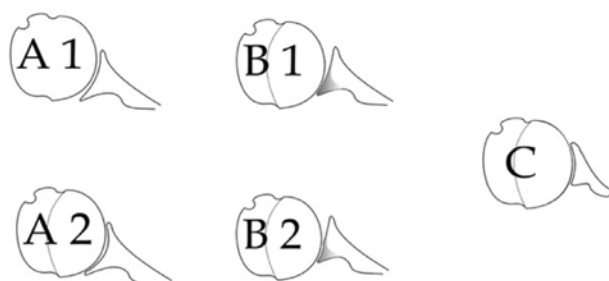


Figure 8: Walch classification of primary osteoarthritis of the shoulder



## 2.2 Treatment

The main annoyance in osteoarthritis is pain and a gradual decrease in mobility. While medical treatment may initially be carried out, sometimes using infiltration, the evolution is usually towards a functional disability such that a surgical solution must be considered. The decision then requires a complete imaging assessment. Today, 3D analysis and virtual implantation of prostheses most often use CT scan of the entire scapula and elbow to get a precise idea of humeral retroversion. This assessment makes it possible to classify osteoarthritis according to Walch's classification<sup>[42]</sup>. It also makes it possible to assess the trophicity of the rotator cuff muscles and their degree of fatty infiltration, which are important factors in the decision-making<sup>[43]</sup>.

In the case of a type A glenoid, an anatomical prosthesis is usually indicated. Hemiarthroplasty can be performed<sup>[44]</sup>. It gives less satisfactory functional results than total prostheses, but their long-term survival is rather good. A better functional result will be obtained with a total anatomical prosthesis. However, these prostheses are exposed to the risk of glenoid loosening and surgical revision, especially after 10 years of follow-up<sup>[45]</sup>.

There are many types of prosthesis. On the humeral side, there are prostheses with long stem, short stem, without stem; the head can be made of metal, ceramic or pyrocarbon. On the glenoid side, it is most often a cemented polyethylene glenoid, but some have a metal back. At the moment, there is no study to prove the superiority of one type of prosthesis over another. The only evidence from studies and registries is a higher risk of surgical revision with metal back glenoids<sup>[46]</sup>. If a cemented polyethylene glenoid is used, the main risk is to ream the subchondral bone, which is one of the glenoid loosening patterns, by subsidence of the prosthesis into the bone vault<sup>[47]</sup>.

In the case of a type B glenoid, the surgical indication is a concern. The retroversion due to wear must be corrected to decrease the risk of posterior subluxation of the head. In type B glenoids, the result of anatomical prostheses is worse than in type A glenoids<sup>[48]</sup>.

The risk of loosening or wear of the PE, by excessive stress on the posterior edge is important. For this reason, in elderly patients, some authors use a reverse prosthesis with satisfactory results<sup>[49]</sup>. Another possibility is to use augmented posterior glenoids but long-term results have not yet been reported. The posterior bone graft does not give good results. The correction of retroversion by excessive reaming on the anterior part weakens the subchondral bone and exposes to the risk of subsidence. Hemiarthroplasties associated with ream and run do not seem to give satisfactory results, exposing to the risk of glenoid wear<sup>[50]</sup>.

If it is a type C glenoid, the problem is even more complex, usually requiring a reverse prosthesis.

Thus, today, there is no consensus on the best technique to use in case of significant posterior subluxation of the humeral head or in glenoidal wear of type B. In any case, a three-dimensional analysis, virtual implantation using appropriate software and the use of patient specific guides are certainly recommended. In borderline cases, the reverse prosthesis is probably a safer solution.

## 3. Elbow osteoarthritis

### 3.1 Introduction

Elbow arthritis is relatively rare<sup>[51]</sup> (about 2% of the general population) and the most common annoyance is pain. The severity of pain, along with the degree of limitation in motion and weakness, guides the treatment. Age and functional status of the patient are also important factors to consider. Treatment has evolved and now includes conservative treatment, open and arthroscopic joint, as well as arthroplasty.

### 3.2 Anatomy

The elbow is a modified hinge joint comprised of three articulations including the ulnotrochlear, radiocapitellar, and proximal radioulnar joints. The proximal ulna provides the major articulation against the distal humerus. Bony stability is provided by the coronoid in flexion and by the olecranon and the radiocapitellar joint in extension. The elbow joint has two degrees of freedom: flexion-extension at the ulnotrochlear joint and pronationsupination through the radiocapitellar joint as well as the proximal and distal radioulnar joints. The normal range of motion approximates 0° of extension to 140° of flexion and 80° of pronation to 85° of supination but functional range of motion of the elbow approximates 30° of extension to 130° of flexion and 50° of pronation to 50° of supination<sup>[52]</sup>.

### 3.3 Etiology

The causes of elbow arthritis include rheumatoid arthritis (RA), posttraumatic arthritis, primary osteoarthritis (OA), septic arthritis, crystalline arthropathy, haemophilia, and ochronosis. The three most common types are RA, posttraumatic arthritis, and primary OA. Patients with RA of the elbow usually complain of pain throughout the arc of motion. Instability may also play a role in elbow dysfunction. Primary OA of the elbow is a disease that is almost exclusive to males, and often associated with heavy manual work<sup>[53]</sup>. The pattern of pain in patients with primary OA is quite different from the one of patients with RA. OA patients classically complain of impingement pain at the extremes of motion, mainly in extension. Posttraumatic arthritis may occur after any traumatic involvement to the elbow. The risk of developing this condition correlates with both the injury pattern and the energy of the injury. Patients complain of pain throughout the arc of elbow motion and instability is rarely a concern.

### 3.4 Clinical assessment

The skin should be inspected to evaluate scars, skin grafts, or areas of fibrosis. Active and passive range of motion should be carefully measured. The end point of restricted motion (soft or hard, painful or painless) and any crepitus should be recorded. Loose bodies may lead to joint "locking" of the elbow. The elbow is inspected for deformation (varus, valgus), and/or rotational instability of the elbow. A complete neurovascular assessment should be performed, with special attention to the ulnar nerve, which is frequently associated with elbow OA. Electrodiagnostic studies may be necessary, if the assessment of nerve irritability is positive.



## 3.5 Radiographic Evaluation

Anteroposterior, lateral with the elbow flexed at 90° are obtained as a routine and provide adequate information but computed tomography with two- and three-dimensional reconstructions is helpful for surgical planning of joint debridement. Radiographic findings typical for RA include symmetric joint space narrowing, periarticular erosions, and osteopenia. In contrast, some preservation of the ulnohumeral and radiocapitellar joint spaces is common in elbows with primary osteoarthritis. Radiographs reveal osteophyte and loose body formation. Rettig<sup>[54]</sup> developed a new radiographic classification system with three classes or levels of severity, to predict outcomes after debridement of elbow osteoarthritis.

## 3.6 Treatment

### • Non-operative Treatments

If not medically contraindicated, patients should be prescribed analgesic or anti-inflammatory drugs (NSAIDs). Intra-articular steroid or hyaluronic injections acid can be very effective<sup>[55]</sup>. Physical therapy is important for the maintenance of elbow range of motion. Patients are advised to use some combination of modalities as activity modification, hinge braces, night splint, etc.

### • Operative treatments

#### Arthrodesis

Nowadays elbow arthrodesis is rarely indicated and most often performed as a salvage operation.

#### Synovectomy

Open or arthroscopic synovectomy, with or without radial head excision, is an established treatment option for patients with rheumatoid arthritis. The primary goal of synovectomy is to provide pain relief and prevent destruction of the elbow joint<sup>[56]</sup>. The advantages of arthroscopic synovectomy include improved enhanced visualization, decreased morbidity, and shorter rehabilitation<sup>[57]</sup>. Conjunction with current biologic disease-modifying antirheumatic drugs is essential to maintain outcomes in patients after arthroscopic synovectomy.

#### Debridement

This surgery is referred to as the Outerbridge- Kashiwagi (OK) procedure<sup>[58]</sup>. This surgery is indicated in those patients with primary OA who have continuous pain at the extremes of motion and radiographic evidence of impingement. Arthroscopic debridement and loose body excision is limited to patients with degenerative arthritis and clinical symptoms of impingement pain, limited motion, and intermittent mechanical locking.

#### Interposition arthroplasty

Arthroplasty by interposition of an Achilles tendon allograft<sup>[59]</sup> may be indicated in young, active patients where total elbow prosthesis is contra-indicated, with severe inflammatory arthritis or posttraumatic arthritis, especially those with limited elbow motion. However, elbow instability is the major complication.

## Total elbow arthroplasty (TEA)

TEA is indicated for patients older than 65 years of age who have considerable pain, limited motion, and functional deficit and for whom non-operative interventions have failed. There are different prosthesis designs that are generally grouped as unconstrained, semi-constrained, and constrained. Constrained designs lead to a loosening at the cement-bone interface<sup>[60]</sup>. Non-constrained designs lead to a significant risk of instability. In fact, elbow instability is now considered to be a contraindication for unconstrained TEA. A semi-constrained design attempts to create a solution between constrained and unconstrained TEA. Global survival rate in TEA is between 80% to 90% at ten years with aseptic loosening and infection being the main complications requiring revision<sup>[61]</sup>.

## References:

1. Milgrom C, Schaffler M, Gilbert S, van Holsbeeck M. Rotator-cuff changes in asymptomatic adults. The effect of age, hand dominance and gender. *J Bone Joint Surg. Br* 1995; 77: 296-298.
2. Sher JS, Uribe JW, Posada A, Murphy BJ, Zlatkin MB. Abnormal findings on magnetic resonance images of asymptomatic shoulders. *J Bone Joint Surg. Am* 1995; 77: 10-15.
3. Moosmayer S, Smith HJ, Tariq R, Larmo A. Prevalence and characteristics of asymptomatic tears of the rotator cuff: an ultrasonographic and clinical study. *J Bone Joint Surg. Br* 2009; 91: 196-200.
4. Yamamoto A, Takagishi K, Osawa T, et al: Prevalence and risk factors of a rotator cuff tear in the general population. *J Shoulder Elbow Surg* 2010; 19: 116-120,
5. Neer CS: 2nd Impingement lesions. *Clin Orthop Relat Res* 173:70-77, 1983
6. Bigliani LU, Ticker JB, Flatow EL, Soslowsky LJ, Mow VC. The relationship of acromial architecture to rotator cuff disease. *Clin Sports Med*. 1991; 10:823-38.
7. Lohr JF, Uhthoff HK: The microvascular pattern of the supraspinatus tendon. *Clin Orthop Relat Res* 1990; 254: 35-38.
8. Tashjian, R.Z., Epidemiology, natural history, and indications for treatment of rotator cuff tears. *Clin Sports Med*, 2012; 31: 589-604.
9. Bigliani LU, Levine WN: Subacromial impingement syndrome. *J Bone Joint Surg Am* 1997; 12: 1854-1868.
10. Vitale MA, Arons RR, Hurwitz S, Ahmad CS, Levine WN. The rising incidence of acromioplasty. *J Bone Joint Surg. Am* 2010; 9:1842-1850.
11. Henkus HE, de Witte PB, Nelissen RG, Brand R, van Arkel ER: Bursectomy compared with acromioplasty in the management of subacromial impingement syndrome: A prospective randomised study. *J Bone Joint Surg Br* 2009; 4: 504-510.
12. Gartsman GM, O'Connor DP: Arthroscopic rotator cuff repair with and without arthroscopic subacromial decompression: A prospective, randomized study of one-year outcomes. *J Shoulder Elbow Surg* 2004; 4: 424-426.
13. Shin SJ, Oh JH, Chung SW, Song MH. The efficacy of acromioplasty in the arthroscopic repair of small- to medium-sized rotator cuff tears without acromial spur: prospective comparative study. *Arthroscopy*. 2012; 5: 628-35.

14. Nyffeler RW, Werner CM, Sukthankar A, Schmid MR, Gerber C. Association of a large lateral extension of the acromion with rotator cuff tears. *J Bone Joint Surg Am* 2006; 88: 800-5.
15. Moor BK, Bouaicha S, Rothenfluh DA, Sukthankar A, Gerber C. Is there an association between the individual anatomy of the scapula and the development of rotator cuff tears or osteoarthritis of the glenohumeral joint? A radiological study of the critical shoulder angle. *Bone Joint J* 2013; 95:9 35-41.
16. Bigliani BU, Morrison ES, April EW: The morphology of the acromion and its relationship to rotator cuff tears. *Orthop Trans* 1986; 10: 216.
17. Park TS, Park DW, Kim SI, Kweon TH. Roentgenographic assessment of acromial morphology using supraspinatus outlet radiographs. *Arthroscopy*. 2001; 5: 496-501.
18. Mochizuki T, Sugaya H, Uomizu M, Maeda K, Matsuki K, Sekiya I, Muneta T, Akita, K. Humeral insertion of the supraspinatus and infraspinatus. New anatomical findings regarding the footprint of the rotator cuff. *J Bone Joint Surg Am*. 2008; 5:962-9.
19. Kim HM, Dahiya N, Teefey SA, Middleton WD, Stobbs G, Steger-May K, Yamaguchi K, Keener JD. Location and initiation of degenerative rotator cuff tears: an analysis of three hundred and sixty shoulders. *J Bone Joint Surg. Am* 2010; 92: 1088-1096.
20. Maman E, Harris C, White L, Tomlinson G, Shashank M, Boynton E. Outcome of nonoperative treatment of symptomatic rotator cuff tears monitored by magnetic resonance imaging. *J Bone Joint Surg. Am* 2009; 91: 1898-1906.
21. Burkhart SS, Esch JC, Jolson RS. The rotator crescent and rotator cable: an anatomic description of the shoulder's "suspension bridge". *Arthroscopy* 1993; 9: 611-616.
22. Mall NA, Kim HM, Keener JD, Steger-May K, Teefey SA, Middleton WD, Stobbs G, Yamaguchi K. Symptomatic progression of asymptomatic rotator cuff tears: a prospective study of clinical and sonographic variables. *J Bone Joint Surg. Am* 2010; 92: 2623-2633.
23. Halder AM, O'Driscoll SW, Heers G, Mura N, Zobitz ME, An KN, Kreuzsch-Brinker R. Biomechanical comparison of effects of supraspinatus tendon detachments, tendon defects, and muscle retractions. *J Bone Joint Surg. Am* 2002; 84: 780-785.
24. Jobe FW, Jobe CM. Painful athletic injuries of the shoulder. *Clin Orthop*. 1983;117-24.
25. Hertel R, Ballmer FT, Lombert SM, Gerber C. Lag signs in the diagnosis of rotator cuff rupture. *J Shoulder Elbow Surg*. 1996; 5: 307-13.
26. Walch G, Boulahia A, Calderone S, Robinson AH. The 'dropping' and 'hornblower's' signs in evaluation of rotator-cuff tears. *J Bone Joint Surg Br*. 1998; 80: 624-8.
27. Gerber C, Krushell RJ. Isolated rupture of the tendon of the subscapularis muscle. Clinical features in 16 cases. *J Bone Joint Surg Br*. 1991; 73: 389-94.
28. Gerber C, Hersche O, Farron A. Isolated rupture of the subscapularis tendon. *J Bone Joint Surg Am*. 1996; 78: 1015-23.
29. Tokish JM, Decker MJ, Ellis HB, Torry MR, Hawkins RJ. The belly-press test for the physical examination of the subscapularis muscle: electromyographic validation and comparison to the lift-off test. *J Shoulder Elbow Surg*. 2003; 12: 427-30.
30. Barth JR, Burkhart SS, De Beer JF. The bear-hug test: a new and sensitive test for diagnosing a subscapularis tear. *Arthroscopy*. 2006; 22: 1076-84.
31. Collin P, Matsumura N, Lädermann A, Denard PJ, Walch G. Relationship between massive chronic rotator cuff tear pattern and loss of active shoulder range of motion. *J Shoulder Elbow Surg*. 2014; 8: 1195-202.
32. Hamada K, Fukuda H, Mikasa M, Kobayashi Y. Roentgenographic findings in massive rotator cuff tears. A long-term observation. *Clin Orthop*. 1990; 92-6.
33. Gerber C, Meyer DC, Frey E, von Rechenberg B, Hoppeler H, Frigg R, et al. Neer Award 2007: Reversion of structural muscle changes caused by chronic rotator cuff tears using continuous musculotendinous traction. An experimental study in sheep. *J Shoulder Elbow Surg*. 2009; 18: 163-71.
34. Goutallier D, Postel JM, Bernageau J, Lavau L, Voisin MC. Fatty muscle degeneration in cuff ruptures. Pre- and postoperative evaluation by CT scan. *Clin Orthop*. 1994; 304: 78-83.
35. Fuchs B, Weishaupt D, Zanetti M, Hodler J, Gerber C. Fatty degeneration of the muscles of the rotator cuff: assessment by computed tomography versus magnetic resonance imaging. *J Shoulder Elbow Surg*. 1999; 8: 599-605.
36. Zanetti M, Gerber C, Hodler J. Quantitative assessment of the muscles of the rotator cuff with magnetic resonance imaging. *Investigative radiology*. 1998; 33: 163-70.
37. Thomazeau H, Rolland Y, Lucas C, Duval JM, Langlais F. Atrophy of the supraspinatus belly. Assessment by MRI in 55 patients with rotator cuff pathology. *Acta Orthop Scan*. 1996; 67: 264-8.
38. Kim HM, Dahiya N, Teefey SA, Keener JD, Galatz LM, Yamaguchi K. Relationship of tear size and location to fatty degeneration of the rotator cuff. *J Bone Joint Surg Am*. 2010; 92: 829-39.
39. Melis B, DeFranco MJ, Chuinard C, Walch G. Natural history of fatty infiltration and atrophy of the supraspinatus muscle in rotator cuff tears. *Clin Orthop*. 2010; 468: 1498-505.
40. Agout C, Berhouet J, Spiry C, Bonneville N, Joudet T, Favard L; French Arthroscopic Society. Functional outcomes after non-operative treatment of irreparable massive rotator cuff tears: Prospective multicenter study in 68 patients. *Orthop Traumatol Surg Res*. 2018; 104: 189-192.
41. McElvany, M.D., et al., Rotator cuff repair: published evidence on factors associated with repair integrity and clinical outcome. *Am J Sports Med*, 2015; 2: 491-500.
42. Walch, G., et al., Morphologic study of the glenoid in primary glenohumeral osteoarthritis. *J Arthroplasty*, 1999; 6: 756-60.
43. Patrick J, Denard, MD, Gilles Walch, MD. Current concepts in the surgical management of primary glenohumeral arthritis with a biconcave glenoid. *J Shoulder Elbow Surg*. 2013; 22: 1589-1598.
44. Levine WN, Fischer CR, Nguyen D, Flatow EL, Ahmad CS, Bigliani LU: Long-term follow-up of shoulder hemiarthroplasty for glenohumeral osteoarthritis. *J Bone Joint Surg* 2012; 22: e164.
45. Young A, Walch G, Boileau P, Favard L, Gohlke F, Loew M, et al. A multicenter study of the long-term results of using a flat-back polyethylene glenoid component in shoulder replacement for primary osteoarthritis. *J Bone Joint Surg Br* 2011; 93: 210-6.
46. Page RS, Pai V, Eng K, Bain G, Graves S, Lorimer M. Cementless versus cemented glenoid components in conventional total shoulder joint arthroplasty: analysis from the Australian Orthopaedic Association National Joint Replacement Registry. *J Shoulder Elbow Surg*. 2018; 10:1859-1865.

47. Walch G, Young AA, Boileau P, Loew M, Gazielly D, Molé D. Patterns of loosening of polyethylene keeled glenoid components after shoulder arthroplasty for primary osteoarthritis: results of a multicenter study with more than five years of follow-up. *J Bone Joint Surg Am.* 2012; 2:145-50.
48. Walch G, Moraga C, Young A, Castellanos-Rosas J. Results of anatomic nonconstrained prosthesis in primary osteoarthritis with biconcave glenoid. *J Shoulder Elbow Surg* 2012; 21: 1526-33.
49. Mizuno N, Raiss P, Denard PJ, Walch G. Reverse total shoulder arthroplasty for primary glenohumeral osteoarthritis with a biconcave glenoid. *J Bone Joint Surg Am* 2013; 14: 1297-304.
50. Gilmer BB, Comstock BA, Jette JL, Warme WJ, Jackins SE, Matsen FA. The prognosis for improvement in comfort and function after the ream-and-run arthroplasty for glenohumeral arthritis: an analysis of 176 consecutive cases. *J Bone Joint Surg* 2012; 18:e102.
51. Ortner, D.J., Description and classification of degenerative bone changes in the distal joint surfaces of the humerus. *Am J Phys Anthropol*, 1968; 2: 139-55.
52. Morrey BF, Askew LJ, An KN, and Chao EY. A biomechanical study of normal functional elbow motion. *J Bone Joint Surg.* 1981; 6: 872-7.
53. Stanley, D., Prevalence and etiology of symptomatic elbow osteoarthritis. *J Shoulder Elbow Surg.* 1994; 6: 386-9.
54. Rettig LA, Hastings H II, Feinberg JR. Primary osteoarthritis of the elbow: lack of radiographic evidence for morphologic predisposition, results of operative debridement at intermediate follow-up, and basis for a new radiographic classification system. *J Shoulder Elbow Surg* 2008; 17: 97-105.
55. Van Brakel, R.W. and D. Eygendaal, Intra-articular injection of hyaluronic acid is not effective for the treatment of posttraumatic osteoarthritis of the elbow. *Arthroscopy*, 2006; 11: 1199-1203.
56. Fuerst M, Fink B, Rüther W. Survival analysis and long-term results of elbow synovectomy in rheumatoid arthritis. *J Rheumatol* 2006; 33: 892-896.
57. Tanaka N, Sakahashi H, Hirose K, Ishima T, Ishii S. Arthroscopic and open synovectomy of the elbow in rheumatoid arthritis. *J Bone Joint Surg* 2006; 88: 521-525.
58. Kashiwagi D. Intra-articular changes of the osteoarthritic elbow, especially about the fossa olecrani. *Japan Orthop Assoc.* 1978; 52:1367-72.
59. Larson AN, Morrey BF. Interposition arthroplasty with an Achilles tendon allograft as a salvage procedure for the elbow. *J Bone Joint Surg* 2008; 90: 2714-2723.
60. Morrey BF, Bryan RS. Complications of total elbow arthroplasty. *Clin Orthop Rel Res.* 1982;170: 204-12.
61. Fevang, B.T., et al., Results after 562 total elbow replacements: a report from the Norwegian Arthroplasty Register. *J Shoulder Elbow Surg*, 2009. 3: 449-56.

## Questions

1. Which of the following is a risk factor for cuff tear?
  - a. CSA <30°
  - b. CSA > 35°
  - c. Retroversion of the glenoid
  - d. Short lateral extension of the acromion
  - e. Acromion bi partita
2. What is the main reason for a pseudo paralytic shoulder?
  - a. Infra spinatus tear
  - b. Infra spinatus and teres minor tear
  - c. Supra, infra spinatus and teres minor tear
  - d. Sub scapularis tear
  - e. Subscapularis and supra spinatus tear
3. What is the best treatment for a woman 80 y.o., with a primary osteoarthritis and a glenoid B2?
  - a. Hemiarthroplasty
  - b. Anatomical shoulder arthroplasty with bone graft
  - c. Reverse shoulder arthroplasty
  - d. Hemiarthroplasty with ream and run of the glenoid
  - e. Gleno humeral arthrodesis
4. Which of following is not possible to do under arthroscopy for elbow arthritis
  - a. Loose bodies removal
  - b. Capsular release
  - c. Osteophytes resection
  - d. Interposition arthroplasty
  - e. Synovectomy

## Answers

1b, 2e, 3c, 4d.



*Dr. Simone Cerciello*  
Casa Di Cura Villa Betania – Rome, Italy  
Policlinico Universitario Fondazione Agostino Gemelli – Rome, Italy  
simone.cerciello@me.com

*Prof. Philippe Neyret*  
Burjeel Orthopaedics and Sports Medicine Center – Abu Dhabi, UAE  
philippe.neyret01@gmail.com

*Dr. Dario Candura*  
Policlinico Universitario Fondazione Agostino Gemelli – Rome, Italy  
dariocandura11@gmail.com

## Knee Ligaments & Meniscii

### Abstract

Meniscal and ligament injuries are commonly encountered in orthopedic practice. Since they may result in functional impairment with mid and long-term consequences, the pathologic anatomy should be carefully evaluated. Medial and lateral meniscii are mainly load transducers. Tears can be either traumatic or degenerative. Since they have reduced healing potential, torn parts meniscii are usually removed trying to preserve the healthy portions in order to avoid late cartilage degeneration. Anterior cruciate ligament (ACL) injuries commonly follow sport traumas. ACL controls anterior tibial translation and pivot. When it is insufficient, knee stability is severely affected and it should be therefore reconstructed. Great care should be taken to reproduce original ligament insertions in order to re-establish its normal biomechanics and ensure knee stability. Posterior cruciate ligament (PCL) is thicker and stronger than ACL. As a consequence, it is usually injured in high-energy traumas such as motor vehicle accidents. In case of minor anatomic damage, residual instability is generally limited and conservative treatment with immobilization and further rehabilitation is still indicated. When major instability is present, PCL reconstruction should be performed as well as the reconstruction of any peripheral ligament damage. Medial collateral ligament (MCL) is the major restraint to valgus stress. It is usually affected in the setting of multi-ligament injuries. Isolated acute lesions are generally treated with immobilization and further rehabilitation. Isolated chronic tears or MCL lesions associated with ACL or PCL ruptures require surgical reinsertion or reconstruction.

### 1 Meniscii

#### 1.1 Introduction

The prevalence of meniscal tears is approximately 12% to 14%, with an approximate incidence of 61 cases in every 100000 people [Enkhmaa Luvsannyam 2022]. Similarly, around 1 million knee arthroscopies are performed for meniscal problems in the United States of America (USA) annually [Cook 2005], and arthroscopic meniscal debridement is the most common procedure logged during part II board certification [Garrett 2006].

#### 1.2 Anatomy and function

The menisci are wedge shaped fibrocartilagenous structures located between the femoral condyles and tibial plateau. The medial meniscus is "U" shaped covering around 60% of the medial compartment whereas the lateral meniscus is more "C" with a shorter distance between its anterior and posterior horns covering 80% of the lateral compartment. Meniscal tissue consists mainly of water and type I collagen fibres [Simon C Mordecai 2014]. Both have poor blood supply, which is responsible for the reduced healing potential before and after repair surgery. Supply comes from the periphery via the medial and lateral geniculate arteries, however only the peripheral 10%-25% of the meniscus benefits from a blood supply [Arnoczky 1982]. On the contrary, nerve supply is rich in mechanoreceptors and free nerve endings. The concentration is higher in the peripheral two-thirds, with the peak in the posterior horns of both meniscii [Assimakopoulos 1992]. This suggests that the menisci may have a role in proprioception, stability and protective reflexes. The meniscii play an important role in knee function and biomechanics as load transducers (50% of the body weight in extension and up to 85-90% in flexion [Ahmed 1983], and contribute to stability and joint lubrication as well. The role in joint stability becomes critical in anterior cruciate ligament (ACL) deficient knees.

#### 1.3 Classification of meniscus injuries

Meniscal tears are traditionally considered traumatic or degenerative, referring to their onset. Currently, this classification is based on medical history, trauma mechanism, patient age, and magnetic resonance imaging indicating a specific tear pattern. Classifying meniscal tears into traumatic versus degenerative tears can, however, be challenging, as there is no consensus on how exactly to define degenerative and traumatic tears. In some cases, traumatic tears are caused by a very minor trauma (eg, walking stairs); in other cases, degenerative tears are incidentally found in asymptomatic healthy knees. Moreover, studies have shown that traumatic meniscal tears may result from early degenerative disease processes. Thus, differentiation between these types is not as straightforward as it may seem [Marinus A. Wesdop 2020]. Degenerative and chronic tears have been defined as slowly developing lesions, typically involving a horizontal cleavage of the posterior horn of the medial meniscus in a middle-aged or older person. They are usually asymptomatic and their prevalence increases with age, ranging from 16% in the knees of women aged 50 to 59 years to over 50% in the knees of



men aged 70 to 90 years [Englund 2008]. Since they have low/no healing potential, they should be treated non-surgically if possible or with meniscectomy if required. However, since meniscectomy has important consequences on loads distribution it should be carefully evaluated. Total medial meniscectomy decreases tibio-femoral contact area by 75% and increases peak contact pressure by approximately 235% [Baratz 1986]. Acute/traumatic tears are often classified according to their orientation and stability/instability. They can be vertical longitudinal, vertical radial, horizontal, oblique or complex [Binfield 1993]. Longitudinal tears are more common medially, whereas radial tears are more frequently seen laterally [Klimckiewicz 2002]. Traumatic tears can also be defined as 'stable' or 'unstable' according to their mobility. In stable knees (intact ACL), the rate of post-traumatic meniscal tears is 6% [Maffulli 1993]; the rate is much higher in ACL deficient knees [Gadeyne 2006] and continues to increase along with time. More recently ramp and root lesions of the menisci has been widely re-considered. Ramp lesions of the medial meniscus affect the menisco-capsular junction and induce anterior instability in ACL-deficient cadaveric knees as well as internal and external [Peltier 2015] rotation laxity at all knee flexion angles. Root tears of the menisci have been defined as lesions of the menisci within 1cm to the root insertion. They reduce translational and rotational stability of the knee in both ACL-intact and ACL-deficient conditions [Chen 2015] and increase tibiofemoral contact pressures equal to those following a total meniscectomy. Their repair restores contact pressure to that of the uninjured knee [Allaire 2008].

## 1.4 Treatment options

The contribution of the meniscii in joint stability and biomechanics is well established and influences treatment options.

### a) Conservative treatment

According to the results of recent systematic reviews and meta analyses, conservative treatment should be the first option in chronic/degenerative lesions [Elattrache 2014, Thorlund 2015, Bollen 2015]. It consists of rehabilitation and exercise programmes to improve muscle strength, flexibility and proprioception. Noorduyn et Al., in a randomized controlled trial, compared partial meniscectomy with physical therapy consisting of a supervised incremental

exercise protocol of 16 sessions over 8 weeks. The main outcome measure was the Dutch-language equivalent of the Patient-Specific Functional Scale (PSFS), a secondary outcome measure of the ESCAPE trial. They used crude and adjusted linear mixed-model analyses to reveal the between-group differences over 24 months. Both interventions were associated with a clinically meaningful improvement regarding patients' most important functional limitations. Although partial meniscectomy was associated with a statistically larger improvement at some follow-up time points, the difference compared with physical therapy was small and clinically not meaningful at any follow-up time point. [Noorduyn 2020] Yim et al. compared the outcomes of meniscectomy and non-operative strengthening exercises in patients with degenerative horizontal tears of the posterior horn of the medial meniscus. Satisfactory clinical results were found in each group at 2 years FU with no significant difference in terms of pain, function and patient satisfaction [Yim 2013]. Similar outcomes were reported in a multicentre randomised controlled study on 351 patients over 45 years of age with a meniscal tear and evidence of osteoarthritis [Katz 2013]. At 12 months FU,

no significant differences were found in terms of improvement in functional status and pain between the partial meniscectomy and physical therapy alone. However, there was crossover from the physical therapy group to the surgery group in 35% of patients. Functional outcomes in this cohort of patients at 12 months FU were similar to those patients who had surgery initially. This data confirms, that non-operative treatment is a reasonable first line approach in middle-aged patients with degenerative meniscal tears. Conservative treatment is a reasonable option even in case of traumatic tears; in stable knees, subjective results are good at more than 10 year FU and 85% of patients consider their knee as normal or nearly normal [Chatain 2003]. On the contrary, in ACL-deficient knees, isolated meniscectomy has a dramatic negative impact on knee function with almost 100% osteoarthritis rate at more than 30 years [Neyret 1993]. Clinical outcomes are usually better on the medial side, while they quickly deteriorate on the lateral compartment [Chatain 2003]. The difference is confirmed by the re-arthroscopy rate, which is 14% after lateral meniscectomy and 6% after medial meniscectomy and by the prevalence of joint-line narrowing which is 22% on the medial side and 38% on the lateral side, at more than ten-years FU [Chatain 2003]. The rate of arthritis at 20 years FU is 56% in a specific population after lateral meniscectomies [Hulet 2015]. This is due to the convexity of lateral tibial plateau that mirrors the convexity of the distal femoral condyle. In the absence of a meniscus there is greater tendency to point loading.

### b) Partial meniscectomy

Partial meniscectomy is indicated in case of acute tears in the avascular zone of both meniscii with a radial, oblique and flap configuration. In addition, degenerative lesions non-responding to conservative treatment can be addressed with arthroscopic selective meniscectomy. The aim of the procedure is to debride the loose nonviable edges of meniscii in order to keep a stable meniscus. The extent of the debridement should be predetermined, and should allow the removal of the damaged and unstable portion of the meniscus while preserving as much of the normal meniscus and its structural integrity as possible. It is particularly important to preserve the periphery of the meniscus, and the junction between the meniscus and capsule. This maintains the integrity of the hoop stresses in the meniscus, which are vital for cartilage preservation. The goal is to remove the damaged meniscal tissue, leaving a stable peripheral rim.[Weiss 2014]The outcomes are generally very positive in terms of functional recovery and pain relief. The outcomes of partial meniscectomy are superior to those of complete resection as reported by Northmore-Ball et al. [Northmore Ball 1983]. In a cohort of 219 knees at 4.3 years FU they reported 90% of patients having either good or excellent satisfaction following arthroscopic partial meniscectomy compared to only 68% in the cohort of open total meniscectomy. Similar data have been reported by Burks et al. who had good or excellent results in 88% of patients [Burks 1997] and by Jaureguito et al. who reported 90% of good or excellent results and 85% of patients resuming pre-injury level of activities at 2 years FU [Jaureguito 1995]. However it is now clear that partial meniscectomy may delay degeneration but not prevent it, and functional outcomes usually decrease along with time. In a study involving 147 athletes, they were reviewed at 4.5 years and then at 14 years [Faunø 1992]. Almost half of patients were asymptomatic at first FU, while only one third was still asymptomatic at last control and 46% had given up or reduced their sporting activity. Conversely the incidence of

radiographic changes rose from 40% to 89%. Similar data were reported in a series of 136 patients treated with partial meniscectomy [Jørgensen 1987]. At 8.5 years there was a re-operation of 22.8% and 53% of patients had osteoarthritic radiographic changes compared to only 22% in the unaffected control knee. Radiographic degeneration is usually more common after lateral meniscectomy than medial and the outcomes are generally inferior when some extent of articular cartilage damage pre-exists in surgery.

## c) Meniscal repair

Traumatic and acute tears have a great healing potential: they are suitable to repair if the geometry of the lesion allows it. Blood supply is crucial to ensure tissue healing and only tears in the red-red or at least in the red-white zone (up to approximately 5 mm from periphery) have the potential to heal. Therefore, healing stimulating adjuvants such as exogenous fibrin clots have been used to enhance the reparative response in the avascular/ partially vascular zones [VanTrommel 1998]. Traditionally, the best indication for meniscal repair is longitudinal tear in a stable knee. ACL deficiency greatly affects meniscal healing potential. Positive results have also been reported in case of radial tears [Boyd 2003]. These tears cause disruption of all the longitudinal fibres and complete loss of meniscus function, if they extend to the peripheral zone. Therefore, radial tears of the red and red-white zones should be repaired in order to restore integrity of the rim [Ra 2013]. Meniscal repair can be performed open or under arthroscopy. Arthroscopic inside-out and outside-in techniques are useful for anterior and middle third tears, which are not easily accessed by an all-inside technique. More recently all-inside arthroscopic meniscal repair techniques have been proposed in lesions of the posterior aspect of the meniscus to avoid the need for accessory incisions. The outcomes of both treatment options are encouraging, however the complication rate is not negligible. In a recent systematic review by Nepple et al, on 27 studies with a minimum of five-year FU, a pooled overall failure rate was 22.6%, while the failure rate of modern repairs (excluding early-generation all-inside devices) was 19.5%. Medial repairs were significantly more likely to fail compared with lateral repairs (23.9% versus 12.6%,  $p = 0.04$ ). [Nepple 2022] More nerve symptoms are generally associated with the inside-out repair, while more implant-related complications are associated with the all-inside techniques.

## 2 Anterior Cruciate Ligament

### 2.1 Introduction

Anterior cruciate ligament (ACL) injuries are common in contact sports (such as soccer, rugby and basketball) and in activities requiring pivoting movements (such as skiing). Reported annual incidence is 68.6 per 100,000 person-years, representing the most common ligament injury [Thomas L. Sanders 2016]. ACL insufficiency has a dramatic impact on knee function, leading to additional anatomic damages such as meniscal tears, chondral lesions and an increased risk of early onset post-traumatic osteoarthritis (OA) at long-term FU [Levine 2013]. Since the ACL has poor healing capacity, surgery is often indicated.

### 2.2 Anatomy and function

The ACL is an intra-articular, yet extra-synovial structure formed by two bundles: the antero-medial and the postero-lateral. The AM bundle is anterior and medial to the PL bundle. Both the AM bundle and the PL bundle likely have independent roles in providing stability to the knee. The whole ACL is the major restraint to anterior tibial translation (accounting for about 86% of the total resistance) and to tibial internal and external rotation relative to the femur [Butler 1980].

More than 70% of ACL injuries are the result of non-contact sports (without a direct trauma on the knee joint) involving combined valgus and varus movements associated with tibial internal and external rotation [Quatman 2014]. In addition it has been showed that neuromuscular control deficit has a crucial influence on ACL injury risk [Hewett 2013].

### 2.3 Treatment options

Conservative treatment is unsatisfactory with residual instability and pain. Similarly, primary repair of ACL is ineffective with persistent symptoms in more than 90% of patients at 5 years FU [Feagin 1976]. When the outcomes of primary repair were compared to those of conservative treatment, they were similar with high rates (40% to 100%) of ACL healing failure [Sandeberg 1987]. According to these evidences surgical reconstruction has emerged as the golden standard in ACL deficient knees. ACL reconstruction is a satisfactory procedure, however, persistent instability has been reported in 10%-30% of patients with a return-to-sport rate of only 60% to 70% after single bundle reconstruction [Prodomos 2008]. Conservative treatment is unsatisfactory with residual instability and pain. Similarly, primary repair of ACL is ineffective with persistent symptoms in more than 90% of patients at 5 years FU [Feagin 1976]. When the outcomes of primary repair were compared to those of conservative treatment, they were similar with high rates (40% to 100%) of ACL healing failure [Sandeberg 1987]. According to these evidences surgical reconstruction has emerged as the golden standard in ACL deficient knees. ACL reconstruction is a satisfactory procedure, however, persistent instability has been reported in 10%-30% of patients with a return-to-sport rate of only 60% to 70% after single bundle reconstruction [Prodomos 2008]. In a recent systematic review, Westin et Al., reported on 1149 patients who underwent ACL reconstruction and participated in high-risk sports before their injury, 994 (80%) returned to these activities postoperatively. Overall, 1 in 5 patients sustained a reinjury to either knee, 90% of which occurred while participating in high-risk sports[Sue Barber Westin].

#### a) Femoral tunnel placement

The femoral tunnel placement is crucial to restore normal joint kinematics [Abebe 2011]. The initial trans-tibial technique for femoral tunnel placement was a reproducible option but had the drawback of more vertical tunnel positioning and, tibial and femoral tunnels were dependent each other. Antero-medial technique is more anatomic and has the advantage of independent tunnels, however it is more technically demanding, especially in terms of femoral visualization when the knee is in deep flexion. Out-in technique is a reliable option and allows great freedom when positioning the articular end of the femoral tunnel.

## b) Graft choice

Most common autografts are hamstrings (HS), patellar tendon (PT) and quadriceps tendon (QT). Both PT and HS result in a functionally stable knee in more than 95% of surgeries with similar graft failure rate. PT graft has good structural fixation properties, and has the potential for tendon-to-bone healing [Aune 2001]. Drawbacks include anterior knee pain, extensor quadriceps weakness and possible patellar complications [Freedmann 2003]. HS are variable in terms of length and diameter. Although postoperative recovery is usually easier than PT and equally tensioned 4 strands, HS withstands much greater tension strains than a 10-mm PT graft [Tuman 2007], a recent meta-analysis revealed it has higher side to-side difference than PT at the KT-1000 testing [Freedmann 2003]. QT resulted in similar functional outcomes and stability as PT but lower donor-site morbidity. Donor-site morbidity is a concern for some surgeons with PT in ACL reconstruction, and QT results in reduced anterior knee pain and numbness [Eoghan T. Hurley 2018]. Allografts have several advantages over autografts including no donor-site morbidity, reduced operative time of graft harvest, availability of larger grafts, superior cosmesis, and the possibility for multiple ligament reconstruction [Prodromos 2007]. Drawbacks include delayed graft incorporation, disease transmission, potential immune reactions, altered mechanical properties caused by sterilization, and increased costs of the allograft [Krych 2008].

## c) Double bundle technique

To reproduce the anatomy of the native ACL, some authors have advocated the reconstruction of both bundles. In comparison with the single-bundle technique, double-bundle reconstruction has proven its superiority regarding biomechanical studies and clinical outcomes, in both rotational knee stability and anterior translation function; however functional advantages are still controversial and some complications for this technique such as the risk of breaking the bone septum between bundle tunnels 2 AM and PL at the level of the femoral condyle, have been described [Cong Dung Truong-2021].

## d) Biologically augmented ACL repair

Several options have been investigated to increase ligament integration into the bone tunnels and graft ligamentizations. Platelet-rich-plasma (PRP), which contains several growth factors (including PDGF and TGF- $\beta$ 1 that increase fibroblast proliferation and collagen production) [Eppey 2004] has been proposed with some success [Sanchez 2010, Silva 2008].

soccer injuries account for 25%. Fanelli et al., after arthroscopic evaluation, reported that the incidence of isolated injuries was 7.5%, while in 92.5% of the cases there was a concomitant injury [Fanelli 1993]. Conversely, Schulz et al. reported that isolated injury was present in 47 % of the cases while associated injuries were present in 53 % of cases. Moreover, it was possible to predict the involvement of other anatomic structures, according to the degree of posterior displacement (posterior displacement between 5–12 mm in case of isolated injury) [Schultz 2003]. More recently, Owesen et al. reported that isolated PCL injuries accounted for about one-third of the total number of PCL injuries [Owesen 2015].

## 3.2 Anatomy and function

The PCL is the stronger of the two cruciate ligaments and it is usually considered an extra-articular ligament because it is enclosed within its own synovial sheath [Matava 2009]. The ligament is divided into two bundles [Chwaluk 2008]; a large anterolateral bundle (AL) which tightens in flexion and is lax in extension and a smaller posteromedial bundle (PM) which is conversely tight in extension and lax in flexion [Harner 1995]. The PCL is the major restraint to the posterior displacement of the tibia and accounts for about 95 % of the total restraint [Kannus 1991]. The lateral collateral ligament and the posterolateral corner (PLC), which are the secondary restraints to the posterior translation of the tibia, act in conjunction with the PCL [McAllister 2007]. In addition, the PCL has secondary stabilizing functions, it restrains rotation when the knee is flexed and remains in varus and valgus position when the knee is extended [Malone 2006, Kennedy 2014].

The easiest way to clinically assess a PCL insufficiency is the posterior drawer, which also gives information on the involvement of peripheral structures when it is performed with the foot in internal or external rotation. According to the extent of the posterior drawer it is possible to grade the PCL insufficiency. If the tibia can be displaced posteriorly from zero to 5 mm, it is considered a grade I. In a grade II injury, the tibia is displaced 6 to 10 mm posteriorly, which makes the tibial condyle flush with the femoral condyle. In a grade III injury, the tibia is displaced more than 10 mm posteriorly. This corresponds to a displacement of the tibial condyles posterior to the femoral condyles [Colvin 2009].

## 3.3 Treatment options

The first-line treatment for an isolated grade I or II PCL tear is non surgical management. Patients with concomitant ligamentous injury or those with a chronic PCL tear with residual laxity and recurrent instability should consider surgery. Isolated grade III PCL injuries can be treated non-operatively in patients with mild symptoms or in patients with low activity demands. PCL rehabilitation follows similar principles as ACL rehabilitation with specific differences and it is generally slower. Patients initially work on hamstring and calf stretching and quadriceps strengthening while maintaining range of motion limitations to limit stress on the PCL. In the early stages of rehabilitation, it is also important to avoid active hamstring contraction to limit posteriorly directed forces on the tibia [Michelle E. Kew-2022].

Surgical treatment is recently gaining popularity especially in case of avulsions, grade III injuries and multi-ligament accidents [LaPrade 2015]. Avulsions are usually treated with reinsertion of the bony fragment using a posterior approach, with screws with or without

## 3 Posterior Cruciate Ligament

### 3.1 Introduction

The posterior cruciate ligament (PCL) is the major restraint to tibial posterior translation. The estimated annual incidence of isolated PCL injuries has been reported as 2 per 100,000 persons [Derrick M. Knapik-2022]. It is a thick and strong ligament, therefore its rupture is mainly the consequence of high-energy traumas following motorvehicle accidents (around 45% of cases); sports traumas are less common (around 40% of cases) [Schultz 2003]. More precisely, motorcycle accidents account for 28% of the total PCL injuries and

washer when the fragment is large [Colvin 2009]. When it is smaller or comminuted, suture fixation through small drill holes is preferable. In these cases reinsertion should be protected with extension bracing [Cosgarea 2001]. The reconstruction of the PCL can be performed either with single bundle or double bundle. The single bundle option can be performed with a transtibial tunnel technique, where the graft is passed through the tibial tunnel that exits at the level of the PCL footprint and enters a femoral tunnel placed in the position of the anterolateral bundle of the native PCL on the medial femoral condyle [Allen 2002]. Another option is the tibial inlay technique, which involves the arthroscopic placement of a femoral tunnel and the open creation of a trough at the native footprint of PCL. Double bundle technique has the theoretical advantages of more anatomic reconstruction, with a superior control on posterior drawer [Harner 2000]. This technique requires two femoral tunnels (one bigger for the anterolateral bundle and one smaller for the posteromedial bundle) but just one tibial tunnel is usually needed [Alfonso Vaquero Picado-2017]. A well-designed study has demonstrated slight differences in objectives outcomes (posterior tibial translation, Lysholm score), with double-bundle reconstructions being more accurate than single-bundle reconstructions in restoring the knee to native stability levels [Yoon KH-2011]. Several grafts can be used including patellar tendon autografts. Achilles tendon is the most common used autogenous allograft. In any case, the graft should be longer than 40 mm to ensure adequate length for fixation [Veltri 1993].

## 4 Medial Collateral Ligament

### 4.1 Introduction

Medial collateral ligament (MCL) is the primary static stabilizer of the medial side of the knee, providing resistance to valgus stress as well as internal and external rotation [Marchant 2009].

MCL injury usually follows a pure valgus stress on the knee as a consequence of contact sports injuries. Anatomic damage to the medial side of the knee has been reported to be 0.24 cases per 1000 inhabitants in the USA and is twice as common in males than females [Wijdicks 2010]. Although isolated MCL injury often occurs, the more severe is its anatomic damage, the more likely it is associated with damage of other structures. The risk of having a concomitant ligament injury is 20% with a grade I MCL injury, 53% with a grade II MCL injury, and 78% with a grade III MCL injury [Fetto 1978]. The most common pattern of combined injury involves the MCL and ACL, representing 7-8% of all ligamentous knee injuries [Shelbourne 2003] and 70% of all multiligamentous knee injuries [Kaeding 2005].

### 4.2 Anatomy and function

MCL is divided in two: the superficial and the deep parts. The former contributes to the middle layer (layer 2) of the medial side of the knee while the latter is part of the deep layer (layer 3). The MCL is closely correlated with the posterior oblique ligament (POL), which lies in the layer 2 [Warren 1979]. MCL injuries are usually classified according to medial laxity when a valgus force at 30° degrees of flexion is applied to the knee. Grade I sprain is defined as 0-5mm valgus laxity. Patients have tenderness over the MCL but no instability is present; the MCL is stretched and minor tearing is present. Grade II sprains are defined as 6-10mm valgus laxity. Physical examination reveals increased

valgus laxity with a firm endpoint and significant partial tear of the ligament is observed. Grade III injury is defined a medial laxity greater than 10mm with no appreciable endpoint, which corresponds to a complete rupture of the ligament [Warren 1979].

### 4.3 Treatment options

Isolated acute grade I and II injuries are generally treated conservatively with immobilization and physical therapy with satisfactory results and a quick comeback to sports [Chen 2008, Miyamoto 2009]. More controversies exist on the treatment of acute isolated grade III injuries. When the outcomes of surgery and conservative treatment were compared, some authors showed better results in subjective scores and earlier return to play in conservative treatment [McMahon 2007]. Surgery is indicated in case of intra-articular ligaments entrapment, large bony avulsion, or an acute complete tear of the tibial insertion [Marchant 2009, Laprade 2012]. Ineffective conservative treatment of isolated grade III injuries leads to chronic medial laxity, which is an indication for surgery as well [Lind 2009]. The treatment of MCL grade III injuries in the scenario of multi-ligament injury is complex. Timing, order and which ligament should be repaired/reconstructed is debated. In case of combined ACL/PCL and MCL injuries. The ACL/PCL should be repaired first. MCL can be repaired with sutures, reinserted with anchors (for proximal or distal avulsions) or reconstructed with autografts/allografts. However randomized studies comparing rehabilitation and reconstruction of the MCL in association with ACL reconstruction have reported faster restoration of flexion and quadriceps muscle power in the first cohort [Halinen 2009]. At 52 weeks there was no significant difference in outcomes between the two groups. The reconstructed ACL seems to create a favorable environment to the healing of the MCL. Therefore, in case of multi ligament injury it is reasonable to follow a conservative protocol involving physical therapy for some weeks, in order to let the MCL healing and allow the patient to regain full knee range of motion, and then proceed with ACL reconstruction [Indelicato 1995]

### References:

1. Luvsannyam E, Jain MS, Leitaio AR, Maikawa N, Leitaio AE. *Meniscus Tear: Pathology, Incidence, and Management. Cureus.* 2022 May; 14(5): e25121. Published online 2022 May 18. doi: 10.7759/cureus.25121
2. Cook JL. (2005) *The current status of treatment for large meniscal defects. Clin Orthop Relat Res* 435:88-95.
3. Garrett WE, Jr., Swiontkowski MF, Weinstein JN, Callaghan J, Rosier RN, Berry DJ, Harrast J, Derosa GP. (2006) *American Board of Orthopaedic Surgery Practice of the Orthopaedic Surgeon: Part-II, certification examination case mix. J Bone Joint Surg Am* 88(3):660-7.
4. Mordecai SC, Al N, Ware HE and Gupte CM. *Treatment of meniscal tears: An evidence based approach. World J Orthop.* 2014 Jul 18; 5(3): 233-241. Published online 2014 Jul 18. doi: 10.5312/wjo.v5.i3.233
5. Arnoczky SP, Warren RF. (1982) *Microvasculature of the human meniscus. Am J Sports Med* 10:90-95 DOI: 10.1177/036354658201000205.



6. Assimakopoulos AP, Katonis PG, Agapitos MV, Exarchou EI. (1992). The innervation of the human meniscus. *Clin Orthop Relat Res* 275:232-6.
7. Ahmed AM, Burke DL. (1983) In-vitro measurement of static pressure distribution in synovial joints—Part I: Tibial surface of the knee. *J Biomech Eng* 105(3):216-25.
8. Wesdorp MA, Eijgenraam SM, Meuffels DE, Bierma-Zeinstra SMA, Kleinrensink GJ, Bastiaansen-Jenniskens YM, Reijman M. Traumatic Meniscal Tears Are Associated With Meniscal Degeneration. *Am J Sports Med.* 2020 Aug; 48(10): 2345-2352. Published online 2020 Jul 14. doi: 10.1177/0363546520934766
9. Englund M, Guermazi A, Gale D, Hunter DJ, Aliabadi P, Clancy M, Felson DT. (2008) Incidental meniscal findings on knee MRI in middle-aged and elderly persons. *N Engl J Med* 359:1108-1115.
10. Baratz ME, Fu FH, Mengato R. (1986) Meniscal tears: the effect of meniscectomy and of repair on intraarticular contact areas and stress in the human knee. A preliminary report. *Am J Sports Med* 14:270-275 DOI: 10.1177/036354658601400405
11. Binfield PM, Maffulli N, King JB. (1993) Patterns of meniscal tears associated with anterior cruciate ligament lesions in athletes. *Injury* 24:5 57-561 DOI: 10.1016/0020-1383(93)90038-8.
12. Klimkiewicz JJ, Shaffer B. (2002) Meniscal surgery 2002 update: indications and techniques for resection, repair, regeneration, and replacement. *Arthroscopy* 18:14-25 DOI: 10.1053/jars.2002.36505.
13. Maffulli N, Binfield PM, King JB, Good CJ. (1993) Acute haemarthrosis of the knee in athletes. A prospective study of 106 cases. *J Bone Joint Surg [Br]* 75-B:945-949.
14. Gadeyne S, Besse JL, Galand-Desme S, Lerat JL, Moyen B. (2006) Analysis of meniscal lesions accompanying anterior cruciate ligament tears: A retrospective analysis of 156 patients. *Rev Chir Orthop Repar Appar Mot* 92:448-454.
15. Peltier A, Lording T, Maubisson L, Ballis R, Neyret P, Lustig S (2015) The role of the meniscotibial ligament in posteromedial rotational knee stability. *Knee Surg Sports Traumatol Arthrosc* 23:2967-2973.
16. Chen L, Linde-Rosen M, Hwang SC, Zhou J, Xie Q, Smolinski P, Fu FH (2015) The effect of medial meniscal horn injury on knee stability. *Knee Surg Sports Traumatol Arthrosc* 23(1):126-131.
17. Allaire R, Muriuki M, Gilbertson L, Harner CD (2008) Biomechanical consequences of a tear of the posterior root of the medial meniscus. Similar to total meniscectomy. *J Bone Jt Surg Am* 90(9):1922-1931.
18. Elattrache N, Lattermann C, Hannon M, Cole B. (2014) New England Journal of Medicine article evaluating the usefulness of meniscectomy is flawed. *Arthroscopy* 30:542-543.
19. Thorlund JB, Juhl CB, Roos EM, Lohmander LS. (2015) Arthroscopic surgery for degenerative knee: systematic review and meta-analysis of benefits and harms. *BMJ* 350:h2747.
20. Bollen SR. (2015) Is arthroscopy of the knee completely useless? Meta-analysis a reviewer's nightmare. *Bone Joint J* 97-B:1591-1592.
21. Noorduyn JCA, Glastra van Loon T, van de Graaf VA, Willigenburg NW, Butter IK, Scholten-Peters GGM, Coppeters MW, Poolman RW; Functional Outcomes of Arthroscopic Partial Meniscectomy Versus Physical Therapy for Degenerative Meniscal Tears Using a Patient-Specific Score: A Randomized Controlled Trial. *Orthop J Sports Med.* 2020 Oct 29;8(10):2325967120954392. doi: 10.1177/2325967120954392. eCollection 2020 Oct.
22. Yim JH, Seon JK, Song EK, Choi JI, Kim MC, Lee KB, Seo HY. (2013) A comparative study of meniscectomy and nonoperative treatment for degenerative horizontal tears of the medial meniscus. *Am J Sports Med* 41:1565-1570 DOI: 10.1177/0363546513488518.
23. Katz JN, Brophy RH, Chaisson CE, de Chaves L, Cole BJ, Dahm DL, Donnell-Fink LA, Guermazi A, Haas AK, Jones MH, Levy BA, Mandl LA, Martin SD, Marx RG, Miniaci A, Matava MJ, Palmisano J, Reinke EK, Richardson BE, Rome BN, Safran-Norton CE, Skonecki DJ, Solomon DH, Smith MV, Spindler KP, Stuart MJ, Wright J, Wright RW, Losina E. (2013) Surgery versus physical therapy for a meniscal tear and osteoarthritis. *N Engl J Med* 368: 1675-1684 DOI: 10.1056/NEJMoa1301408.
24. Neyret P, Donell ST, Dejour H. (1993) Results of partial meniscectomy related to the state of the anterior cruciate ligament. Review at 20 to 35 years. *J Bone Joint Surg [Br]* 75-B:36-40.
25. Chatain F, Adeleine P, Chambat P, Neyret P; Société Française d'Arthroscopie. (2003) A comparative study of medial versus lateral arthroscopic partial meniscectomy on stable knees: 10-year minimum follow-up. *Arthroscopy* 19:842-849.
26. Hulet C, Menetrey J, Beauvais P, et al; French Arthroscopic Society (SFA). (2015) Clinical and radiographic results of arthroscopic partial lateral meniscectomies in stable knees with a minimum follow up of 20 years. *Knee Surg Sports Traumatol Arthrosc* 23:225-231.
27. Weiss WM, Johnson D. Update on meniscus debridement and resection. *J Knee Surg.* 2014 Dec;27(6):413-22. doi: 10.1055/s-0034-1388653. Epub 2014 Aug 27. PMID: 25162409
28. Northmore-Ball MD, Dandy DJ, Jackson RW. (1983) Arthroscopic, open partial, and total meniscectomy. A comparative study. *J Bone Joint Surg Br* 65:400-404.
29. Burks RT, Metcalf MH, Metcalf RW. (1997) Fifteen-year follow up of arthroscopic partial meniscectomy. *Arthroscopy* 13:673-679 DOI: 10.1016/S0749-8063(97)90000-1.
30. Jaureguito JW, Elliot JS, Lietner T, Dixon LB, Reider B. (1995) The effects of arthroscopic partial lateral meniscectomy in an otherwise normal knee: a retrospective review of functional, clinical, and radiographic results. *Arthroscopy* 11:29-36 DOI: 10.1016/0749-8063(95)90085-3.
31. Faunø P, Nielsen AB. (1992) Arthroscopic partial meniscectomy: a long-term follow-up. *Arthroscopy* 8:345-349 DOI: 10.1016/0749-8063(92)90066-K.
32. Jørgensen U, Sonne-Holm S, Lauridsen F, Rosenklint A. (1987) Long-term follow-up of meniscectomy in athletes. A prospective longitudinal study. *J Bone Joint Surg Br* 69 80-83.
33. vanTrommel MF, Simonian PT, Potter HG, Wickiewicz TL. (1998) Arthroscopic meniscal repair with fibrin clot of complete radial tears of the lateral meniscus in the avascular zone. *Arthroscopy* 14:360-365 DOI: 10.1016/S0749-8063(98)70002-7.
34. Boyd KT, Myers PT. (2003) Meniscus preservation; rationale, repair techniques and results. *Knee* 10(1):1-11.
35. Ra HJ, Ha JK, Jang SH, Lee DW, Kim JG. (2013) Arthroscopic inside-out repair of complete radial tears of the meniscus with a fibrin clot. *Knee Surg Sports Traumatol Arthrosc* 21:2126-2130.

36. Nepple JJ, Block AM, Eisenberg MT, Palumbo NE, Wright RW. Meniscal Repair Outcomes at Greater Than 5 Years: A Systematic Review and Meta-Analysis. *J Bone Joint Surg Am* 2022 Jul 20;104(14):1311–1320. doi: 10.2106/JBJS.21.01303. Epub 2022 Apr 19.
37. Sanders TL, Maradit Kremers H, Bryan AJ, Larson DR, Dahm DL, Levy BA, Stuart MJ, Krych AJ. Incidence of Anterior Cruciate Ligament Tears and Reconstruction. A 21-Year Population-Based Study. *Am J Sports Med*. 2016 Jun;44(6):1502–7. doi: 10.1177/0363546516629944. Epub 2016 Feb 26. PMID: 26920430
38. Levine JW, Kiapour AM, Quatman CE, Wordeman SC, Goel VK, Hewett TE, Demetropoulos CK. (2013) Clinically relevant injury patterns after an anterior cruciate ligament injury provide insight into injury mechanisms. *Am J Sports Med* 41:385–395 doi: 10.1177/0363546512465167.
39. Butler DL, Noyes FR, Grood ES. (1980) Ligamentous restraints to anterior-posterior drawer in the human knee. A biomechanical study. *J Bone Joint Surg Am* 62:259–270.
40. Quatman CE, Kiapour AM, Demetropoulos CK, Kiapour A, Wordeman SC, Levine JW, Goel VK, Hewett TE. (2014) Preferential loading of the ACL compared with the MCL during landing: a novel in sim approach yields the multiplanar mechanism of dynamic valgus during ACL injuries. *Am J Sports Med* 42:177–186.
41. Hewett TE, Di Stasi SL, Myer GD. (2013) Current concepts for injury prevention in athletes after anterior cruciate ligament reconstruction. *Am J Sports Med* 41:216–224.
42. Feagin JA Jr, Curl WW. (1976) Isolated tear of the anterior cruciate ligament: 5-year follow-up study. *Am J Sports Med* 4:95–100.
43. Sandberg R, Balkfors B, Nilsson B, Westlin N. (1987) Operative versus non-operative treatment of recent injuries to the ligaments of the knee: a prospective randomized study. *J Bone Joint Surg [Am]* 69-A:1120–1126.
44. Prodromos CC, Fu FH, Howell SM, Johnson DH, Lawhorn K. (2008) Controversies in soft-tissue anterior cruciate ligament reconstruction: grafts, bundles, tunnels, fixation, and harvest. *J Am Acad Orthop Surg*. 16:376–384.
45. Barber-Westin S, Noyes FR. One in 5 Athletes Sustain Reinjury Upon Return to High-Risk Sports After ACL Reconstruction: A Systematic Review in 1239 Athletes Younger Than 20 Years. *Sports Health*. 2020 Nov/Dec;12(6):587–597. doi: 10.1177/1941738120912846. Epub 2020 May 6. PMID: 32374646
46. Abebe ES, Kim JP, Utturkar GM, Taylor DC, Spritzer CE, Moorman CT 3rd, Garrett WE, DeFrate LE. (2011) The effect of femoral tunnel placement on ACL graft orientation and length during in vivo knee flexion. *J Biomechanics*. 44:1914–1920 doi: 10.1016/j.jbiomech.2011.04.030. Epub 2011 May 13.
47. Adachi N, Ochi M, Uchio Y, Yasa J, Kuriwaka M, Ito Y. (2004) Reconstruction of the anterior cruciate ligament: single- versus double-bundle multistranded hamstring tendons. *J Bone Joint Surg Br*. 86:515–520.
48. Aune AK, Holm I, Risberg MA, Jensen HK, Steen H. (2001) Four-strand hamstring tendon autograft compared with patellar tendon-bone autograft for anterior cruciate ligament reconstruction: a randomized study with two-year followup. *Am J Sports Med*. 29:722–728.
49. Hurley ET, Calvo-Gurry M, Withers D, Farrington SK, Moran R, Moran CJ. Quadriceps Tendon Autograft in Anterior Cruciate Ligament Reconstruction: A Systematic Review. *Arthroscopy*. 2018 May;34(5):1690–1698. doi: 10.1016/j.arthro.2018.01.046. Epub 2018 Apr 5. PMID: 29628380
50. Prodromos C, Joyce B, Shi K. (2007) A meta-analysis of stability of autografts compared to allografts after anterior cruciate ligament reconstruction. *Knee Surg Sports Traumatol Arthrosc*. 15:851–856.
51. Krych AJ, Jackson JD, Hoskin TL, Dahm DL. (2008) A meta-analysis of patellar tendon autograft versus patellar tendon allograft in anterior cruciate ligament reconstruction. *Arthroscopy*. 24:292–298.
52. A Simplified Double-Bundle Anterior Cruciate Ligament Reconstruction by the Three-Inside Technique With Two Suspension Buttons and One Interference Screw. *Cong Dung Truong, To Dong Kha Thanh Huan Vuong Abdelrahman Zakzouk Nguyen Minh Dung Tung Dang Xuan Tran Abdelrahman M Makram Nguyen Tien Huy*
53. Sanchez M, Anitua E, Azofra J, Prado R, Muruzabal F, Andia I. (2010) Ligamentization of tendon grafts treated with an endogenous preparation rich in growth factors: gross morphology and histology. *Arthroscopy* 26:470–480.
54. Silva A, Sampaio R. (2009) Anatomic ACL reconstruction: does the platelet-rich plasma accelerate tendon healing? *Knee Surg Sports Traumatol Arthrosc* 17:676–682.
55. Knapik DM, Gopinath V, Jackson GR, Chahla J, Smith MV, Matava MJ, Brophy RH. Global variation in isolated posterior cruciate ligament reconstruction *J Exp Orthop*. 2022 Dec;9: 104. Published online 2022 Oct 9. doi:10.1186/s40634-022-00541-4
56. Schulz MS, Russe K, Weiler A, Eichhorn HJ, Strobel MJ. (2003) Epidemiology of posterior cruciate ligament injuries. *Arch Orthop Trauma Surg*. 123(4):186–191.
57. Fanelli GC. (1993) Posterior cruciate ligament injuries in trauma patients. *Arthroscopy*. 9(3):291–294
58. Owesen C, Sivertsen EA, Engebretsen L, Granan LP, Årøen A. (2015) Patients With Isolated PCL Injuries Improve From Surgery as Much as Patients With ACL Injuries After 2 Years. *Orthop J Sports Med*. 19;3(8):2325967115599539. doi: 10.1177/2325967115599539.
59. Matava MJ, Ellis E, Gruber B. (2009) Surgical treatment of posterior cruciate ligament tears: An evolving technique. *J Am Acad Orthop Surg*. 17(7):435–46.
60. Chwaluk A, Cizek B. (2008) Anatomy of the posterior cruciate ligament. *Ortop Traumatol Rehabil*. 10(1):1–11.
61. Harner CD, Xerogeanes JW, Livesay GA, Carlin GJ, Smith BA, Kusayama T, Kashiwaguchi S, Woo SL. (1995) The human posterior cruciate ligament complex: an interdisciplinary study. Ligament morphology and biomechanical evaluation. *Am J Sports Med*. 23(6):736–45.
62. McAllister DR, Petrigliano FA. (2007) Diagnosis and treatment of posterior cruciate ligament injuries. *Current Sports Medicine Reports*. 6(5):293–9
63. Kannus P, Bergfeld J, Jarvinen M, Johnson RJ, Pope M, Renstrom P, Yasuda K. (1991) Injuries to the posterior cruciate ligament of the knee. *Sports Med*. 12(2):110–131

64. Kennedy NI, LaPrade RF, Goldsmith MT, Faucett SC, Rasmussen MT, Coatney GA, Engebretsen L, Wijdicks CA. (2014) Posterior cruciate ligament graft fixation angles, part 1: biomechanical evaluation for anatomic single-bundle reconstruction. *Am J Sports Med.* 42(10):2338–2345
65. Malone AA, Dowd GS, Saifuddin A. (2006) Injuries of the posterior cruciate ligament and posterolateral corner of the knee. *Injury.* 37(6):485–501
66. Colvin AC, Meislin RJ. (2009) Posterior cruciate ligament injuries in the athlete: diagnosis and treatment. *Bull NYU Hosp Jt Dis.* 67(1):45–51
67. Kew ME, Cavanaugh JT, Elnemer WG, Marx RG. Return to Play after Posterior Cruciate Ligament Injuries. *Curr Rev Musculoskelet Med.* 2022 Dec;15(6):606–615. doi: 10.1007/s12178-022-09794-z. Epub 2022 Nov 30.
68. LaPrade CM, Civitarese DM, Rasmussen MT, LaPrade RF. (2015) Emerging updates on the posterior cruciate ligament: a review of the current literature. *Am J Sports Med.* 43(12):3077–92. doi: 10.1177/0363546515572770.
69. Cosgarea AJ, Jay PR. (2001) Posterior cruciate ligament injuries: evaluation and management. *J Am Acad Orthop Surg.* 9(5):297–307.
70. Veltri DM, Warren RF. (1993) Isolated and Combined Posterior Cruciate Ligament Injuries. *J Am Acad Orthop Surg.* 1(2):67–75.
67. Allen CR, Kaplan LD, Fluhme DJ, Harner CD. (2002) Posterior cruciate ligament injuries. *Curr Opin Rheumatol.* 14(2):142–9.
68. Harner CD, Jansushak MA, Kanamori A, Yagi M, Vogrin TM, Woo SL. (2000) Biomechanical analysis of a double-bundle posterior cruciate ligament reconstruction. *Am J Sports Med.* 28(2):144–51.
71. Vaquero-Picado A, Rodríguez-Merchán EC. Isolated posterior cruciate ligament tears: an update of management. *EFORT Open Rev.* 2017 Apr 27;2(4):89–96. doi: 10.1302/2058-5241.2.160009. eCollection 2017 Apr.
72. Yoon KH, Bae DK, Song SJ, Cho HJ, Lee JH. A prospective randomized study comparing arthroscopic single-bundle and double-bundle posterior cruciate ligament reconstructions preserving remnant fibers. *Am J Sports Med.* 2011 Mar;39(3):474–80. doi: 10.1177/0363546510382206. Epub 2010 Nov 23
73. Marchant MH Jr, Tibor LM, Sekiya JK, Hardaker WT Jr, Garrett WE Jr, Taylor DC. (2009) Management of medial sided knee injuries, part 1: medial collateral ligament. *Am J Sports Med.* 39(5):1102–1113. doi: 10.1177/0363546510385999
74. Fetto JF, Marshall JL. (1978) Medial collateral ligament injuries of the knee: a rationale for treatment. *Clin Orthop Relat Res.* May 132:206–218.
75. Shelbourne KD, Carr DR. (2003) Combined anterior and posterior cruciate and medial collateral ligament injury: nonsurgical and delayed surgical treatment. *Instr Course Lect.* 52:413–418.
76. Kaeding CC, Pedroza AD, Parker RD, Spindler KP, McCarty EC, Andrich JT. (2005) Intra-articular findings in the reconstructed multiligament-injured knee. *Arthroscopy.* Apr 2005;21(4):424–430.
77. Warren LF, Marshall JL. (1976) The supporting structures and layers on the medial side of the knee: an anatomical analysis. *J Bone Joint Surg Am.* 61(1):56–62
78. Clancy W, Bergfeld J, O'Connor GA, Cox JS. (1979) Symposium: functional rehabilitation of isolated medial collateral ligament sprains. First, second, and third-degree sprains. *Am J Sports Med.* 7(3):206–213.
79. Chen L, Kim PD, Ahmad CS, Levine WN. (2008) Medial collateral ligament injuries of the knee: current treatment concepts. *Curr Rev Musculoskelet Med.* 1(2):108–13. doi: 10.1007/s12178-007-9016-x.
80. Miyamoto RG, Bosco JA, Sherman OH. (2009) Treatment of medial collateral ligament injuries. *J Am Acad Orthop Surg.* 17(3):152–61.
81. Macmahon P. (2007) Current diagnosis & treatment in sports medicine, in Lange medical book. Lange Medical Books/McGraw Hill Medical Pub, New York, 73–77
82. LaPrade RF, Wijdicks CA. (2012) The management of injuries to the medial side of the knee. *J Orthop Sports Phys Ther.* 42(3):221–233
83. Lind M, Jakobsen BW, Lund B, Hansen MS, Abdallah O, Christiansen SE. (2009) Anatomical reconstruction of the medial collateral ligament and posteromedial corner of the knee in patients with chronic medial collateral ligament instability. *Am J Sports Med.* 37(6):1116–1122. doi: 10.1177/0363546509332498.
84. Halinen J, Lindahl J, Hirvensalo E. (2009) Range of motion and quadriceps muscle power after early surgical treatment of acute combined anterior cruciate and grade-III medial collateral ligament injuries. A prospective randomized study. *J Bone Joint Surg Am.* 91(6):1305–1312.
85. Indelicato PA. (1995) Isolated Medial Collateral Ligament Injuries in the Knee. *J Am Acad Orthop Surg.* 3(1):9–14.



#EFORT2025

**EFORT Head Office**  
ZA La Pièce 1-A5  
1180 Rolle, Switzerland  
Phone: +41 (0)21 343 4400  
office@efort.org  
**www.efort.org**